

ORIGINAL PAPERS

Dent. Med. Probl. 2011, 48, 3, 311–318
ISSN 1644-387X

© Copyright by Wrocław Medical University
and Polish Dental Society

CHRISTINE TESSEROMATIS¹, ANTONIA KOTSIU², ELENI PARARA¹, NICOLAOS SEFEROS¹,
CONSTANTIN MOUROUZIS³, JANE MESSARI¹, GEORGE RALLIS⁴, MAGDALENE TSAMOURI⁵

A Clinical and Histological Study on the Micro-Vascular Diseased Gingiva of Diabetic Patients

Badanie kliniczne i histologiczne zmian mikronaczyniowych w zmienionym zapalnie dziąśle u pacjentów chorych na cukrzycę

¹ Department of Pharmacology Medical School, University of Athens, Greece

² Aretaieion University Hospital Athens, Greece

³ Oral and Maxillofacial Surgery, Queen Alexandra Hospital, University of Portsmouth, United Kingdom

⁴ Department of Oral and Maxillofacial Surgery General Hospital of Athens «KAT», Greece

⁵ Department of Pathology Red Cross Hospital of Athens, Greece

Abstract

Background. Diabetes mellitus is involved in many degenerative processes leading to the manifestation of great morbidity. Furthermore, diabetes mellitus is strongly associated with periodontal disease. The severity of the defects due to diabetes depends on the blood glucose level. Similarly, the progression and the extent of tissues changes are influenced by the control of glucose levels.

Objectives. The aim of the study was to investigate the periodontal status in patients suffering from diabetes and to estimate the severity of the morphological changes of blood bed vessels or to assess the degree of diabetes morbidity from the histological findings of gingival biopsy specimen.

Material and Methods. Thirty patients with mean age 58 years ($\pm 12,11$), 18 men and 12 women with mean blood glucose of 250 mg/dl and 10 healthy subjects were included in the study. All of them underwent periodontal examination using the Ramfjord index (dental plaque, gingival inflammation degree and periodontal pocket depth) in order to obtain the most constant criterion possible of the clinical features of diabetes in the oral cavity. In parallel, biopsies from buccal gingivae were obtained, so as to investigate possible changes attributed to diabetes mellitus.

Results and Conclusions. The histological findings from the buccal gingival papilla demonstrated hyperplasia of the multilayer squamous epithelium and intense chronic inflammation with fibrosis of the lamina propria. In addition microangiopathy was detected from the PAS positive material on the vessel wall. Perivascular inflammation with intense thickness and narrowing of the arteriole lumen was also observed (*Dent. Med. Probl.* 2011, 48, 3, 311–318).

Key words: diabetes mellitus, periodontal status, gingival microangiopathy.

Streszczenie

Wprowadzenie. U osób chorych na cukrzycę dochodzi do wielu procesów degeneracyjnych prowadzących do złożonej symptomatologii klinicznej. Cukrzyca pozostaje także w ścisłym związku z chorobami przyzębia. Ciężkość zmian zależy od stężenia glukozy w surowicy krwi. Podobnie zaawansowanie i rozległość zmian tkankowych są modulowane za pomocą kontroli stężenia glukozy.

Cel pracy. Ocena stanu klinicznego przyzębia pacjentów chorych na cukrzycę, ocena zaawansowania zmian morfologicznych naczyń w dziąśle tych osób oraz próba określenia zaawansowania cukrzycy na podstawie badania histopatologicznego dziąsła.

Materiał i metody. Do badania zakwalifikowano 30 osób (18 mężczyzn i 12 kobiet) o średniej wieku 58 lat ($\pm 12,11$) ze średnim stężeniem glukozy w surowicy krwi 250 mg/dl. Grupę kontrolną stanowiło 10 ogólnie zdrowych osób. W ocenie stanu klinicznego przyzębia zastosowano wskaźnik Ramfjorda (płytką nazębną, stan zapalny dziąsła i głębokość kieszonek przyzębnych) w celu wykazania najbardziej stałych zmian w jamie ustnej w przebiegu cukrzycy. Aby ocenić zmiany histopatologiczne zależne od cukrzycy, równolegle pobierano wycinki dziąsłowe.

Wyniki i wnioski. W badaniu histopatologicznym językowych brodawek dziąsłowych wykazano rozrost wielowarstwowego nabłonka rogowaciejącego oraz rozległy stan zapalny z włóknieniem w blaszce właściwej. Dodatkowo stwierdzano mikroangiopatie w PAS pozytywnym materiale ściany naczyń. Obserwowano również rozległy proces zapalny w obszarze okołonaczyniowym oraz zwężenia światła naczyń (**Dent. Med. Probl.** 2011, 48, 3, 311–318).

Słowa kluczowe: cukrzyca, stan kliniczny przyzębia, mikroangiopatie dziąsłowe.

Diabetes mellitus (DM) is a crucial metabolic status, characteristic for relative or absolute insulin deficiency. The diminished insulin capacity to involve in glucose and lipid metabolism results in a wide number of degeneration processes affecting retina, kidneys, vasculature, nervous system and the periodontium. Periodontal disease is so firmly bound to diabetes that it is referred to as its sixth complication – retinopathy, nephropathy, neuropathy, intermittent claudication, erectile disorders [1, 2]. Periodontal disease is attributed mainly to dental plaque biofilm due to dental plaque accumulation and diabetes mellitus or other systemic diseases can modify the host response to the bacteria and they can be considered as risk factors for periodontitis [3, 4]. The principal problem of hyperglycaemia by DM is the microvascular complications. Furthermore, the accumulation of advanced glycation end products (AGE) in diabetes mellitus is responsible for impaired wound healing and endothelial dysfunction [5–7]. A continual non-enzymatic cross-linking of structural proteins as collagen and elastin is the cause of several complications [8]. The vascular complications (increased permeability of small vessels) observed in DM may be caused by the interaction of AGE's and the endothelial cells that exert noxious effects on gingival tissues through its receptors (RAGE) contributing to basement membrane thickening via cross-linking of the structural proteins collagen and elastin [9, 10]. Probably the accumulation of mononuclear phagocytes, smooth muscle cells, or other vessel wall components through the increase of the vascular permeability may be involved in the inflammation tendency of the diabetic population [11].

On the other hand, the notion, that the gravity of the periodontal disease predisposes either the abnormal insulin secretion or the tissues' insulin resistance, has been a matter of great interest during the past years. Periodontal disease aggression may also upregulate the already disturbed diabetic metabolic control. The products of perio-pathogenic bacteria (*Porphyromonas gingivalis*, *Tannerella forsythensis*, *Aggregatibacter actinomycetemcomitans*) inducing the production and secretion of cytokines aggravate the periodontal status [12].

The aim of this study was to record the condition of the periodontal status and to estimate the severity of the morphological changes of blood

bed vessels in DM. In this procedure, it is attempted to apply an easily performed method by collecting gingival specimens and searching for PAS+ material, in order to detect diabetic morbidity.

Material and Methods

The study was conducted as case-control, comparing two parallel groups. Group A was the control, with 30 healthy individuals, 12 males and 18 females. The mean age was 52 ± 7.5 years, ranging from 27 to 60 years. Group B included 80 known diabetic patients, 48 males and 32 females. Mean age for the second group was 58 ± 12 years, ranging between 28 and 75 years. Fifty one (51) patients of the second group were on insulin therapy (type-1) and twenty nine (29) were non-insulin dependent (type-2). The diabetic participants presented a wide range of disease duration, as defined by the time of diagnosis, extending over 15 years. Moreover, the study group consisted of poorly controlled diabetics diagnosed as such, by their elevated blood glucose and glycated haemoglobin levels. Majority of the patients suffered from the micro- and macrovascular complications of diabetes related retinopathy, neuropathy, nephropathy and coronary heart disease. The participants underwent a full oral clinical and radiographic examination. The exclusion criteria involved puberty, smoking habits, hypertension or other vascular diseases, other endocrine disorders, immune deficiencies, haematological abnormalities especially bleeding tendency, pregnancy for females, use of antibiotics, chemotherapeutics, immunosuppressives up to 6 months prior to the study, corticosteroids, intake of drugs associated with gingival hyperplasia as phenytoin, nifedipine and cyclosporine. All the ethical rules for research determined by the declaration of Helsinki 1975 have been applied to the study [13].

The alveolar bone level and the periodontium were examined with panoramic and periapical radiographs. The impact of several local factors on the periodontal tissues was evaluated by Ramfjord Index, which is more reliable for people with severe illness, in spite of the fact that its application sometimes can underestimate the severity of the periodontal disease but may be useful for assessing periodontal disease progression in longitu-

dinal population studies of human periodontitis [14, 15].

The use of selected teeth represents the entire dentition in many epidemiological and clinical investigations. The patients were examined for assessment of their Plaque Index, Gingival Index, Calculus Index and Loss of Attachment for the Ramfjord teeth 16, 21, 24, 36, 41, 44 [16]. If a Ramfjord tooth was missing, a substitute tooth was selected as suggested by Fleiss et al. [17] (teeth numbers 17, 11, 25, 37, 31, 45). The Ramfjord (PDI) was applied on the 4 sides of each tooth in the oral cavity.

The presence of dental plaque became clearly visible by the application of erythrocin – disclosing solution and the red pigmentation of plaque in each dental site. The grading was performed by the following criteria: score 0 (total absence of dental plaque), score 1 (plaque extends up to 1/3 of the dental surface), score 2 (plaque extends up to 2/3 of the dental surface), score 3 (plaque extends on the whole dental surface).

The presence of dental calculus, was detected by a dental explorer, measured by a calibrated dental probe, and registered under the grades of the Ramfjord index: Grade 0 (absence of calculus), Grade 1 (supragingival calculus < 1 mm), Grade 2 (1mm < supragingival calculus < 2 mm). We defined as Grade 3 the abundant calculus, which was practically covering the tooth surface.

The Ramfjord index determined the periodontal tissues' inflammatory reaction, which was mainly demonstrated as gingival redness and oedema. In order to detect bleeding, a periodontal probe was inserted and run along the gingival sulcus and periodontal pocket. The gingival inflammation was evaluated with a scale of 0–3 grades. Grade 0: healthy gingiva, no inflammation, normal gingiva in texture and colour, Grade 1: mild inflammation, slight change in colour and swelling, no bleeding in inserting the probe, Grade 2: moderate inflammation extending to marginal and papillary gingiva, redness, swelling, bleeding in inserting the probe, Grade 3: severe gingivitis, inflammation extending to attached gingiva, redness, swelling, spontaneous bleeding.

The probing depth was measured from the gingival margin to the base of the crevice by inserting a calibrated probe to the periodontal tissues. The mean percentage of the 4 dental sites was estimated.

Gingival biopsies were obtained as a diagnostic procedure for histological lesions attributed to diabetic microangiopathy. The incision for the specimen (biopsy) included interdental papilla, attached and free gingival from the mandibular premolar area. The samples of gingival tissues were

placed in Bouin's solution as a fixative medium, for histopathological investigation. Mandibular block nerve anesthesia *via* injection of 1ml lidocaine hydrochloride (2%) without vasoconstrictors was performed while for the buccal nerve area 0,5 ml was injected, in order to avoid local vascular constriction.

Statistical analysis was performed by Spearman's non-parametric correlation and Mann-Whitney test. It determines the statistically significant differences between the two groups as $p < 0.05$.

Results

Group Comparison

The study group comprised of 80 known diabetic patients, 35 (43.75%) of who were male. The control group on the other hand, had 12 (40%) males, which is not a significant difference. The mean age for the study group and the controls was 57 ± 12 years and 54 ± 10 years respectively.

Oral Hygiene

Regarding the oral hygiene status, diabetic patients were more likely to present oral plaque, as 61 (76%) were positive for plaque existence. This finding was not statistically significant (Table 1). Plaque existence (Spearman's $p > 0.10$), Plaque extend (Spearman's $p > 0.10$).

Incidence of calculus was also found higher in the study group than controls. The amount of calculus was higher in diabetic patients as well (Table 1). This result was statistically significant (Spearman's $p < 0.05$).

Periodontal Examination

a) The Ramfjord index for inflammatory reaction of periodontal tissues (gingival redness and oedema) was significantly higher for the group of diabetic patients (Spearman's $p < 0.05$). This result was significant both for inflammatory reaction existence and for inflammatory reaction grade (Table 1).

b) Periodontal pocket existence was estimated and found statistically significantly higher for the diabetic group than controls (Spearman's $p < 0.001$).

The index for probing depth, as measured for each patient, was also higher for the study group, as can be seen in Table 1. One patient of the study group presented gingival regression instead of pockets, so the index was documented for 24 patients.

Table 1. Clinical indices of periodontitis: plaque existence (Spearman's $p > 0.10$), plaque extend (Spearman's $p > 0.10$), calculus existence (Spearman's $p < 0.05$), Calculus extent (Spearman's $p < 0.05$), inflammatory reaction existence – control/ /diabetics (Spearman's $p < 0.05$), inflammatory reaction extent (Spearman's $p < 0.05$)

Tabela 1. Wskaźniki kliniczne choroby przyzębia: obecność płytki (Spearman $p > 0,10$), rozległość płytki (Spearman $p > 0,10$), obecność kamienia nazębnego (Spearman $p < 0,05$), rozległość kamienia $p < 0,05$, obecność zapalenia – kontrola/cukrzyca (Spearman $p < 0,05$), rozległość stanu zapalnego (Spearman $p < 0,05$)

Groups of patients (healthy, diabetic)		Diabetes		Total
		no	yes	no
Plaque	no	12	18	30
	one third of tooth	6	9	15
	two thirds of tooth	12	31	43
	more than two thirds	0	22	22
Calculus	no	12	12	24
	supragingival ≤ 1 mm	6	7	13
	supragingival $> 1, < 2$ mm	9	32	41
	abundant	3	29	32
Inflammation	no	12	13	25
	mild, not surrounding tooth	9	9	18
	moderate, surrounding tooth	6	39	45
	severe gingivitis	3	19	22
Total		30	80	110
Pocket depth (mm)	0,00	21	3	24
	0,50	0	6	6
	1,00	9	6	15
	1,50	0	7	7
	2,00	0	29	29
	2,50	0	4	4
	3,00	0	19	19
	3,50	0	3	3
	4,00	0	3	3
Total		30	80	110

Radiographic Examination

The teeth examined on orthopantomographic and periapical radiographs demonstrated subgingival calculus, traumatic prostheses or teeth restorations in 19 of the 30 diabetic patients (61%) while only 3 (30%) of the healthy subjects had subgingival calculus.

Evaluation within the Diabetic Group

Fifty one (51) patients of the second group were on insulin therapy (type-1) and twenty nine (29) were non-insulin dependent (type-2). The group of 80 diabetic patients comprised of 29 type-2 and 51 type-1. Among those categories, the oral hygiene, periodontal disease indexes, duration of DM disease and systematic complications of the DM disease were different. However, the only statistically significant difference between type-1 patients

and type-2 patients was observed for comparison of periodontal pocket existence (Table 2).

General Status

As mentioned in Table 2, 58 of the diabetic patients also suffered accompanying diseases arising from the microangiopathy of DM. Furthermore, serum glucose levels were more marked in the type 1 group (mean: 268 mg/dl) than the type-2 group (mean: 145 mg/dl) with a statistical significance of $p < 0.01$ (Mann-Whitney U test). The same difference was apparent for the glycosylated haemoglobin (HbA1C) levels. For the type 1 group HbA1C was 7.66 ± 0.88 mg/dl whereas for the type-2 group it was 6.67 ± 1.014 mg/dl. This was a statistically significant result.

Histopathological Results

Histopathological examination of tissue specimens revealed the existence of chronic inflam-

Table 2. Clinical findings of periodontium and systematic manifestation in diabetes mellitus (type-1 and type-2)**Tabela 2.** Zmiany kliniczne przyzębia i objawy ogólne w cukrzycy typu 1 i 2

Diabetic patients	Dental plaque	Dental calculus	Gingival inflammation	Periodontal pocket *	Systematic complications	Mean disease duration (yrs)
Type -2	11	18	21	13	18	9,8
Type -1	32	37	35	38	40	11,4
Total	43	55	56	51	58	

Table 3. Histological findings in diabetic and healthy subjects (*Spearman's $p < 0.001$ differences of each histopathological parameter between groups)**Tabela 3.** Zmiany histopatologiczne dziąseł u osób chorych na cukrzycę i osób zdrowych (*różnica wsp. Spearmana za każdym razem $p < 0,01$ w każdym parametrze histopatologicznym między grupami)

		Inflammation*	Vasculitis*	Fibrosis*	Lumen obstruction*	Positive PAS stain	
Diabetes	no	15	12	3	0	0	
	yes	74	80	72	53	19	
Histologically found inflammation (zapalenia w obrazie hist.-pat.)							Total
		no	mild	medium	grave	excessive	
Diabetes	no	15	9	0	6	0	30
	yes	5	0	8	40	27	80
Total		20	9	8	46	27	110
Vasculitis							Total
		no	mild	medium	grave	excessive	
Diabetes	no	18	12	0	0	0	30
	yes	0	18	24	34	4	80
Total		18	30	24	34	4	110
Fibrosis (zwłóknienie)							Total
		no	mild	medium	grave	excessive	
Diabetes	no	27	3	0	0	0	30
	yes	8	17	29	21	5	80
Total		35	20	29	21	5	110
Lumen obstruction (zmniejszenie światła naczynia)							Total
		no	mild	medium	grave		
Diabetes	no	30	0	0	0	30	
	yes	26	32	19	3	80	
Total	56	32	19	3	110		

mation, which was markedly elevated in the study group (Table 3). This result was statistically significant (Spearman's $p < 0.001$). The same statistically significant difference was noted for other histopathological observations, i.e. vasculitis, fi-

brosis and vascular wall thickness, which caused lumen obstruction (Table 3).

The difference of PAS deposition was not found statistically significant between diabetics and controls (Table 3).

Histological Findings

Histological gingival lesions were more often in the diabetic patients. The gingival squamous epithelium showed intense hyperplasia and the lamina propria focal grave chronic inflammation and fibrosis. Perivascular chronic inflammation was focally observed with narrowing of the lumens and thickening of the small artery walls due to PAS positive deposits. PAS material deposition in the vessel wall indicative of microangiopathy was also observed in 19 diabetic patients, while none of the healthy had the above finding. Furthermore, perivascular inflammation with intense thickening and narrowing of the arteriole lumen was present in 53 patients (Fig. 1–3).

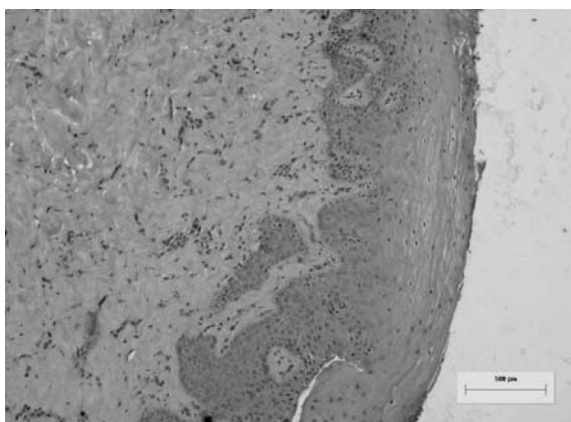


Fig. 1. Gingival epithelium of normal thickness, absence of inflammation and undetectable vessels. H + E, $\times 25$

Ryc. 1. Nabłonek dziąsła normalnej grubości, brak zapalenia i niewidoczne naczynia. Barwienie H + E, $25\times$

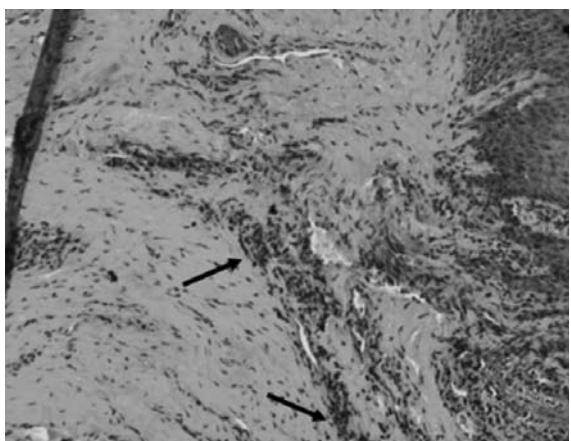


Fig. 2. Severe hyperplasia (\blacktriangleright) of the squamous epithelium, chronic perivascular and diffuse inflammation (\rightarrow) and neoangiogenesis of gingival mucosa. In diabetic patient. H + E, $\times 25$

Ryc. 2. Znaczący rozrost (\blacktriangleright) zrogowaciałego nabłonka, przewlekłe i rozległe zapalenie w tkance okołonaczyniowej (\rightarrow) oraz neoangiogeneza w tkance dziąsła u pacjenta chorego na cukrzycę. Barwienie H + E, $25\times$

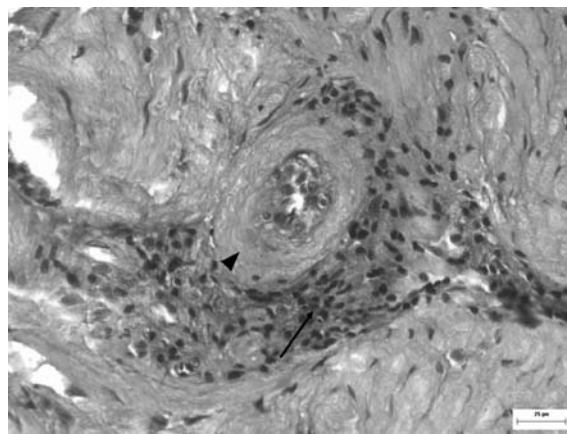


Fig. 3. Chronic perivascular inflammation (\rightarrow) with thickening (\blacktriangleright) of the vessel wall in the gingiva of a diabetic patient. H + E, $\times 200$

Ryc. 3. Przewlekłe zapalenie okołonaczyniowe (\rightarrow) ze zgrubieniem (\blacktriangleright) ścian naczynia dziąsła u pacjenta chorego na cukrzycę. Barwienie H + E, $200\times$

Discussion

Diabetes is considered to be responsible for the impairment of wound healing process [18, 19]. Moreover, it is referred that diabetic patients are more susceptible to periodontal disease compared to non-diabetic population. The observed higher incidence of calculus in diabetic patients (Table 1) aggravates the local conditions in the periodontal bed, which is subject to traumatic injuries and is in agreement with relative findings of other investigators [20]. Furthermore, the presence of calculus may be attributed to the greater content of proteins in the meals of diabetic patients, that predisposes to the conservation of constant pH values, a fact associated with abundant amount of calculus [21, 22].

As it is mentioned above, the AGE accumulation may promote an increased vascular permeability, which in relation to a long term injury via local factors, leads to excessive micro non-healing wounds [10, 23]. In the present study the assessment of the relationship between the six selected teeth described by Ramfjord concerning the Plaque Index, Gingival Index, Calculus Index and Loss of Attachment as well as the histological findings of the patients in a diabetic status demonstrate an aggravation of the disease manifestations in diabetic group and more in the type-1 patients [24, 25]. It is obvious that in type-1 patients, the severity of diabetes mellitus is greater since a variety of organs are affected. On the other hand, the type-2 showed no diabetic complications in other organs and their periodontal status was not negatively influenced [26]. The results of the present study suggest that calculus incidence is greater

in the type-1 ($p < 0.05$), as well as pocket depth ($p < 0.001$). However, the increase of inflammation when the disease is more pronounced [27] (type-1) was not depicted by our results. The increased incidence of gingival inflammation, apart from the diabetic condition may be explained by negligence for dental and general oral cavity health care because of the systemic disease status [28, 29].

As it is deduced by the histological findings, the typical changes through the PAS deposition on the gingival vessel wall are limited only in 19 patients (24%). However, this finding was not seen in the control group. A strong incidence of the inflammation frequency and severity in the gingival tissue of diabetic patients versus the control group was shown, followed by the excessive presence of vasculitis in patients versus control $p < 0.001$. Although our results suggest an important incidence of diabetic injuries in gingival bed vessels, specific PAS-positive lesions were not observed as a rule. Therefore, this finding cannot be used to alert the patient and their current team physicians

to urgently control the blood glucose. Thus, once established in the diabetic host, chronic infections complicate diabetes control and increase the occurrence and severity of microvascular and macrovascular complications [30].

The most common diabetic complications due to microangiopathy are retinopathy, neuropathy and nephropathy that reflect the respective organ functional impairment and are time related [31]. On the other hand, according to our results, periodontal tissues are similarly affected from the “overflow” of glucose to the cells, since periodontitis is an infection that is twice as prevalent in diabetic individuals compared to non-diabetics [32].

It may be concluded that a clinical examination of oral and periodontal health status with histological evaluation (even if the findings are not definitive) as it has already been proved by previous experimental study in rats, may serve as a flexible index for the detection of other organ impairment and this may be a challenge for further research [33].

References

- [1] KHADER Y.S., DAUOD A.S., EI-QADERI S.S., ALKAFAJEI A., BATAYHA W.Q.: Periodontal status of diabetics compared with nondiabetics: a meta-analysis. *J. Diab. Complicat.* 2006, 20, 59–68.
- [2] LALLA E., LAMSTER I.B., STERN D.M., SCHMIDT A.M.: Receptor for advanced glycation end products, inflammation, and accelerated periodontal disease in diabetes: mechanisms and insights into therapeutic modalities. *Ann. Periodontol.* 2001, 6, 113–118.
- [3] SALVI G.E., CAROLLO-BITTEL B., LANG N.P.: Effects of diabetes mellitus on periodontal and peri-implant conditions: update on associations and risks. *J. Clin. Periodontol.* 2008, 35, Suppl. 8, 398–409.
- [4] GRAVES D.T., AL-MASHAT H., LIU R.: Evidence that diabetes mellitus aggravates periodontal diseases and modifies the response to an oral pathogen in animal models. *Compend. Contin. Educ. Dent.* 2004, 25(7 Suppl. 1), 38–45.
- [5] LOOMANS C.J., DE KONING E.J., STAAL F.J., ROOKMAAKER M.B., VERSEYDEN C., DE BOER H.C., VERHAAR M.C., BRAAM B., RABELINK T.J., VAN ZONNEVELD A.J.: Endothelial progenitor cell dysfunction: a novel concept in the pathogenesis of vascular complications of type 1 diabetes. *Diabet.* 2004, 53, 195–199.
- [6] PEPPA M., BREM H., EHRLICH P., ZHANG J.G., CAI W., LI Z., CROITORU A., THUNG S., VLASSARA H.: Adverse effects of dietary glycotoxins on wound healing in genetically diabetic mice. *Diabet.* 2003, 52, 2805–2813.
- [7] SHARP P.S., RAINBOW S., MUKHERJEE S.: Serum levels of low molecular weight advanced glycation end products in diabetic subjects. *Diabet. Med.* 2003, 20, 575.
- [8] VASAN S., FOILES P., FOUNDS H.: Therapeutic potential of breakers of advanced glycation end product-protein crosslinks. *Arch. Biochem. Biophys.* 2003, 419, 89–96.
- [9] KATZ J., BHATTACHARYYA I., FARKHONDEH-KISH F., PEREZ F.M., CAUDLE R.M., HEFT M.W.: Expression of the receptor of advanced glycation end products in gingival tissues of type 2 diabetes patients with chronic periodontal disease: a study utilizing immunohistochemistry and RT-PCR. *J. Clin. Periodontol.* 2005, 32, 40–44.
- [10] VLASSARA H.: The AGE-receptor in the pathogenesis of diabetic complications. *Diabetes Metab. Res. Rev.* 2001, 17, 436–443.
- [11] BASTA G., SCHMIDT A.M., DE CATERINA R.: Advanced glycation end products and vascular inflammation: implications for accelerated atherosclerosis in diabetes. *Cardiovasc. Res.* 2004, 63, 582–592.
- [12] SAITO T., MURAKAMI M., SHIMAZAKI Y., MATSUMOTO S., YAMASHITA Y.: The extent of alveolar bone loss is associated with impaired glucose tolerance in Japanese men. *J. Periodontol.* 2006, 77, 392–397.
- [13] Committee on Care and Use of Laboratory animals. Guides for the care and use of laboratory animals. Washington D: Institute of Laboratory Animals and Resources. National Research Council, 1985 p. 83.
- [14] OETTINGER-BARAK O., BARAK S., MACHTEI E.E., ARDEKIAN L., BARUCH Y., PELED W.: Periodontal changes in liver cirrhosis and post-transplantation patients. I: clinical findings. *J. Periodontol.* 2001, 72, 1236–1240.
- [15] RAMS T., OLER J., LISTGARTEN M., SLOTS J.: Utility of Ramfjord index teeth to assess periodontal disease progression in longitudinal studies. *J. Clin. Periodontol.* 2005, 20, 147–150.
- [16] GETTINGER G., PATTERS M.R., TESTA M.A., LOE H., ANERUD A., BOYSEN H., ROBERTSON P.B.: The use of six selected teeth in population measures of periodontal status. *J. Periodontol.* 1983, 54, 155–159.

- [17] FLEISS J.L., PARK M.H., CHILTON N.W., ALMAN J.E., FELDMAN R.S., CHAUNCEY H.H.: Representativeness of the "Ramfjord teeth" for epidemiologic studies of gingivitis and periodontitis. *Commun. Dent. Oral Epidemiol.* 1985, 15, 221–224.
- [18] KOMESU M.C., TANGA M.B., BUTTROS K.R., NAKAO C.: Effects of acute diabetes on rat cutaneous wound healing. *Pathophysiol.* 2004, 11, 63–67.
- [19] CHRISTOPHERSON K.: The impact of diabetes on wound healing: implications of microcirculatory changes. *Br. J. Commun. Nurs.* 2003, 8, S6–13.
- [20] MEALEY B.L., RETHMAN M.P.: Periodontal disease and diabetes mellitus. Bidirectional relationship. *Dent. Today* 2003, 22, 107–113.
- [21] KARIKOSKI A., ILANNE-PARIKKA P., MURTOOMA H.: Oral self-care and periodontal health indicators among adults with diabetes in Finland. *Acta Odontol. Scand.* 2001, 59, 390–395.
- [22] LIU H., BRAVATA D.M., CABACCAN J., RAFF H., RYZEN E.: Elevated late-night salivary cortisol levels in elderly male type 2 diabetic veterans. *Clin. Endocrinol. (Oxf)*. 2005, 63, 642–649.
- [23] TAKENAKA K., YAMAGISHI S., MATSUI T., NAKAMURA K., IMAIZUMI T.: Role of advanced glycation end products (AGEs) in thrombogenic abnormalities in diabetes. *Curr. Neurovasc. Res.* 2006, 3, 73–77.
- [24] KANTARCI A., VAN DYKE TE.: Resolution of inflammation in periodontitis. *J. Periodontol.* 2005, 76, Suppl. 11, 2168–2174.
- [25] SYRJALA A.M., YLOSTALO P., NISKANEN M.C., KNUUTILA M.L.: Role of smoking and HbA1c level in periodontitis among insulin-dependent diabetic patients. *J. Clin. Periodontol.* 2003, 30, 871–875.
- [26] LU H.K., YANG P.C.: Cross-sectional analysis of different variables of patients with non-insulin dependent diabetes and their periodontal status. *Int. J. Periodontics Restorative Dent.* 2004, 24, 71–79.
- [27] SIUDIKIENE J., MACIULSKIENE V., DOBROVOLSKIENE R., NEDZELSKIENE I.: Oral hygiene in children with type I diabetes mellitus. *Stomatologija* 2005, 7, 1, 24–27.
- [28] KINANE D.F., MARSHALL G.J.: Periodontal manifestations of systemic disease. *Aust. Dent. J.* 2001, 46, 2–12.
- [29] CAMPUS G., SALEM A., UZZAU S., BALDONI E., TONOLO G.: Diabetes and periodontal disease: a case-control study. *J. Periodontol.* 2005, 76, 418–425.
- [30] GROSSI S.G.: Treatment of periodontal disease and control of diabetes: an assessment of the evidence and need for future research. *Ann. Periodontol.* 2001, 6, 138–145.
- [31] YU Y., LYONS T.J.: A lethal tetrad in diabetes: hyperglycemia, dyslipidemia, oxidative stress, and endothelial dysfunction. *Am. J. Med. Sci.* 2007, 330, 227–232.
- [32] HEITZ-MAYFIELD L.J.: Disease progression: identification of high-risk groups and individuals for periodontitis. *J. Clin. Periodontol.* 2005, 32, 196–209.
- [33] TESSEROMATIS C., KOTSIUO A., PARARA H., VAIRAKTARIS E., TSAMOURI M.: Morphological changes of gingiva in streptozotocin diabetic rats. *Int. J. Dent.* 2009, 72, 5628.

Address for correspondence:

Christine Tesseromatis
Department of Pharmacology Medical School
University of Athens Greece Division of Oral Therapeutics
Mikras Assias 75 Goudi
11527 Athens
Greece
Fax: + 30 210 7462554
E-mail: ctesser@med.uoa.gr

Received: 6.07.2011

Revised: 29.07.2011

Accepted: 1.08.2011

Praca wpłynęła do Redakcji: 6.07.2011

Po recenzji: 29.07.2011

Zaakceptowano do druku: 1.08.2011