



Bodleian Libraries

UNIVERSITY OF OXFORD

This book is part of the collection held by the Bodleian Libraries and scanned by Google, Inc. for the Google Books Library Project.

For more information see:

<http://www.bodleian.ox.ac.uk/dbooks>



This work is licensed under a Creative Commons Attribution-NonCommercial-ShareAlike 2.0 UK: England & Wales (CC BY-NC-SA 2.0) licence.

PHYSIOLOGY






600035429T

PRESS	9 128
SHELF	5
No	2

16621 c. 44







A COURSE
OF
ELEMENTARY
PRACTICAL PHYSIOLOGY.



A COURSE
OF
ELEMENTARY
PRACTICAL PHYSIOLOGY,


BY

M. FOSTER, M.D., F.R.S.,
PRÆLECTOR IN PHYSIOLOGY AND FELLOW OF TRINITY COLLEGE,
CAMBRIDGE.

ASSISTED BY

J. N. LANGLEY, B.A.,
FELLOW OF TRINITY COLLEGE, CAMBRIDGE.

THIRD EDITION



London:
MACMILLAN AND CO.
1878

[All Rights reserved.]

Cambridge:
PRINTED BY C. J. CLAY, M.A
AT THE UNIVERSITY PRESS

PREFACE.

EVER since I began teaching Practical Physiology in University College, London, I have been in the habit of distributing among my students a syllabus to guide them in their work. By the introduction of fuller details what was at first a Syllabus has been changed into a Practical Course, which I now venture to publish in the hope that it may be found useful to others.

I fear that its use will be much restricted by the fact that in it Histology and Physiology are closely combined instead of being separated into two or more distinct courses. Although, in practice at least, I stand alone, I believe, in this matter, continued experience makes me more and more convinced that the plan which I adopt is, though troublesome, the safest one. Histological work, unless it be salted with the salt either of physiological or of morphological ideas, is apt to degenerate into a learned trifling of the very worst description; and students are generally only too ready to spend far too much of their time in the fascinating drudgery of cutting sections and mounting stained specimens. In morphological questions the physiologist has but an indirect interest; and details of microscopic structure ought only to occupy his attention in so far as they serve as a basis for physiological deductions. The reader in looking through this little book

will see that in its structure and function go hand in hand. In the case of each tissue or organ, as far as is practicable, the anatomy and histology are first studied, and then without delay the physiology, so that the student may, in learning what is known concerning the action of the part, form an opinion of the relative importance of the structural details.

The various topics are arranged in the order of my lectures, each Lesson containing the practical work corresponding to one or more lectures. In those lectures I first deal with the animal body as a collection of fundamental tissues, each tissue having a conspicuous and characteristic property or characteristic properties, and then consider the ways in which these tissues are arranged in mechanisms, and coordinated into an organic whole. Thus the student is first introduced to the structure and properties of blood, muscle, nervous tissue, and what, for want of a better name, I have called 'indifferent tissues'. Next comes the vascular mechanism, constructed out of the preceding tissues, and carrying on its work by means of their properties. I have found it practically convenient thus to break the series of fundamental tissues by the early introduction of this important mechanism. Returning to the fundamental tissues, the secreting tissues are next considered, under the divisions of the digestive, with which the lymphatics are not unnaturally taken, the respiratory, with which comes the respiratory mechanism, and the urinary, the practical work on the urine being an accompaniment to lectures on the general facts of nutrition. The great nervous mechanism of the body is then attacked, first as regards the special senses and then with reference to the spinal

cord and brain. The Lesson on the larynx is from its very nature disconnected from the others. The tissues of reproduction naturally form the subject of the concluding Lesson.

I have called it an Elementary Course because my class is divided into an Elementary and an Advanced Division, and this work is intended for the former only. I have found it, however, practically convenient to go into some subjects fully in the Elementary Class and to leave certain other subjects entirely for the advanced class. Thus while, on the one hand, some topics seem to be treated here in a more than elementary manner; others, on the other hand, *e.g.* the ear and hearing, binocular vision, &c., are entirely absent, being reserved for the advanced class.

I presuppose the student to have gone through a course of Elementary Biology, in which he has worked out the Lessons of Prof. Huxley and Dr Martin. He will thus have acquired a knowledge of the fundamental principles of Histology and Physiology, know how to use his microscope and possess a good acquaintance with the Anatomy of the Frog. The dissection of the dog and the rabbit as directed in Lesson I., in which attention is paid only to details of physiological importance, will at once put him in a position for the study of Physiology, strictly so called.

The instructions given are generally complete in themselves; but the student should have access to the Handbook of the Physiological Laboratory, to which (under the abbreviation *Hdb.*) he is frequently referred.

The demonstrations appended to each Lesson illustrate the lecture belonging to the Lesson, and are for the most

part observations or experiments too difficult for the student to carry out for himself. A list of them is given merely in order that the student may know what he has to see. Nothing therefore is said about the manner of executing them; I may, however, remark that none of them are painful, since they are of such a nature that anæsthetics where necessary can always be used.

The work marked out occupies my class the whole of two terms, *i. e.* from fifteen to eighteen weeks, the lectures being delivered twice weekly, and the practical work being carried on immediately after the lecture as well as on the intermediate days. The plan of work, in fact, closely follows that of Prof. Huxley in his *Elementary Biology*. It is, of course, not necessary that all the details of each chapter should be worked over by each student. Practical work of this kind is only of value in so far as it suggests or corrects ideas. The student who has mounted an exquisitely thin and beautifully stained section, is only just so much the worse for his pains (as far as physiology is concerned), if he does not understand what the section means. Hence, when the features of some of the fundamental tissues and the general working of the more important mechanisms have been really learnt, and the student has got, by doing things for himself, to know the value of a physiological experiment and the pitfalls that are hidden under carmine and Canada balsam, he may be safely trusted to fill in the details of his study by means of reference to mounted specimens and to mere demonstrations or even to descriptions of experiments. How much practical work is needed by each student must depend on a variety of

circumstances; and the choice of subjects studied in detail ought to be varied from time to time. In the Lessons, therefore, selection has been exercised to a very limited extent, and most of the topics have been treated with equal fulness.

In no case whatever are the directions given intended to be exhaustive. In the use of reagents, in the details of the microscopical work, and in the various experiments, the counsels given are those which have, on the whole, been found most useful for students in the laboratory. They are not in any way to be considered as forming a practical treatise on Histology or Physiology. That ground is already occupied by the Handbook for the Physiological Laboratory, to which the present little book may be looked upon as an introduction.

So much of the labour of preparing this volume for the press has fallen on my able Demonstrator, Mr J. N. LANGLEY, B.A., of St John's College, that his name naturally appears on the title-page as well as my own. To Prof. Huxley and to Dr H. N. Martin I am indebted for much valuable advice.

M. FOSTER.

TRINITY COLLEGE, CAMBRIDGE,
May, 1876.


PREFACE TO THE THIRD EDITION.

THE present Edition differs from the preceding one chiefly by the introduction of a Lesson, quite elementary in character, on the Structure of the Ear, and by some additions to the Lessons on the Connective Tissue group. Otherwise the changes are slight, and chiefly connected with improved histological methods.

M. FOSTER.

J. N. LANGLEY.

TRINITY COLLEGE, CAMBRIDGE,
December, 1877.



CONTENTS.

	PAGE
LESSON I.	
Dissection of a Rabbit and of a Dog	1—23
LESSON II.	
Structure of Blood	24—30
LESSON III.	
Coagulation of Blood	31—36
LESSON IV.	
Cartilage. Bone and Teeth	37—44
LESSON V.	
Connective Tissue	45—51
LESSON VI.	
Modification of Connective Tissue and Hyaline Cartilage—Ossification	52—55
LESSON VII.	
Structure of Contractile Tissue	56—61
LESSON VIII.	
Properties of Contractile Tissue	62—69

LESSON IX.

	PAGE
Structure of Nervous Tissue	70—76

LESSON X.

General Properties of Nervous Tissue—Automatic Actions	77—82
--	-------

LESSON XI.

Structure and Properties of Blood-Vessels	83—90
---	-------

LESSON XII.

Structure and Action of the Heart	91—98
---	-------

LESSON XIII.

Blood Pressure	99—105
--------------------------	--------

LESSON XIV.

Structure of Stomach and Salivary Glands	106—112
--	---------

LESSON XV.

Saliva and Gastric Juice	113—121
------------------------------------	---------

LESSON XVI.

Structure of Intestine. Bile and Pancreatic Juice	122—130
---	---------

LESSON XVII.

The Lymphatic System	131—138
--------------------------------	---------

LESSON XVIII.

Structure of Liver. Glycogen	139—142
--	---------

LESSON XIX.

The Structure of the Lung. The Mechanics of Respiration	143—147
---	---------

LESSON XX.

The Colour of Blood. Respiration	148—152
--	---------

LESSON XXI.

Structure of the Kidney	153—158
-----------------------------------	---------

CONTENTS.

XV

LESSON XXII.

	PAGE
Urine	159—164

LESSON XXIII.

Skin and Touch	165—172
--------------------------	---------

LESSON XXIV.

Olfactory and Gustatory Organs	173—177
--	---------

LESSON XXV.

The Eye	178—187
-------------------	---------

LESSON XXVI.

Vision	188—200
------------------	---------

LESSON XXVII.

The Ear	201—209
-------------------	---------

LESSON XXVIII.

Structure of the Spinal Cord	210—214
--	---------

LESSON XXIX.

Dissection of the Brain of a Dog or Sheep	215—227
---	---------

LESSON XXX.

Dissection of the Larynx	228—231
------------------------------------	---------

LESSON XXXI.

Tissues of Reproduction	232—239
-----------------------------------	---------

APPENDIX	241—253
--------------------	---------

INDEX	255—276
-----------------	---------





LESSON I.

DISSECTION OF A RABBIT AND OF A DOG.

In the following, the descriptions in large type apply more particularly to the rabbit, but the general directions for dissection serve also for the dog: some points in which the two animals differ, and some which are better seen in the dog, are put in small type.

¹A. 1. Make a median incision through the skin, down the whole length of the front of the body from the neck to the pubis, and reflect the skin as far as possible on both sides.

Observe the thin, pale, abdominal muscles. It is better to dissect out the individual muscles in the dog as below, but the dissection may be done on the rabbit.

In the dog observe

- a. The tendinous aponeuroses of the abdominal muscles forming in the middle line the white *linea alba*.
- b. The *externus obliquus abdominis*, a thin muscle, with descending fibres, stretching from the ribs above and from the back to the linea alba and the pubis.
- c. The *recti abdominis*, one on either side of the middle line, covered by the tendon of the externus obliquus.

If *b* be carefully reflected, there will be seen underneath :

¹ N. B. A and B should be carried out on the first day, in order that the viscera may be useful for microscopic observation, and the brain in good condition. If for any reason the dissection be delayed beyond the first day, the sections which are marked with an asterisk should be omitted.

d. The *internus obliquus abdominis*, with ascending fibres ;
and underneath the upper part of this

e. The *transversalis abdominis*.

2. Divide the abdominal wall carefully (so as to avoid wounding the intestine) in the middle line from the sternum to the pubis. From the middle of this incision make transverse incisions through the abdominal walls. Hook or pin back the four flaps.
3. Simply turning the parts over without cutting or tearing anything, trace out as far as possible the alimentary canal, making out the narrow **oesophagus**, the **stomach**, the **small intestine** not distinctly divisible into duodenum, jejunum and ileum, the large dark sacculated **cæcum** with its **appendix**, the **large intestine**, (puckered near the cæcum, but in its course becoming smoother and containing balls of fæces,) and lastly the **rectum**. (The student should avoid mistaking the cæcum for the large intestine.)
4. Trace out the **mesentery** which supports the intestine; observe its attachment to the vertebral column behind, its continuity with the lining membrane (peritoneum) of the abdominal cavity, and the manner in which the blood-vessels run in it.
Observe in the dog the loose fold of mesentery loaded with fat, hanging from the lower border of the stomach and forming the *great omentum*.
5. Observe the **spleen**, an elongated dark red body lying near the broad end of the stomach to which it is attached by a mesenteric fold (gastro-splenic omentum).
6. Turn the stomach over to the left (of the animal), gently stretch out the duodenum and observe in the mesentery belonging to it, the diffuse, pale red **pancreas**; trace the entrance of the pancreatic duct as a

pale thin band into the duodenum: this occurs rather more than a foot below the pylorus, where the duodenum turns back on itself to form a loop.

In the dog the pancreatic duct is close to the entrance of the bile-duct (see § 10).

Observe the mesenteric lymphatic glands, small greyish white lumps, more abundant in the duodenal mesentery.

7. Turning the stomach and intestines over to the right side, observe the **dorsal aorta**¹ descending through the diaphragm and giving off first the **coeliac artery**, and next the **superior mesenteric artery**. Just by the latter lies the left **supra-renal body**, small, oval and yellowish white; and a little above this, lying in the angle between the aorta and superior mesenteric artery, is the almost transparent **coeliac ganglion**, seen through the peritoneal membrane. Running into this, and crossing the aorta to do so, may be seen the **left splanchnic nerve**. Trace the latter up to the diaphragm. To see these structures more distinctly, the peritoneum and any fat which may be present can be torn aside with a blunt needle, care being taken not to injure the splanchnic nerve. Observe on the oesophagus the left **pneumogastric nerve**, dividing into many fibres; some of these are joined by fibres from the right pneumogastric: trace the branches to the coeliac ganglion.
8. Then turning the stomach and intestines over to the left side, tear away the connective tissue round the right supra-renal body, being careful not to puncture

¹ The arteries may be distinguished from the veins by their containing after death little or no blood, and therefore appearing of a bluish white colour, with a central tint of pink, whereas the veins are of a full dark maroon colour.

the vena cava. Underneath the supra-renal body, or very nearly so, will be seen the right cœliac ganglion, not so large as the left, but having a splanchnic nerve in connection with it. Trace out the nerve.

In the dog the right cœliac ganglion is a little in front of, and nearer the middle line than the supra-renal body. Note the number of pale nerves which are given off, proceeding more especially to the stomach, liver and kidneys.

The left cœliac ganglion will be found in a corresponding position on the other side.

9. With the stomach and duodenum still turned to the left side, trace out the union of the mesenteric, splenic, and gastric veins to form the **vena portæ**, and the entrance of that vein into the liver. Observe the **vena cava inferior**, and entrance into it of the **hepatic veins** immediately below the diaphragm.
10. Turning the liver up towards the diaphragm, the **gall-bladder** will be seen in a fossa on the under surface of the posterior right lobe: trace the cystic duct arising from this to run into the **hepatic duct**, proceeding from the liver itself; trace the united duct or common bile duct into the duodenum, close to the pylorus.
11. Trace out the division of the cœliac artery into the hepatic, splenic, and gastric arteries: trace out also the main branches of the superior mesenteric artery. Observe here C § 3, p. 11, since the diaphragm may be punctured in removing the liver.
12. Place a double ligature round the rectum and divide between the ligatures: do the same with the œsophagus. Ligature the hepatic veins as close as possible to their entrance into the vena cava and cut

through the hepatic veins on the liver side of the ligature. Turning the intestine to the right, cut through the mesentery and remove from the abdomen the alimentary canal and its appendages.

13. Cut open one of the hepatic veins and trace it in this way back into the substance of a liver lobe. Observe on its inner surface the opening of numerous smaller veins; cut through the lobe near its base, and try to distinguish the portal veins from the hepatic by the small artery and bile duct running alongside each of the former.
- *14. Cut off several small pieces of the liver, about the size of a bean, and place them in Müller's fluid. Change the fluid next day; and after three weeks transfer to 50 per cent. alcohol, leave for two days and transfer to 75 per cent., leave one day and then put in absolute alcohol until required for sections.

In the following sections, when tissues are directed to be placed in Müller's fluid, potassium or ammonium bichromate, chromic acid, &c.; it is to be understood that they are to be subsequently treated as above with alcohol, unless the contrary is stated.

15. Cut away the mesentery from the alimentary canal, and trace out the latter along its whole length, observing more fully the features mentioned in § 3, and noting in addition one or more white patches (Peyer's patches) on the free surface of the ileum, due to clumps of lymph-follicles, also note the connection of the cæcum with the small and large intestine, the thin walls of the cæcum and the thicker spotted walls of the appendix proceeding from its extremity.

Note in the dog, the wider œsophagus entering into the stomach nearer the cardiac end than is the case with

the rabbit; note also the shorter length of the intestine, the small cæcum, and the less difference between the large and small intestines.

If the intestine is not wanted for microscopical purposes, it may be washed out before cutting through the mesentery by tying a tube with a funnel at one end into the duodenum, and letting water from a tap stream down the funnel.

16. In the dog (if dissected within 24 hours of its death)
 - **a.* Cut some of the pancreas into small bits the size of peas, and place in absolute alcohol.
 - b.* Remove as much fat as possible, and mince the remainder, dry with blotting-paper, and cover with glycerine to serve for the preparation of ferment. Cp. p. 128 § 2.
- *17. Lay open the stomach, throw away the contents, and wash the surface once with normal saline solution.
 - a.* Cut out a piece one inch square from the middle region, and place in Müller's fluid.
 - b.* Place a similar piece at once into absolute alcohol.
 - c.* Place in alcohol, or Müller's fluid, one or two small pieces, taken from the pyloric end.
Before placing in the reagents, the pieces should be pinned out (best with small porcupine quills) on a piece of cork to prevent distortion by contraction of the muscular coat.
 - d.* From the remainder of the middle region of the stomach remove the mucous membrane from the muscular coat; mince the former finely; dry it somewhat by pressing it between blotting-paper, and cover it with strong glycerine in a small flask or bottle.

18. Wash out the duodenum, observe the openings of the biliary and pancreatic ducts, and carefully pass a bristle through them into the ducts.

Lay open a portion of the jejunum, wash it, and examine the villi with a lens.

- *19. Lay open another portion, about an inch long, wash it once with normal salt solution, divide it into two pieces. Pin these out on cork, and place one in chromic acid .5 per cent., and the other in Müller's fluid. Lay open several inches of the ileum by an incision carried along the mesenteric attachment. Cut out the Peyer's patches, and place them in Müller's fluid.
20. Take a piece of the large intestine, cut it open and wash, look at it with lens; there are no villi.
- *21. Place two or three small pieces of the spleen in ammonium bichromate 5 per cent.
22. Note again the position of the supra-renal bodies.
23. Note the position of the **kidneys**, the left being much nearer the pelvis than the right; trace out the renal artery and vein. Observe the **ureter**, a pale semi-transparent duct passing downwards from the kidney over the muscles of the back, towards the middle line; trace it down to its end in the urinary bladder.
24. If a female, observe the **uterus**, with its two cornua prolonged into the Fallopian tubes. Near the end of each Fallopian tube a little below the kidney will be seen a small, somewhat oval, spotted body, the **ovary**.
25. If a male, observe the **testis** in its serous pouch, the **epididymis**, and the **vas deferens**; trace the vasa deferentia to their entrance into the **urethra**.

26. Divide the symphysis pubis, stretch the two halves apart, and with the bone-forceps cut away as much bone on each side as may be necessary. Observe the prostate, surrounding the first part of the urethra. Lay open the **bladder**, observe its neck, ending in the urethra, and the entrance of the two ureters at its base. Pass a probe down each ureter into the bladder.
- *27. Divide one kidney longitudinally, and observe the cortex, medulla, and pelvis. Divide one half into four or five pieces, each containing cortex and medulla; treat some with ammonium bichromate 5 p.c., the rest with absolute alcohol.
- *28. *a.* Make two or three incisions into the ovary, rubbing the surface as little as possible, and treat it with a mixture of equal parts of chromic acid .5 p.c. and alcohol 90 p.c.
- b.* Cut off two or three pieces of testis, and one or two of the epididymis, not larger than a pea, and treat with chromic acid .2 per cent.
- *29. Cut off one or two pieces of bladder, and treat with Müller's fluid.
- B. 1. Make a median incision over the skull from the nose to behind the level of the ears. Reflect the skin on each side. Cut away the attachment of the muscles of the neck to the occiput until the occipito-atlan-toidean membrane between the occiput and the atlas is laid bare. Carefully divide this with scissors and observe the medulla oblongata.

With a trephine saw through the roof of the skull in its broadest part, a little behind the orbits, working very carefully when the bone is nearly sawn through. With an elevator raise the circular piece of bone and

remove it. Then with the bone-forceps cut away piecemeal the rest of the roof of the skull.

Observe the smooth **cerebral hemispheres**, somewhat triangular in form; in front of these and separated from them by a constriction, the elongated **olfactory lobes**. Behind the cerebral hemispheres lies the laminated **cerebellum** (the outlying lateral portions of which are lodged in pits in the skull), and behind this again is seen the **medulla oblongata** with the fourth ventricle. On the surface of the cerebrum may be seen the *dura mater* and *pia mater*, but these are better seen in the dog.

2. In the dog observe

- a. The *dura mater*, a thick and very resistant membrane; its prolongation between the cerebral hemispheres as the *falx cerebri* and between the cerebellum and cerebrum as the *tentorium*.
- b. The *pia mater*, underneath (a), and immediately covering the brain; note the blood-vessels running in it.
- c. The *pia mater* dips down into the sulci, between the convolutions, and here may be observed, above the *pia mater* and bridging over the sulci the thin transparent arachnoid membrane, also distinctly visible as a covering to the *pia mater* at the base of the brain. In the spaces between the arachnoid and *pia mater* is contained the clear watery sub-arachnoid (or cerebrospinal) fluid. A smaller quantity of fluid also exists between the arachnoid and *dura mater*.
- d. The relative sizes of cerebrum and cerebellum.
- e. The general appearance of the cerebral convolutions.

3. With a scalpel divide the front of the cerebral hemispheres from the olfactory lobes. Lift up with the handle of a scalpel the extreme front of the cerebrum,

and turning it backwards bring into view the optic nerves. Cut these through with a sharp pair of scissors close to the skull. Still turning the brain back cut through successively all the other cranial nerves. A little behind the optic nerve is the small but evident third nerve (motor oculi), close behind this the considerably smaller fourth nerve (trochlear), farther back in the hollow behind the attachment of the tentorium lies the thick fifth nerve, to the median side of which the small sixth (abducens) is fairly conspicuous. A little behind and to the outside of the fifth, in the hard petrous bone are seen together the seventh (facial) and eighth (auditory). Some distance back and nearer the middle line come the ninth (glossopharyngeal), tenth (pneumogastric), and the small eleventh (spinal accessory). Lastly, still farther back is the twelfth (hypoglossal). Finally, cut through the spinal cord below the medulla oblongata, and remove the brain entirely.

The outlying lateral portions of the cerebellum will probably be left in the skull. Do not injure the skull in attempting to get them out.

4. Placing the brain bottom upwards observe the superficial origin of the above cranial nerves. (These will be studied more carefully in a subsequent lesson.)
Place the brain in spirit.
5. In the dog repeat § 3 and 4, observing in addition the basilar artery uniting with the internal carotid arteries to form the circle of Willis, which will be seen more distinctly in the dog than in the rabbit.
- *6. Remove one eye, puncture the cornea, make a slight incision in the thin part of the sclerotic behind the cornea and place it in strong spirit.

- C. 1. Examine the **diaphragm**, marking well its shape; observe the central tendon and the radiating muscular bundles, their attachment to the chest-walls; the orifices of the œsophagus, aorta, and vena cava.
2. Make similar observations on the dog, where the diaphragmatic muscles are much more fully developed.
3. Through the transparent tendon of the diaphragm the lungs are visible in close contact with it. Puncture the tendon, and observe the collapse of the lungs upon the entrance of air into the pleural cavity.

In the dog

4. Observe the *pectoralis muscle* consisting of the *sternal* and *costal pectoral*, the former partly overlying the latter. Cut through the sternal pectoral in its middle and reflect the two ends. Observe its attachment to the upper part of the sternum and to the humerus. Observe the attachment of the costal pectoral along the greater part of the sternum below the sternal pectoral.
5. Observe the costal cartilages and their connection with the ribs and sternum.
6. Observe the *serratus magnus* proceeding from the whole length of the internal border of the scapula to the first seven ribs. Cut this through the middle.
7. Note the course of the fibres of one of the *external intercostals* about an inch from the end of the bony rib. Trace it forward to about the juncture of the rib and cartilage where it ends in a free border and the fibres of the *internal intercostal* pass beneath it. Beginning at this free border remove the external intercostal, laying bare the internal intercostal; trace also the intercartilaginous part of the latter.
8. Turning the animal on its side observe the *serratus anticus*, arising from a single flat tendon lost amongst

the muscles of the neck and dividing into bundles going from the 4th rib to the 10th inclusive.

9. Dissect away the conspicuous longitudinal muscles covering the vertebral ends of the ribs, and observe the *levatores costarum* arising from the transverse processes of the dorsal vertebræ and proceeding to the ribs below.
10. Cut through the costal cartilages at their junction with the ribs, beginning at the second; divide the sternum between the 1st and 2nd ribs, and remove the sternum with the costal cartilages. While removing it observe the **mediastinum** separating the two pleural cavities, and enclosing the heart and pericardium.
- *11. Place a small piece of costal cartilage in a concentrated aqueous solution of picric acid.
12. Observe the **pericardium**, lay it open in the median line.
13. Observe the **vena cava inferior**—and, on each side of the heart, just inside the mediastinum, the conspicuous **phrenic nerve** distributed to the muscles of the diaphragm. Trace one phrenic nerve up until it is lost in the tissue at the top of the chest. Avoid cutting it.

Turning in the dog the heart and lungs over to the right, pull up the large aortic trunk, and note the almost transparent **thoracic duct**, lying alongside the œsophagus; trace it up to its termination into the venous system (at the junction of the left jugular and subclavian veins, cp. § 17, p. 13).

14. Prolong the median skin incision to the chin and reflect the skin as far as possible. Observe on each side the external jugular vein dividing into two branches; avoid wounding it.

15. Cut through in the middle line the thin superficial muscle (platysma); draw it to one side, clearing away the connective tissue. Lying on either side of the muscles immediately surrounding the trachea will be seen the sterno-mastoid muscle diverging from the lower part of the neck. Separate this and draw it to one side; there will be seen the **carotid artery**, and running along the outer side of this the **pneumogastric nerve**. Free in one place the carotid, and lift it up with a hook. In the underlying connective tissue will be seen two nerves more or less closely united by tissue; the larger is the **sympathetic**, the smaller the superior cardiac (**depressor**).
16. Clear away the connective tissue from the artery. Draw the larynx from the carotid by means of a hook to which is tied a string having a weight at the end. Passing *over* the carotid at the level of the larynx will be seen the descendens noni. Cut this through and remove it entirely. Passing *underneath* the carotid nearly at the same level is the **superior laryngeal** branch of the pneumogastric. Trace this *with especial care*; soon after it leaves the pneumogastric it will be seen to give off a small nerve, the depressor. Follow this down the neck, separating it from the sympathetic. Sometimes the depressor receives a branch direct from the pneumogastric. Occasionally this is its sole origin.
17. Remove the first rib and the remains of the sternum, avoiding any injury to the tissues below. Observe the **thymus**, a fatty looking body covering the roots of the great vessels. It may be torn away. Trace out on each side the junction of the jugular and subclavian veins to form respectively the **right** and **left venæ cavæ superiores**.

18. Observe the right vena cava superior passing straight down to join the right auricle; the left vena cava superior passing obliquely downwards underneath the left auricle to join the right auricle; and the inferior vena cava passing upwards from the diaphragm to join the right auricle.
19. Trace up one **phrenic** nerve. It makes its way out of the thorax by the side of the superior vena cava, and then passes beneath it. Place a double ligature round the vein and divide between the ligatures. Follow up the phrenic to its origin from the 4th and 5th (and also from the 6th and 7th) cervical nerves.
20. Trace out the arch of the aorta by clearing away the tissue from its upper surface. Take care not to injure the pneumogastric nerves (see next section). Observe on the right side the **innominate artery**, which gives off first the **left common carotid**, and then divides into the **right subclavian** and **right common carotid**; on the left side the **left subclavian**.
• Note the vertebral artery on either side proceeding from the subclavian.
21. Trace both pneumogastric nerves downwards, observing the **recurrent laryngeal** branches passing on the right side round the subclavian artery, and on the left round the aorta. Place a double ligature round the innominate artery and divide between the ligatures. Trace the recurrent laryngeal nerves along the back of the trachea to the larynx. Pursue the main pneumogastric trunks on the œsophagus to the point where they were seen in A, § 7.
22. Trace the sympathetic nerve downwards to the **inferior cervical** ganglion lying a little above the sub-

clavian artery, and close to the vertebral artery; follow it thence to the **first thoracic ganglion**.

Observe the branches going from these ganglia to the heart. Observe also the depressor nerve passing to the heart.

From the first thoracic ganglion trace down the thoracic sympathetic lying on the heads of the ribs with the ganglia (twelve in all) and the **rami communicantes** connecting each ganglion with its corresponding spinal nerve.

Trace out the **splanchnic** on one side; it will be found to separate from the sympathetic at the 8th, 9th, or 10th thoracic ganglion. At first sight it appears to be the continuation of the sympathetic instead of a branch of it; since the sympathetic at its lower part becomes more transparent, and running in a groove between two muscles, is rather easily overlooked.

The splanchnic receives branches from each of the thoracic sympathetic ganglia below its origin.

23. Cut out the heart with the lungs attached, and trace the **pulmonary arteries and veins**.

The heart may here be dissected by help of the directions given for the dissection of a sheep's heart in Lesson XII., or its dissection may be omitted.

24. Having reflected on either side the skin of the neck of the dog, and cleared away the fascia of connective tissue, observe the muscles underneath.
- a. The *sterno-hyoid* one on either side of the median line.
 - b. The *sterno-thyroid* lying immediately outside (a) for the greater part of its length.

- c. The *thyro-hyoid*, a small muscle of the larynx external to (a) in the upper part of its course.
 - d. The *sterno-mastoid* external to (b) and covering it near the hyoid bone, thence it proceeds outwards, and disappears under a white oval mass, the submaxillary gland.
25. Carefully separate the sterno-mastoid from the sterno-thyroid; the sympathetic-pneumogastric trunk and the carotid artery will come into view.
26. Observe the following points in which the dog differs from the rabbit:
- a. There is but *one* superior vena cava formed by the junction of the *two innominate veins*.

(The arrangement of the main arteries is usually that described for the rabbit, but considerable variations occur.)

- β. There is in the neck no separate nerve corresponding to the depressor in the rabbit.
 - γ. The sympathetic is intimately united with the pneumogastric in the greater part of its course. Low down in the neck it separates from the pneumogastric, though still running in the same sheath with it, until it reaches the inferior cervical ganglion. Issuing from this it diverges from the pneumogastric, going to the large elongated first thoracic ganglion.
- D. 1. Make an incision over the knee, and remove the skin for some distance above and below it. Observe the **fascia** covering the muscles of the thigh and leg, the fibrous **capsule** of the knee-joint, and the patella.
2. Remove the fascia, dissect out the lower part of some of the muscles of the thigh, cutting them across in

the middle, and observe the attachment, direct or by tendon, to the bones, and the continuation in some cases (e. g. *musc. sartorius*, the thin broad muscle running obliquely across the thigh) of their tendons into the capsule of the knee-joint.

3. Observe the **lateral ligaments** or fibrous strengthenings of the capsule.
4. Move the joint until the edges of the femur and of the tibia are felt, and make a transverse incision through the capsule between the two bones. Observe the **synovial fluid**.
5. Bend the knee so as to bring the **crucial ligaments** into view and divide them; divide also the lateral ligaments, and expose completely the ends of the bones.
6. Examine the extent of the synovial sac. Observe the articular ends of the bones, their cartilaginous coverings, and their form. Observe the interarticular cartilages.
7. Remove the fascia, and clean any one of the muscles of the leg.
Observe its attachment to the tibia (or fibula) above, notice the fascicular construction of the muscle; the entrance of nerves and blood-vessels. Observe how the muscular bundles end below in the tendon.
8. Trace the tendon down into the foot. Observe its synovial sheath.

- E. 1. Remove the skin from the other leg, and note the external saphena vein running across the lower front part of the leg and proceeding up on the posterior outer border of the thigh. In this part of its course it is superficial, and is very convenient in physiological experiments for injecting substances into the blood.

2. In the inner part of the thigh will be seen an almost median depression; cut through the tendon and muscle along this, and observe the crural artery, vein and nerve giving off various branches.
 3. Cut through the thick mass of muscle on the posterior internal part of the thigh, and note the large sciatic nerve.
- F. The Student should have a rabbit's and a dog's skull before him, and make out the several openings by which the nerves spoken of below issue from the skull.
1. Sever the neck at its lower part from the trunk, and reflect the skin from the side of the head. Place the head on one side. At the base of the ear will be seen the small parotid gland. From its anterior border issues the **facial** (7th) nerve, branching almost immediately; these branches may be traced to certain facial muscles.
 2. Carefully pushing upwards the facial nerve close to the parotid gland, the small pale duct of Stenon will be seen. Satisfy yourself that it is a duct, by gently pushing a bristle down it. Its course need not be traced.
The duct is seen much more readily in the dog.
 3. Dissecting away the parotid gland, trace the facial nerve to its exit from the skull by the stylo-mastoid foramen; observing the branches going to the muscles of the ear. Whilst still in the skull the facial gives off the chorda tympani. See § 13.
 4. Behind the parotid gland will be seen a nerve running from the under surface of the sterno-mastoid muscle, dividing into two branches, and passing up the ear. This is the **great auricular**, which arises from

the 3rd cervical nerve, and is the main sensory nerve for the ear. Trace as far as possible its course in the ear.

5. Place the head resting on the lower jaw, and clear away the skin from the base of the ear; a somewhat flat piece of cartilage will come into view. In the normal animal this can be felt by passing the finger from the occipital spine outwards towards the ear. Through this cartilage runs another sensory nerve of the ear, the **posterior auricular**. Carefully clear away the connective tissue on either side of the cartilage, and trace the nerve forwards into the ear. Trace it also backwards along the neck, to its origin from the 2nd cervical nerve.
6. Now follow up the course of the **pneumogastric** from the place where it was left in C. § 16. A little above the superior laryngeal branch will be seen the pharyngeal nerve. Still a little higher up, the trunk presents a fusiform enlargement, the **ganglion** of the **trunk**. Note the large nerve (**hypoglossal**) running across the pneumogastric a little below the ganglion. Observe at the same time the sympathetic nerve passing into the **superior cervical ganglion**, and the fibres given off from this accompanying the branches of the carotid artery.

In the dog the united sympathetic-pneumogastric trunk divides at this point into the sympathetic with its ganglion, and the pneumogastric with its ganglion.

7. In the dog, in which the skin has been reflected, the outline of a muscle attached to the inner part of the extremity of the lower jaw will be seen, this is the digastric. Clear away as much as possible the connective tissue surrounding it, carefully cut it through,

and turn back the cut ends; the *submaxillary duct* will be seen running from the submaxillary gland, and passing (in the position of the animal) underneath the mylohyoid muscle.

Cut through the middle of the latter, parallel to the jaw, taking care not to injure the tissues below; reflect the cut ends. In the fascia below the muscle will be seen the continuation of the submaxillary duct. Crossing the duct not far from the free lower border of the mylohyoid muscle runs a nerve, the *lingual* or gustatory, a branch of the 5th. It is seen coming from underneath the jaw, and passing on to the tongue. Just before it crosses the duct it gives off a small branch, *chorda tympani*, which turning back runs to the duct, and thence to the gland. In the triangle formed by lingual, chorda, and duct, lies the small submaxillary ganglion.

In the middle line is seen the hypoglossal passing to the muscles of the tongue.

8. Trace the chorda tympani back towards the gland. Trace the lingual towards the tongue, it will be found to be mainly distributed to the tip of the tongue.
9. Trace the submaxillary duct from the gland on towards the tongue. Lying on it in its course is seen the small lobulated *sublingual gland*, and issuing from the gland, the sublingual duct. The two ducts run side by side, the submaxillary duct being the larger, and nearer the median line.
10. In the rabbit, when the skin and underlying fascia have been reflected, there will be seen between the angles of the jaw the tolerably compact-looking, but soft submaxillary glands meeting one another in the middle line. Trace forward the duct, passing (in the position of the animal) from the under surface of the

upper part of the gland, beneath the digastric near its tendinous insertion, and then beneath the mylohyoid. Here the digastric is a thin elongated muscle with conspicuous tendon. Make out as in the dog the lingual and hypoglossal nerves. The chorda tympani, being small, will not be easily seen.

11. Partly saw through the symphysis menti, then use a lever and force the rami asunder, and in the following dissection cut through or remove any muscles necessary.
12. Trace the lingual backwards. It will be found to join the inferior dentary (a large nerve entering into the lower jaw), to constitute, with other branches, the **inferior maxillary** nerve. Trace this back to the front edge of the tympanic bulla.
13. The lingual, almost immediately after its leaving the inferior maxillary, receives a small nerve, the chorda tympani. Carefully trace the latter backwards; it will be found to make its exit from the skull by the Glaserian fissure, near and rather to the outside of the tympanic bulla.

If this is not seen in the rabbit, it should be traced out in the dog.

14. Trace the hypoglossal nerve forwards from its point of crossing the pneumogastric. It will be found to terminate in the muscles of the tongue.
15. Trace up the pneumogastric beyond its ganglion, to near its exit from the skull by the foramen jugulare; (observe the foramen on the prepared skull).
Note, passing from the skull with the pneumogastric, the small **spinal accessory** nerve behind and the **glosso-pharyngeal** in front; the communicating branches between these nerves may be neglected.

16. Trace the glosso-pharyngeal forwards to the tongue and pharynx. It runs somewhat parallel to, but at a higher level than, the hypoglossal, and may be traced to the hinder part and to the sides of the tongue.
17. Cut through the above three nerves, at some distance from the skull, break away with small bone forceps the tympanic bulla, and trace back more thoroughly the exit from the skull of these nerves and of the hypoglossal. The latter issues through the condyloid foramen, which is separated by a distinct width of bone from the foramen jugulare, through which the other three issue.
18. Saw through the base of the skull and the face, from the occiput to the nose, nearly in the median line, but leave the nasal septum entire on one half. Divide carefully with a scalpel the soft palate and the roof and back of pharynx.
Observe the cavity of the nose, the anterior and posterior nares, the turbinate bones, and the Schneiderian membrane.
19. Looking down into the pharynx, observe the **epiglottis** at the root of the tongue, the glottis of the larynx and the vocal cords.
Look at the side of the pharynx for the opening of the Eustachian tube, pass a probe up it into the tympanic cavity. Pass another probe down the meatus externus and, rupturing the membrana tympani, make sure that the first probe has entered into the tympanic cavity.
20. Remove the larynx. Observe the position and relations of the hyoid bone. Divide the larynx by a me-

dian incision in front; observe the vocal cords, the arytenoid, cricoid and thyroid cartilages.

In the dog put the larynx in weak spirit, for dissection at a later period.

21. With a pair of bone forceps remove piecemeal the roof of the orbit which still contains the eye, leaving a broad ring of bone round the optic nerve. Imbedded in the fat will be found the muscles of the eyeball. Trace out the origin and insertion of the four *recti* and two *obliqui*.
22. Immediately below, and in front of the eye, the **superior maxillary nerve** will be found issuing from a foramen in the superior maxillary bone, to supply the skin of the face, &c., with sensory fibres. Cutting away the bone with a small pair of bone forceps, trace this nerve back along the floor of the orbit.
Trace at the same time the inferior maxillary nerve.
23. In the upper part of the intact orbit of the dog will be found a nerve, the *ophthalmic nerve*. It passes from the front of the orbit to the forehead.
24. These three, the ophthalmic, the superior and the inferior maxillary nerves, when traced back, will be found to unite into one large nerve, the fifth or **trigeminal**. Observe on the nerve at the junction of the three branches, the swelling of the **Gasserian ganglion**.
Observe also that the nerve in leaving the brain has two roots, a small and a large, that the small root passes beside the ganglion on the large root, without entering into it, and that the fibres of the small root are, beyond the ganglion, almost entirely confined to the third or inferior maxillary branch.

LESSON II.

STRUCTURE OF BLOOD.

A. BLOOD OF FROG OR NEWT.

1. Place a drop of blood on a glass slide and close to it place a drop of normal saline solution, but so that they do not run into one another. Carefully cover with a cover-slip, avoiding air-bubbles. At the line of junction of the two drops the corpuscles are few, and can there be best examined for special characters. Look at the slide first with the naked eye, then with objective no. 3 or 4, and finally with objective no. 7 or 8.
2. Examine the **red corpuscles**, and observe that
 - a. Each red corpuscle is a flattened oval, of some breadth when viewed flat, narrow when seen in profile.
 - b. Seen singly, each corpuscle appears to be of a pale yellow colour, the tint being equally diffused throughout its substance. Where several corpuscles lie one over the other, they together appear red.
 - c. In a carefully prepared specimen, many of the corpuscles appear homogeneous; in others there is visible, owing to changes which have taken place, a central slightly darker oval spot, the nucleus.

- d. There is a very considerable uniformity in the size of the red corpuscles. Measure the long and short axes of two or three. The simplest mode of measuring objects under the microscope is as follows :

Place a drawing-pad in a firm position close to and on a level with the stage of the microscope. Looking through the tube of the microscope with one eye, keep the other open also. An image of the field of the microscope with the corpuscles will appear on the drawing-pad ; and the outline of a corpuscle may, with a little practice, be traced.

Substitute for the object the stage micrometer, marked with lines, which are small fractions of an inch or of a millimetre apart. Trace these in the same way on a piece of cardboard, taking care that the cardboard is at exactly the same level as the drawing-pad was previously. Then if the stage micrometer is divided into say $\frac{1}{100}$ of a mm., and in the drawings a corpuscle corresponds exactly to one division, its size is evidently $\frac{1}{100}$ of a mm. The cardboard can be kept as a scale, and tracings of any object *drawn at the same level*, with the same magnifying power, may be directly measured by it. Of course for each objective, and each ocular, and for each position of the draw-tube, a separate scale is necessary.

With a camera lucida the same mode of measurement is much easier.

In this and succeeding lessons the student is re-

commended to measure all the more important structures.

3. Bring a drop of dilute acetic acid (1 p. c.) on the glass slide, so that it just touches one edge of the cover-slip. Be careful that the acid does not flow *over* the cover-slip. Place on the slide a small piece of blotting-paper, touching the opposite edge, so as to absorb the fluid under the cover-slip on that side. There will then be a current from the drop of acetic acid to the blotting-paper. It is best to arrange that the current is mainly along the line of junction of the blood and saline drop. Observe the changes in the red corpuscles, looking first at those which the acid has just begun to attack, and then at those more fully acted upon. Note that
 - a. The corpuscles become more egg-shaped, swelling up from the *absorption of fluid*. Most after a time become spherical.
 - b. The nucleus becomes more and more distinctly visible, and as it does so becomes granular and often irregularly rod-shaped.
 - c. The colouring matter is either concentrated around the nucleus, or more usually disappears from the corpuscle being dissolved in the fluid.
 - d. The outline of the corpuscle is seen as a faint round or oval line at some distance from the nucleus. Observe the not infrequent excentric position of the nucleus.
 - e. Some corpuscles are much more readily acted on than others.
4. Place on the centre of a *very clean* cover-slip a fresh drop of blood from a frog just killed. Rapidly and yet carefully place on a glass slide (also scrupulously

clean) the cover-slip, with the drop of blood undermost, and with the point of a needle gently move it about until the drop is spread over its whole area. Cement with paraffin A.¹ (which melts at 39° C.) in the following manner. With a morsel of blotting-paper dry if necessary the slide at the edges of the cover-slip. Keep the cover-slip in place by gently holding a needle against one edge, and, with a small brush, brush very carefully the melted paraffin over the edges all round. The paraffin need not extend more than $\frac{1}{8}$ or $\frac{1}{2}$ inch over the cover-slip. In a few minutes the paraffin becomes solid, and thus the fluid underneath is protected from evaporation.

5. Neglecting the red corpuscles, search, in the spaces where these are scanty, for the **colourless corpuscles**. Be careful not to confound with the colourless corpuscles any of the granular nuclei which may have escaped from the red corpuscles. Observe that
 - a. They are much fewer than the red.
 - b. They are smaller than the red, but not uniform in size.
 - c. They are of variable form, sometimes spherical but more frequently of irregular outline, and marked with protuberances.
 - d. They are colourless and granular. Some are much more coarsely granular than others.
 - e. They possess a transparent nucleus of round or irregular shape, sometimes more than one: since the refractive index of the nucleus differs very slightly from that of the surrounding protoplasm, its outline is seldom visible except when the

¹ See Appendix.

corpuscle is very flat. Do not confound a heap of granules or a protuberance with the nucleus.

6. Examine several of the colourless corpuscles until you find one actively engaged in *amœboid movements*. Watch the movements carefully, sketching the outline of the corpuscle every twenty seconds. If the movements are not satisfactory, warm the slide on the hot stage. (Hdb. p. 7.)
7. Scrape away a little of the paraffin on opposite sides of the cover-slip and irrigate with normal salt solution. As the corpuscles are carried along in the current, note the elasticity of the red corpuscles shewn by their regaining their form after it has been altered by meeting an obstacle; note also that the white corpuscles more frequently stick to the glass and to obstacles than the red. (Cp. Lesson XI. § 5, *c* and *e*.)
8. Take a fresh drop. Do not cement. Having found a characteristic white corpuscle, irrigate very cautiously with dilute acetic acid as in § 3, keeping the corpuscle in view. The corpuscle, when the acid reaches it, becomes more transparent but shews several dark granules, and a granular nucleus, often irregular or lobed, comes into view.
9. Let a drop of blood fall into a few drops of 2 p.c. boracic acid (made with normal salt solution instead of water). A little may be observed under the microscope at once or after some time. Note that the colouring matter instead of being diffused over the whole corpuscle is almost entirely around the nucleus, and that the nucleus is often excentric and in some cases extruded with the colouring matter from the colourless stroma.

B. HUMAN BLOOD.

1. Take a drop of blood from the finger and cover as speedily as possible with a cover-slip. The glasses should be perfectly clean, and the layer of blood so thin that the red colour is hardly visible. It is as well to breathe on the under surface of the cover-slip immediately before putting it on. Observe the red corpuscles.
 - a.* Soon after being taken from the body they stick to one another, and, owing to their shape, usually in rouleaux.
 - b.* They roll about readily, when the cover-slip is lightly touched.
 - c.* They are yellowish, circular bi-concave discs, so that when seen in profile they appear dumb-bell shaped.
 - d.* They appear homogeneous, and possess no nucleus. On focussing down, they first appear clear on the outside and dim in the centre; then dim on the outside and clear in the centre; lower still the first appearance is reproduced; this serves to indicate their biconcave form.
 - e.* Towards the outside of the drop, where evaporation is going on, many of the red corpuscles are crenate.
 - f.* They are much smaller than the red corpuscles of the frog. Measure them.
2. Observe the white corpuscles. Look for them in the open spaces where the red corpuscles are few.
 - a.* They do not readily roll about. They are somewhat adhesive.

LESSON III.

COAGULATION OF BLOOD.

1. Watch carefully the natural coagulation of freshly shed blood. This will be obtained by the demonstrator. Observe—*a.* The natural perfectly fluid stage. *b.* The viscid stage. *c.* The jelly stage. *d.* The appearance of the first drops of serum. *e.* The continued contraction of the fibrin, resulting in the ordinary clot and serum.
2. Whip a small quantity of freshly shed blood. Wash with water the clot so obtained. Note the quantity and observe the following general characters of fibrin.
 - a.* It appears under the microscope as a fine felt-work of granular fibrils.
 - b.* It is elastic.
 - c.* It is insoluble in water and in normal saline solution.
 - d.* It swells up and becomes transparent when treated with dilute hydrochloric acid; but it may be restored to its previous condition if the acid be neutralized.

Leave in a test-tube a little of the whipped blood for twenty-four hours, and satisfy yourself that it undergoes no further coagulation,

3. Examine the plasma of horse's blood kept, by means of cold, from coagulating. (Hdb. p. 167.)
 - a. Transfer with a pipette 2 or 3 cc. of the plasma into a small test-tube. Observe the coagulation and compare it with that of § 1. Avoid shaking. Probably the fibrin will adhere so strongly to the sides of the tube that little contraction will take place. On being freed from the glass it will contract.
 - b. Dilute 1 cc. of the plasma with 50 cc. of distilled water or normal saline solution. Carefully avoid shaking and leave it till the next day. Observe the fine delicate fibrils of fibrin which are formed.
 - c. Examine, without washing, the characters of the fibrin of *a* and *b*. They are best fitted to shew the microscopical characters; white corpuscles will be found entangled among the fibrils.
4. Examine the plasma of blood prevented from coagulating by the presence of neutral salts. (Hdb. p. 171. par. 10.)
 - a. Remove 1 or 2 cc. carefully with a pipette, avoiding blood-corpuscles as much as possible, and dilute tenfold with water. The mixture will clot very speedily if placed in the warm chamber; less speedily if left at the ordinary temperature.
 - b. Remove about 10 cc. into a small conical glass. Add gradually solid sodium chloride to excess, stirring no more than is necessary to assist the salt to dissolve. As the point of saturation is reached, a flaky precipitate makes its appearance. If the precipitate be plentiful, remove it with a spatula, put it on a small filter wetted with a satu-

rated solution of sodium chloride and wash with small quantities of the same: if the precipitate be small, decant it from the undissolved salt; filter and wash the precipitate on the filter paper with small quantities of a saturated sodium chloride solution. Dissolve the substance so obtained, the **plasmine** of Denis, in a small quantity of distilled water, and filter. Probably a portion of it will not dissolve, having already coagulated. The clear, colourless fluid filtrate will, if set on one side, clot. Avoid shaking after filtration. If a small quantity only of the fibrin factors be present, the fine threads of fibrin, as they are formed, are loosened by the shaking, and contract; thus the more easily recognized gelatinous stage is lost. *This operation is the more successful, the more rapidly it is carried on.*

5. To 1 cc. of hydrocele or other serous fluid which has been ascertained not to coagulate, or to have coagulated spontaneously, add 1 cc. of fresh blood-serum, gently mix, and put on one side.

After a while, possibly not until after twenty-four hours, the mixture will have coagulated. The coagulation will be more rapid in the warm chamber.

6. Dilute 10 or 15 cc. of fresh blood-serum with twenty times its volume of distilled water. Pass a brisk stream of carbonic acid through it for half an hour or longer. The mixture will become turbid and opaque. After standing for twelve hours a white amorphous precipitate will have settled to the bottom of the vessel. Siphon off all the clear supernatant fluid. (Fill up the vessel with water charged with carbonic acid, let it stand till the precipitate has again settled, and

again decant. This is for the purpose of still further getting rid of the serum, and may, if time presses, be omitted.)

The precipitate is for the most part **fibrinoplastin**. Add to the fluid containing the precipitate in suspension a drop or two of a 10 p.c. solution of chloride of sodium, and shake gently. The greater part of the precipitate will dissolve, fibrinoplastin being soluble in dilute solutions of sodium chloride. Filter, and let the clear filtrate stand. It will not coagulate spontaneously.

Fibrinoplastin may also be prepared from blood-serum by saturation with sodium chloride, as in § 4 *b*.

7. Add a small quantity of fibrinoplastin solution to hydrocele fluid. Coagulation will result.
8. Treat 10 cc. of hydrocele or pericardial fluid with sodium chloride to saturation, and proceed as in § 4 *b*; a precipitate, very similar in appearance to plasmin, will be obtained, but its solutions do not coagulate spontaneously. It is **fibrinogen**.

Fibrinogen may also be prepared by the carbonic acid method, as fibrinoplastin in § 6, but the salt method is preferable.

9. Add to 1 cc. of a strong solution of fibrinogen an equal volume of blood-serum, and set aside; coagulation will take place.
10. Take 2 cc. of plasma (§ 4), add to it 16 cc. of water, and determine that the mixture coagulates slowly or not at all.

Take another 2 cc. of plasma, and add to it 16 cc. of a .5 p.c. aqueous solution of prepared fibrin ferment; coagulation will quickly take place.

The student may prepare the ferment himself thus : Add alcohol in abundance to serum until no further precipitation takes place, filter, and dry the residue over a water-bath at 35° C.; place the residue in a bottle containing an excess of absolute alcohol, and leave for a month; at the end of this time decant as much alcohol as possible, evaporate the rest at a low temperature (under 40° C.); extract the residue with 200 times its volume of water, and filter. The alcohol will have coagulated the greater part of the fibrinoplastin and albumin, etc., and so rendered them insoluble in water, hence the aqueous filtrate will contain little else than fibrin ferment, the more so the longer the alcohol has been acting; the comparative absence of proteids should be tested by the reaction given in § 12.

11. General characters of serum **albumin** (Hdb. 423, §§ 7, 8, 9). Dilute serum tenfold with water. Of this dilute serum
 - a. Place 10 cc. in a test-tube with a thermometer and gradually heat in water-bath. Observe the temperature (about 70° C.) at which the fluid becomes milky, and that at which coagulation is complete.
 - b. Take another 10 cc. and add a few drops of strong nitric acid. The albumin is coagulated.
 - c. To a third 10 cc. add 1 cc. of acetic acid and then a strong solution of potassium ferrocyanide. The albumin is precipitated.
12. Tests for proteids (Hdb. p. 426, §§ 10, 11, 12). Dilute serum twenty-fold with water.

- a.* Xanthoproteic reaction. Take a little of the dilute serum, add a few drops of nitric acid, and boil. The white precipitate of albumin at first formed becomes yellow, or if the quantity of albumin present is small, dissolves, forming a yellow solution. Cool, and when cold add ammonia; the yellow is turned to orange.
- b.* To another small quantity of the serum add a few drops of Millon's re-agent¹ and boil for some minutes. The fluid and the precipitate (if any be formed) will become pink or rosy.
- c.* Add a drop of cupric sulphate solution to an excess of liquor sodæ. To the blue solution so formed add a drop of dilute serum, and warm; the fluid will become violet.

DEMONSTRATIONS.

1. Coagulation of blood over mercury without access of air.
2. Fluidity of blood in living blood-vessels.
3. Coagulation of blood within the vessels during life on foreign bodies or in injured blood-vessels.

¹ See Appendix.

LESSON IV.

CARTILAGE, BONE, AND TEETH.

A. HYALINE CARTILAGE.

1. Snip off a piece of the free edge of any of the thin cartilages projecting from the sternum or shoulder-girdle of a freshly killed young newt. Gently scrape away with a scalpel any tissue attached to it. Mount it in normal saline solution¹ and with a high power note that
 - a. The **matrix** is studded at tolerably regular intervals with **corpuscles** or **cells**.
 - b. Each corpuscle consists of a round or oval mass of **protoplasm**, in which lies a relatively large **nucleus**. Both of these are fairly clear and transparent, though usually showing a variable number of fine granules.
 - c. Most of the cells entirely fill up the cavities in which they lie.
 - d. At the extreme edge some cavities from which the cells have fallen out may generally be seen.

¹ In this and the following Lessons whenever a tissue is directed to be mounted in normal saline solution it is to be understood that if either fresh aqueous humour, or fresh blood-serum are obtainable, it is to be preferred.

- e.* Except at the edge, the cells are two or more layers deep.
- f.* The matrix is hyaline or faintly granular, and is comparatively (cf. *infra* §§ 5, 7) in small quantity.

If the newts are not quite young the cartilage will vary from the above in the quantity of matrix, the shape and arrangement of the cells, and in the cells possessing small fat globules and often two nuclei.

2. Irrigate the piece with acetic acid 1 p. c.

The following changes will be seen as the irrigation proceeds :

- a.* The nucleus becomes much more granular and distinct.
- b.* The protoplasm also becomes granular, and so more or less hides the nucleus.
- c.* The granules in the protoplasm are dissolved, which then becomes very clear and transparent.
- d.* The protoplasm shrinks from the matrix, and presents a granular-looking finely serrated border. Note the space between the cell and the matrix.

3. Immerse it in hæmatoxylin for a few minutes, watching that it is not stained too deeply; place it on a slide, and wash with spirit to remove any colouring matter simply adhering to the tissue. If the cartilage has been stained too deeply, soak up as much as possible of the spirit with blotting-paper and add a drop of acetic acid 5 p. c. until it is of a light purple or violet colour. Soak up the acetic acid, wash the tissue once more with spirit, and mount it in glycerine. Observe that the nuclei stain deeply,

the matrix stains less deeply, and the protoplasm of the cells little or not at all. Such empty cavities as happen to be present are now very distinct.

4. Place a small piece in gold chloride solution .5 p.c. for about half an hour, until it is of a light yellow colour, then *wash well with water*, and place it in a vessel containing water just acidulated with acetic acid; leave it exposed to the light. In 24 to 48 hours, when of a red-purple colour, mount it in glycerine.

Observe the protoplasm well coloured, and hardly at all shrunken, the nuclei deeply coloured with a sharp outline, the matrix coloured very slightly.

5. Cut thin sections of costal cartilage fresh or preserved in Müller's fluid, imbedding if necessary, and observe that
 - a. The protoplasm of the cells frequently contains large granules and fat globules, from having undergone degeneration. Distinguish between a large fat globule (very highly refractive) and a nucleus.
 - b. The cells are arranged in groups; each cell in a group is called a daughter-cell, all the daughter-cells in a group having arisen from the division of a previously existing cell called a mother-cell. Make out the partitions dividing the mother-cell. This can be best done in stained specimens.
 - c. The matrix in places may be fibrillated or laminated. Add acetic acid; it will have no effect on this fibrillation, which thus differs from that of connective tissue (Lesson v. A. 2, b).
 - d. In places the matrix may be opaque with calcareous deposit, removable by dilute hydrochloric acid.

6. Place a section of fresh costal cartilage in osmic acid 1 p.c. for an hour, wash with water, and mount in dilute glycerine. Observe the fat globules have stained a deep brown; the protoplasm, nuclei, and matrix are but slightly stained.
7. Take a piece of cartilage from the head of a cuttlefish preserved in picric acid or in alcohol. Cut sections, and stain with hæmatoxylin. Observe
 - a. The groups of cartilage cells.
 - b. The marked **processes** proceeding from the cells of one group, running towards and anastomosing with the processes from the cells of other groups.

If the staining of the cells and matrix is too much alike, add a little 1 p.c. acetic acid; this will extract a great deal of the colour from the matrix.

8. Take a small piece of the ear of a freshly killed mouse, remove the skin and scrape away the tissue surrounding the ear-cartilage. Mount the cartilage in normal saline solution.

Observe that the cavities of the cells, generally polygonal in form, are separated by very narrow partitions of matrix. From many of the cavities the corpuscles have disappeared altogether, leaving simply a honeycombed matrix. This form of cartilage is frequently called "parenchymatous."

B. BONE.

1. Examine with a low objective transverse sections of compact bone prepared by grinding down thin slices and mounting them in Canada balsam. Observe

3. Examine similar longitudinal sections, first with a low and then with a high objective, and compare them with the above. Observe
 - a. The Haversian canals, cut longitudinally or obliquely.
 - b. Their divisions or junctions.
 - c. Their openings on to the surface of the bone and into the medullary cavity.
 - d. The lacunæ, generally cut lengthways and therefore narrow, and mostly disposed parallel to the Haversian canals. In many spots they may be seen scattered irregularly.

4. Prepare transverse and longitudinal sections of bone which has been treated with chromic acid¹. Stain with hæmatoxylin and mount in glycerine. Observe
 - a. The Haversian systems, with the Haversian canals as before.
 - b. The remains of capillaries and blood-vessels in the Haversian canals and spaces.
 - c. The cell, consisting of protoplasm and nucleus present in each lacuna.
 - d. The canaliculi, appearing as fine, hardly visible streaks, or when seen in section as dots.

¹ The bone should be divided into small pieces and placed in a large quantity of chromic acid .05 p.c. It is well to shake gently occasionally, to bring fresh acid in contact with the bone. The fluid should be renewed in 24 hours, and again every two or three days. After a week a solution of .5 p.c. may be used; the decalcification will take place in about 15 days, but a preliminary section should be made from one end with a blunt razor or scalpel to see that all salts are extracted. A saturated solution of picric acid may also be used. In either case the sections should be well washed with water before staining.

C. TEETH.

1. Examine with a low objective longitudinal sections of teeth prepared in the same manner as bone in B. Observe the **dentine** surrounding the pulp cavity, the **cement** or **crusta petrosa** covering the dentine of the fangs, and the **enamel** covering the dentine of the crown. Note the general arrangement of the dentinal tubules.

2. Examine with a higher objective the same section, and study in detail.

a. The **Dentine**.

a. In the matrix, apparently homogeneous, are numerous dentinal tubules which run in a wavy course from the pulp-cavity outwards. These, dividing as they go, and giving off many anastomosing lateral branches, finally end either in loops or in small irregular cavities, the so-called interglobular spaces, on the surface of the dentine.

b. In some places the dentinal tubules are cut transversely. Here the central dark spot indicates the space formerly occupied by the dentinal fibre, the ring round this is the dentinal sheath.

β. The **Cement** or **Crusta Petrosa**.

a. This differs little from bone, but Haversian canals are generally absent.

b. The canaliculi of the lacunæ, next to the interglobular spaces, open into these, thus bringing the dentinal fibres into connection with the bone-corpuscles.

- c. Where the cement is massive, wavy 'contour' lines may be seen, indicating the successive deposits.

γ. The **Enamel**.

The striated enamel fibres or prisms are arranged in sets, perpendicular to the surface of the dentine. In mounted specimens the indications of the separate fibres are generally not well marked, but are visible at places. The line of junction of the enamel and dentine is generally very conspicuous, in consequence of a change of level in the specimen, the dentine having been ground thinner than the harder enamel. The enamel is frequently split or cracked.

3. Examine prepared transverse sections of Teeth, taken at different heights, and compare with the above.

LESSON V.

CONNECTIVE TISSUE.

A. CONNECTIVE-TISSUE FIBRES.

1. Elastic Fibres.

- a.* Tease out in water a morsel of ligamentum nuchæ. It is almost entirely made up of rather large branching, and anastomosing fibres with bold outlines, curling at their ends.
- b.* Irrigate with acetic acid; the fibres are unaffected.

2. Proper Fibrillæ of Connective Tissue.

- a.* Tease out in normal salt solution (Hdb. p. 32) a *small* piece of fresh tendon, e.g. from one of the digits of a frog. It is made up of bundles of wavy, delicate fibrillæ, whose outline is hardly visible.
- b.* Irrigate with acetic acid 5 p.c. The fibrillæ disappear, and the whole tissue swells up into a transparent gelatinous mass, in which one can hardly distinguish anything besides a few elastic fibres similar in general characters to those of A. 1, but much finer.

- c. Snip off a piece of the thin connective tissue lying between the muscles of the thigh of a frog. Spread it out carefully on a glass slide without adding any fluid, unless necessary to keep it from becoming dry; put on a cover slip, and irrigate with normal salt solution. It is composed of similar wavy bundles of fibrillæ arranged as a meshwork; these are similarly affected by acetic acid. The elastic fibres are more abundant, and very much curled along their course.

B. CONNECTIVE-TISSUE CORPUSCLES.

1. Take a piece of the thin expansion of a tadpole's tail preserved in chromic acid. Gently break a piece up in glycerine. Where the hexagonal cells of the epidermis have broken away, the homogeneous matrix may be seen, imbedded in which are many blood-vessels and a number of stellate cells.

The larger dark stellate cells are pigment-cells, the smaller stellate cells are **fixed connective-tissue corpuscles**, each of which consists of a nucleus and a branched protoplasmic body. The processes divide much, but irregularly, and communicate with the processes of other cells.

2. Take a frog, of which the brain and spinal cord have been destroyed¹, squeeze the side of the head gently to make the eye bulge out; then with a sharp scalpel with one slice cut off the cornea. If any blood has accidentally got on it, put it on a slide with a drop of normal saline solution and brush it with a camel's-hair brush but gently, since the success of the preparation depends greatly on the cornea being

¹ See Appendix.

placed in gold chloride without having been dragged or pulled about. Put it in gold chloride .5 p.c. solution till it is of a pale yellow colour, wash well, transfer to water just acidulated with acetic acid, and expose to light. When the cornea has become of a weak blue-violet colour, put it on a slide with glycerine, and brush or scrape both surfaces to remove the epithelium, then mount in glycerine and look at it first with a low, and then with a high objective. Where the hexagonal surface epithelium has been removed, there will be seen stained connective-tissue corpuscles, with numerous fine processes branching and anastomosing with each other.

This preparation should be preserved to shew the nerves of the cornea (cf. Less. xxv.).

3. Break off the tip of the tail of a young rat just killed, and pull out from the stump a bundle of fine tendons. Gently stretch this over a glass slide from edge to edge, and hold it in this position till the edges are dry, putting a drop of normal saline solution in the middle only; the fibres are thus kept extended. Cover with a cover-slip. On examination the bundles of wavy fibrillæ will be seen, but no corpuscles.

Slowly irrigate with acetic acid 1 p.c., *watching the bundles the while* under a high objective. Between the bundles of fibres, and sometimes apparently over them, will be seen rows of cells. Note in each the round or oval nucleus, the rectangular outline of the cell, and the granular protoplasm. Indications of lateral processes may be seen by careful focussing. After the acetic acid has been added for some little time the protoplasm of the cells becomes very indis-

tinct, and between the swollen bundles scarcely anything is seen but rows of irregularly shaped nuclei. (Cf. Action of acetic acid on cartilage cells, Lesson IV, § 2.)

4. Imbed the tendo Achillis of a frog that has been placed in absolute alcohol for 24 hours, and make transverse sections. Observe

The separate tendon bundles.

In each bundle the tendon cells (cp. § 3), elongated in sections, thus shewing them to be flat, and from each cell a number of processes joining with those of neighbouring cells.

5. Dissect back a piece of skin of a recently killed young and fasting rat or other animal, and into the subcutaneous tissue attached to this inject a .5 solution of gold chloride with a Pravatz syringe, until the fluid begins to exude. Let this stay for a few minutes, and before the swelling produced subsides snip off with a sharp pair of scissors one or two pieces as thin as possible, and place in a watch-glass containing two parts of water and one part of formic acid 1.06 sp. gr. When the pieces are well coloured, which will probably be in two or three hours, shake them gently in a glass containing distilled water, then mount in the manner given in § 2 c., but in acid glycerine. The preparation will improve in a day or two. Observe

a. The lymphoid cells scattered about between the bundle of fibres; the fibrous bundles will be more or less swollen up by the formic acid, and so not offer sharp outlines.

b. Connective-tissue corpuscles rather larger than

the lymphoid cells, and having processes in some cases seen to be connected with the processes of other similar cells. (Cf. B. §§ 1, 2.)

- c. Larger, more rectangular cells, generally without evident processes, with oval nuclei, lying over the bundles of fibrous tissue often in rows or patches; on a side view these appear as thin long cells.

This section should be preserved for the observation of fat tissue (D. § 5).

6. Snip off a small piece of subcutaneous tissue in a newborn mammal, and spread it carefully on a glass slide *without teasing*, and mount as in A. § 2, c.

In the spaces where the fibrillæ are scanty will be seen some pale, granular, branched cells, not unlike those of B. § 1.

Irrigate with acetic acid 1 p.c. the nuclei of these connective-tissue corpuscles, each surrounded by an irregular-shaped mass of protoplasm, will come distinctly into view.

This will also serve to shew the development of fat-cells (D. § 6).

C. PIGMENT-CELLS.

Pin out on a frog-board one of the webs between the toes of the frog used in B. § 2, and observe first with a low and then with a high objective. There will be seen large corpuscles loaded with dark pigment, and possessing numerous branched processes. In some places the pigmented cells will appear as round dots, the processes in this case having been retracted. Every intermediate stage between these two states may be observed by watching from time to time.

D. FAT-CELLS.

1. Cut out a small piece of the omentum or subcutaneous tissue of a mammal, from a part as the axilla, containing comparatively little fat. Spread it out on a slide, and cover with normal saline solution and a cover-slip. Examine with a low objective. Observe the groups of highly refractive fat-cells.
2. Examine with a high objective. Observe the individual fat-cells, their variable size, the apparent absence of a nucleus, and the fibres of connective tissue passing between and over them.
3. Place a small piece of omentum containing only a small amount of fat in osmic acid 1 p.c. for an hour; wash, and mount in dilute glycerine. Observe that the fat is stained a deep brown or black. (Cf. Less. IV, A. § 6.)
4. Take a small piece of omentum, which has been kept for some time in alcohol, and place it in hæmatoxylin until it has become well stained. Wash it with spirit, place it on a glass slide, and tease it out if it is too thick. Remove as much of the spirit as possible with blotting-paper. Cover the tissue with a mixture of carbolic acid (1 part) and turpentine (4 parts), and let it remain until it is completely transparent, changing the fluid and gently warming if necessary. Remove the excess of turpentine and cover the tissue with a drop of Canada balsam and put on a cover-slip.

Observe the groups of cells from which the fat has been thus removed. Note the shrunken outlines of the cells, the marked membrane, and the presence in each cell of a deeply stained nucleus. A small

amount of protoplasm, also stained, may be seen as in § 5.

5. In the gold chloride preparation of sub-cutaneous tissue made above (B. § 5), observe

The network of capillaries in the small collection of fat-cells.

The large, flat, connective-tissue corpuscles (B. § 5. *c*) in greater quantities near the groups. When the fat-cell group is spindle-shaped, these may often be seen proceeding in rows from the ends.

In some fat-cells a nucleus and a small amount of protoplasm surrounding the fat may be seen. Do not mistake a deposit of crystals in the fat for a nucleus.

6. Snip off a small portion of the gelatinous material from the orbit of the rabbit (Hdb. p. 44, Figs. 47, 48), and examine the transitional forms between connective-tissue corpuscles and fat-cells, containing in their protoplasm a variable number of fat globules.

LESSON VI.

MODIFICATION OF CONNECTIVE TISSUE AND HYALINE CARTILAGE—OSSIFICATION.

A. TRANSITION TO FIBRO-CARTILAGE.

1. From the prepared¹ intervertebral cartilage, cut sections at right angles to the vertebral face. The cutting of the section will be rendered easier if a small piece of the cartilage be previously "imbedded" in the following manner. At one end of a small oblong block of paraffin *B* scoop out a small hole; and place the piece of cartilage in the hole with that surface uppermost from which the sections are to be taken. Pour over it slowly and carefully a little of the paraffin mixture heated so as to be just melted; keeping, if necessary, the tissue in its proper position by means of a heated needle; when the whole is thoroughly solid pare down the paraffin to the surface of the cartilage, at the same time bevelling the edges. In cutting the sections, cover the tissue and the blade of the razor with spirit (for convenience from a wash-

¹ Cut off from one face of a vertebra of a rabbit a thin slice about 1 mm. thick, leaving the intervertebral cartilage in connection with it; divide the more or less circular piece so obtained into four parts, and treat with chromic or picric acid to dissolve the salts (see p. 42).

bottle) and float the sections by means of a gentle stream of spirit into a watch-glass. With the platinum "lifter" transfer them to hæmatoxylin and treat as in § 3. Observe

- a.* The softened bone passing into
- b.* The thin layer of hyaline cartilage; outside this
- c.* The arrangement of the cartilage cells in rows, and the concomittent appearance of fibres in the matrix, this gradually but rapidly merging into
- d.* Fibro-cartilage consisting of bundles of white fibrous tissue with large nucleated cells not distinguishable from cartilage cells, between the fibrous bands; these cells moreover have a thin hyaline capsule
- e.* Towards the outer part of the cartilage, the capsules and cells become smaller and more elongated, the capsules disappear, and so the fibro-cartilage merges into
- f.* Loose connective tissue.

The fibro-cartilage does not form one continuous band connecting the vertebra, but passes in parallel bundles, between and at right angles to which are tendinous bundles which thus will be seen in cross sections; the cartilage cells may in some bundles also be absent.

2. Prepare a section through the junction of the round ligament and head of the femur in a young animal parallel to the direction of the fibres. If the tissue has been treated with picric acid, stain the section in picrocarmine; if in chromic acid, with hæmatoxylin. Observe the transition of the flat rectangular branched

cells of the tendon to oval fuller cells with round nuclei as the tendon approaches the cartilage. Note the gradual disappearance of distinct fibres and their replacement by a hyaline matrix, the cells at the same time becoming scattered. Thus the tendon passes into fibro-cartilage, and fibro-cartilage into hyaline-cartilage.

B. TRANSITION TO ELASTIC CARTILAGE.

Dissect out the arytenoid cartilage of a sheep, preserved in alcohol, and cut out a small piece of the tissue immediately above the hyaline cartilage, and together with a little of the hyaline cartilage itself. Imbed, and cut sections, including the hyaline cartilage and the tissue above it. Stain with picrocarmine. Observe

- a.* That at the upper surface of the hyaline cartilage, the matrix becomes granular, and the granules arranged in rows, which then often have less the appearance of rows of granules than of granular fibres; these may be traced into ordinary fine elastic fibres, which increasing in quantity, form
- b.* The elastic cartilage in which the cells stained red with carmine are similar to those of hyaline cartilage, they have a thin clear outline around them, the capsule, and these are surrounded by a meshwork of elastic fibres stained yellow with picric acid lying in a varying quantity of matrix. This meshwork may have not so much the appearance of distinct elastic fibres, as of a system of thick bars, recalling in general feature parenchymatous cartilage.
- c.* Above (*b*) ordinary loose connective tissue, note the transition of the elastic cartilage into this by

the elongation of the cells and the breaking up of the elastic fibre into loose bundles, and the appearance in these of white fibrous tissue staining red.

OSSIFICATION IN CARTILAGE.

Cut a longitudinal section through the head of the femur of a newly-born rabbit, cat, etc. The femur should have been divided longitudinally into four parts, and treated with chromic acid to dissolve the salts.

Observe

- a.* The normal hyaline cartilage.
- b.* The cartilage cells arranged in rows. Note that many of the cells in section are triangular, the broad side of one lying above the angle of the other; this indicates an origin of two from one cell by oblique division.
- c.* A layer of cells much larger than the previous ones, with clear contents and a distinct nucleus.
- d.* The large irregular cavities below this layer surrounded by bone matrix, and more or less filled with osteoblasts, cells very similar in appearance to white blood corpuscles, but larger. In the centre of some of the cavities may also be seen a blood-vessel with surrounding connective tissue.

DEMONSTRATIONS.

The method of preparation and the reactions of Mucin, Chondrin, and Glutin.

Specimens of Membranous Ossification.

LESSON VII.

STRUCTURE OF CONTRACTILE TISSUES.

1. Scrape a small area of the mucous membrane of the throat or roof of a frog's mouth, which has been treated with osmic acid 1 p. c. for twenty-four hours. Tease out the flakes so obtained in a drop of water, and examine with avoidance of pressure. Groups of **ciliated cells**, intermingled with goblet-cells will be observed. Neglect the latter; note in the former
 - a. The shape of the cell; it is more or less conical, often branching irregularly at its attached end.
 - b. The cilia on the fore surface. Seen in profile, they appear to form a row, but when a cell is obtained in such a position that it is viewed from above, the cilia, foreshortened into mere dots, are seen to be spread over the whole surface of the base.
 - c. The nucleus, the granular protoplasm, and the hyaline border just below the cilia.
2. Scrape the same membrane in a recently killed frog, and gently tease the scrapings in normal saline solution, putting a hair underneath the cover-slip to avoid pressure. Note
 - a. The movements of the cilia, watching especially those in which the action is becoming faint.

- b. The results of ciliary action: granules and blood-corpuscles are driven along. Detached cells may also be seen carried about by the action of their own cilia.
 - c. The contracted, almost globular form of the cells which have been set free.
3. Tear off the smallest possible strip of a **frog's muscle**, preserved in alcohol, and tease it out as finely as possible in dilute glycerine. Note
- a. The varying size of the elementary fibres.
 - b. The striation of the fibres: alternate dim and bright cross-bands passing through the whole thickness of the fibre.
 - c. The breaking up of the fibre into fibrillæ, the latter also striated. Try to obtain as fine fibrillæ as possible. The fibres sometimes split transversely into discs; this is usually the case when the muscle has been preserved in picric acid; the surfaces of the discs appear dotted.
4. Lay bare one of the muscles in the leg of a freshly-killed frog (preferably the sartorius), tear away its connective-tissue covering with a forceps; seize with fine forceps a few fibres at one end of the muscle, and gently pull them out to the opposite end. Lay them on a glass slide, and separate them a little in the centre, place a bristle across them and press gently: remove the bristle, add a drop of normal saline solution, and put on a cover-slip.

Where the bristle was pressed on the fibres the muscular substance will be seen in many cases to be broken across, leaving its delicate transparent sheath,

the sarcolemma, stretching across the gap; an indication of the sarcolemma as a fine line bulging out from the muscle substance may also be seen where the fibres are bent.

5. Irrigate with acetic acid .5 p.c., and observe
 - a. The fibres become cloudy and semi-opaque.
 - b. The precipitate causing this cloudiness is dissolved, and the fibres become more transparent than normal.
 - c. The nuclei of the fibres come into view scattered throughout the muscle substance; they are elongated in the direction of the fibre: lines of granules proceeding from their ends may usually be seen.

6. Remove with as little injury as possible one of the thin muscles from the leg of **Hydrophilus**¹ and mount it in normal saline solution, avoiding pressure. The fibres will for a brief period be seen in a normal condition. In many, the alternate dim and bright striæ will be very distinct; in others the transverse markings will be more or less obscured by an appearance of longitudinal fibrillation. Occasionally fibres are met with, having only a confused granular aspect. If the preparation has been successfully made, waves of contraction may, at times, be seen to travel along the fibres. At the contracted part, the fibre is, for the time being, thicker, and the striæ set closer together.

¹ If not obtainable, take *Dytiscus marginalis*, the large common water-beetle.

Observe in the fibres with distinct transverse striation, that,

The dim band has a faint longitudinal striation, as if made up of small rods.

The bright band shews a dotted line running across its centre, thus dividing it into two parts. If the preparation be good, and a high magnifying power be used, this may be seen to consist of two rows of granules.

The usually round nuclei, imbedded in a granular mass of protoplasm, the whole forms a band or rod running a variable distance in the substance of the fibre (cf. § 5).

7. Imbed a small piece of **mammalian muscle**, hardened in chromic acid .5 p.c., and cut transverse sections, stain with hæmatoxylin, and mount in acid glycerine. Observe

The division of the fibres into bundles, by connective tissue.

The cut ends of the fibres finely dotted, having a small amount of connective tissue between them.

The nuclei, lying not in the muscle substance but beneath the sarcolemma (cf. §§ 5, 6).

In some part of the section the fibre fragments will probably be turned flat; in these the striation and tendency to break into fibrillæ may be noticed as in frog's muscle, the fibres are however much more uniform in size.

8. Tear off with fine forceps a strip of **plain muscular tissue**, from an intestine of (*e. g.*) a dog, preserved in

potassium bichromate 1 p.c. for two days, or in Müller's fluid and subsequently in alcohol; stain with hæmatoxylin and tease out in acid glycerine. Note

- a. The isolated fibre-cells. These are long, and, when not broken off in the preparation, fusiform masses of hyaline or faintly granular protoplasm. They appear very much thinner when seen in one direction than in another; that is to say, they are much flattened. In the middle of each fibre an elongated nucleus will be seen stained deeply with hæmatoxylin. In the neighbourhood of the nucleus, especially at its ends, granules are more abundant in the protoplasm.
 - b. The arrangement of the fibre-cells in bands and sheets: the fibres may frequently be seen projecting like a palisade from the torn end of a band.
9. Examine a strip of plain muscle from a perfectly fresh intestine of not too small a mammal, having teased it out *very gently* in normal saline solution. The individual fibre-cells are seen with great difficulty, and when visible are often contracted.
 10. Add acetic acid. Note in each the nucleus which now appears rod-shaped, and contains one or sometimes two dark spots, the nucleoli.
 11. Take a small piece of the bladder of a dog preserved in Müller's fluid; tear off the connective-tissue coat and the lining mucous membrane; imbed and cut transverse sections; stain with carmine, and mount in glycerine. Observe the arrangement of the fibres in bundles; the cross section of the fibres, many having a large conspicuous central spot, the nucleus.

12. Tease out thoroughly a small portion of **cardiac muscle** preserved in potassium bichromate¹. Note that
- a. The striation is generally obscure.
 - b. No sarcolemma is present.
 - c. The fibres may frequently be seen branching and anastomosing, giving often the appearance of a meshwork.
 - d. Nuclei are present disposed with considerable regularity. Around each nucleus is an area of contractile substance (muscle-cell) marked out by obscure partitions from neighbouring areas.

The nuclei will become more evident if the tissue be stained with hæmatoxylin.

¹ Good preparations can be obtained by the following method (Ranvier). Thin sections in the direction of the fibres are cut from a fresh heart, placed in chromic acid .02 p.c. for one day, then washed and placed in picrocarmine for one day, washed and mounted in acid glycerine.

DEMONSTRATIONS.

The structure of a living muscular fibre of *Trombidium* as seen under a high power.

The appearances of muscular fibre under polarised light.

LESSON VIII.

PROPERTIES OF CONTRACTILE TISSUE.

1. **Constant Current.**

Place on its belly a frog, the brain and spinal cord of which have been destroyed, and make a longitudinal incision through the skin of the back of the thigh. Separate the large semi-membranosus muscle which lies on the inside of thigh, from the smaller biceps muscle which lies more to the outside. (Compare *Elementary Biology*, XIII. E. 4, p. 221.) The sciatic nerve with the femoral vessels will come into view. Taking as much care as possible not to injure the nerve, isolate it by tearing away carefully the surrounding connective tissue.

Place under the nerve the shielded electrodes (Hdb. fig. 271), so that the nerve, and the nerve only, touches the platinum wires.

Connect the wires of the electrodes with a Du Bois Reymond's Key (Hdb. fig. 300), and this again with a battery of two Daniell's¹ cells. The key short-circuits the battery. Hence when the key is opened, the current is thrown into the nerve.

¹ In the following experiments, for convenience in description, Daniell's cells and Du Bois Reymond's key are recommended to be used. Any other battery of corresponding strength, or any other form of key, will serve.

The leg being perfectly at rest, and the key closed, open the key, and after a few seconds close it again. A movement in the leg caused by contractions in the muscles to which the nerve is distributed, will be seen when the key is either opened or shut, or on both occasions. Save in exceptional cases, *there is no movement during the passage of the current through the nerve, but only when the current is thrown into or shut off from it* (the current being supposed to be tolerably constant). Do not repeat this experiment more than once or twice on the same nerve, lest it be too much exhausted for the succeeding observations.

2. **Single Induction Shocks.**

Now connect the wires of the electrodes with the binding screws of the secondary spiral of a Du Bois Reymond's induction machine (Hdb. p. 351), and one of the top screws of the same machine with one pole of a Daniell's cell, connecting the other top screw with a Du Bois Reymond's key, from which connect a wire to the remaining pole of the cell, so that when the key is put down, the current passes into the primary coil, and induces a momentary current in the secondary coil, and in the electrodes therewith connected. When the key is opened, the circuit is broken, the current disappears from the primary coil, and in so doing induces a momentary current in the secondary coil and the electrodes.

Place the marker at the fore part of the secondary coil at the mark 10 on the scale, and, the frog's leg being at rest, shut and open the key. At each shutting and opening of the key, i.e. at each momentary induced current, a single sharp movement of

the leg will take place. The 'single induction shock' causes a *single contraction* or *spasm* of the muscles of the leg.

Be careful to replace the nerve on the electrodes (without pinching it) if it slips off during the movements.

If good contractions are not obtained with the secondary coil at 10, push it up gradually over the primary coil, one division at a time.

3. Shut and open the key as rapidly as you can, for a few seconds. The contraction of the muscle taking longer time to develop than the induced current, each contraction will catch up its predecessor, and the leg will remain rigidly contracted, or nearly so, as long as the breaking and making of the primary current is kept up. In other words, *tetanus* is produced. This is however more easily brought about as follows.

4. **Interrupted Current.**

Remove the wires from the screws at the top of the primary coil to those at the base, thus putting into action the magnetic interruptor attached to the machine (Hdb. p. 351), using, however, the key as before. Remove the electrodes from the nerve while arranging the interruptor. The machine should work in such a way that immediately the key is put down the hammer at once is thrown into oscillations (as indicated by its noise). The current is made and broken at each oscillation. Having replaced the nerve on the electrodes, put down the key. Immediately that the sound of the hammer is heard, the leg is thrust out straight by the tetanic contractions of the muscle, and remains so as long as

the current continues to be thus made and broken. Open the key, at once the limb becomes flaccid and quiet. The 'interrupted current' should not be applied for more than five seconds.

5. **Chemical Stimulation.**

Dissect out the sciatic nerve up to the spinal column, so as to have as long a piece as possible. Let the extreme end of the nerve dip into a saturated solution of sodium chloride; watch the leg.

In a variable time twitchings of the toes will be seen, and after a while these will increase in vigour and extent over the limb until the latter becomes almost as rigid as in § 4.

6. **Mechanical Stimulation.**

Cut off the part of the nerve which has been dipping in the salt solution; the chemical stimulus being thus removed, the leg will become flaccid again.

Pinch the remaining nerve sharply with a pair of forceps several times. At each pinch the muscles of the leg will contract. The pinching kills or injures the part of the nerve pinched; hence it is necessary to begin at the cut end, and work down towards the muscle.

The gastrocnemius muscle of this leg may be used for § 11, *b*.

7. **Muscle Curve.**

From the other leg of the same frog get ready a muscle-nerve preparation. (Hdb. p. 343.)

Place the preparation in the moist chamber (Hdb. pp. 344 and 348) with the nerve on a pair of electrodes. Attach the tendon to the lever, load with 15 or 20 grammes, and bring the lever to mark on the revolving cylinder.

Connect the electrodes with the induction machine arranged for single induction shocks as in § 2.

Take tracings of single contractions or simple spasms of the muscle caused by simple induction shocks (coil at 10 to begin with for instance), using the swiftest speed of the cylinder. Observe the rapid but gradual rise to a maximum, passing almost immediately into a similar but less rapid fall, the later stages of the fall being distinctly more gradual than the early ones.

Note that the contractions caused by the opening or 'breaking' shock are, as a rule, greater than those caused by the closing or 'making' shock.

8. **Tetanus.**

Now arrange the induction machine for an interrupted current (§ 4), the secondary coil being at 15 or 20 to begin with.

Take a tracing of a tetanic contraction of a muscle, stimulating for not more than three or four seconds.

Observe the rise to a maximum at first rapid but afterwards more and more slow, the maintenance of the maximum during the application of the current, and the fall, at first rapid but afterwards more slow, after the removal of the current.

Watch during the tetanus the muscle itself as well as the curve.

9. Load the muscle with 50 grammes, allowing the lever to write on the stationary cylinder. Note the elasticity of the muscle. The weight when applied stretches the muscle to a certain extent, but when raised so as not to drag on the muscle, the latter returns, at once to almost, and eventually to quite, its former length. Stimulate with an interrupted current (coil say at

20). Note the amount of contraction. Repeat this with 100, and then with 200 grammes, using in each case the same strength of current for the same time, moving the cylinder with the hand so as to expose a fresh black surface for each observation.

Observe that with medium weights the work done (the product of the weight into the height) is greater than with very light or very heavy weights.

Observe also that the muscle gradually becomes exhausted, i. e. the contractions caused by the same stimulus gradually become less and less.

10. Remove the magnetic interruptor from the primary circuit, and insert the oscillating rod. (Hdb. p. 353.) Take tracings of the contractions so caused. Observe the gradual fusing of a series of single contraction-curves into the curve of tetanus.

11. Reaction of Muscle.

- a. Remove the muscle from the moist chamber, place it on a *clean* glass slide, and apply the electrodes, connected with the induction machine arranged for an interrupted current, *directly* to the muscle.

Observe that the current applied directly to the muscle produces the same effect as when applied indirectly through the nerve.

Tetanize the muscle with currents of increasing strength until it is completely exhausted, pushing the secondary coil right up over the primary.

Cut the muscle across in half, with a *quite clean* scalpel, and press on one section a piece of faintly blue, on the other a piece of neutral

litmus paper. Both will be turned red where they come in contact with the muscle.

- b. Dissect out the gastrocnemius from the leg used in §§ 1—6, and place it for five minutes in normal saline solution heated to 50° C.

Observe that it has become contracted and opaque, i.e. *rigor mortis* has set in.

Cut the muscle across, and test with litmus paper as in *a*. The muscle will be distinctly acid, even more so than the tetanized muscle in *a*.

- c. Take a fresh living gastrocnemius from a frog just killed, cut it across as in *a* and *b*, and test the sections with neutral litmus paper. The muscle will be found neutral or faintly alkaline.

12. Myosin.

Take some muscle which has been minced and washed until all the substances soluble in water have been removed (Hdb. p. 452):

Rub up a small portion with an equal bulk of a 10 p. c. solution of sodium chloride and let it stand for twenty-four hours. Press the glairy mass through a piece of linen, and then filter through a coarse filter. Let the filtrate drop into a tall jar containing some 500 cc. of distilled water. As each drop falls into the water it gives rise to a white flocculent precipitate. This is **myosin**, which, after standing for some hours, will settle at the bottom of the vessel.

Pour off the clear fluid, filtering if necessary, and determine that the myosin is soluble

- a. In a 10 p. c. sodium chloride solution, the solution coagulating on being boiled,

- b.* In dilute acids and dilute alkalis, the solutions not coagulating on being boiled.

13. **Syntonin.**

Treat another portion of the same washed muscle with ten times its bulk of hydrochloric acid 1 p. c., and place in the warm chamber, frequently shaking. After three or four hours much of the muscle will have disappeared.

Filter off the clear fluid, and carefully neutralize the filtrate with a weak solution of sodium carbonate; a copious bulky precipitate of **syntonin** takes place. Separate the precipitate by filtration, avoiding exposure to air as much as possible, and determine that

- a.* It is soluble in dilute acids and alkalis.
b. The acid and alkaline solutions are not coagulated by heat.
c. The syntonin is precipitated from these solutions on careful neutralisation.
d. The precipitated syntonin *suspended* in water and boiled becomes coagulated, and is no longer soluble in dilute acids and alkalis.

DEMONSTRATIONS.

The natural electric currents of muscle.

The negative variation of the current attending a contraction of the muscle.

The rheoscopic frog.

Measurement of the latent period of contraction.

LESSON IX.

STRUCTURE OF NERVOUS TISSUES.

A. SPINAL NERVES.

1. Cut off about one third of an inch of a small perfectly fresh nerve (e.g. a branch of the sciatic of a frog), and place it on a glass slide *without any fluid*. Fixing one end by pressing on it with the blunt end of a scalpel, and pass a needle through the other end in the direction of the nerve fibres, and so spread it out into the shape of a fan ; add a drop of normal saline solution, and cover with a cover-slip. Observe
 - a. The **nerve-fibres** of variable size.
 - b. In each the double contour, due to the **medullary sheath** or white substance of Schwann.
 - c. The **primitive sheath** ; this is seen with difficulty except at points where the medullary sheath is wanting.
 - d. The **connective tissue** (perineurium) running amongst and around the nerve-fibres.
 - e. Drops and fragments of the medullary sheath, extending from the cut ends of the fibres and shewing a double contour.

2. Cut off a similar piece of nerve and treat it in the same way, but instead of adding a normal solution, pour over the nerve a drop of chloroform, and immediately cover with a cover-slip. Add chloroform as evaporation goes on.

In the middle of the nerve-fibre the pale granular **axis cylinder** will be seen running through the swollen and partially dissolved medullary sheath.

3. Take another piece of fresh nerve, and place it in a small quantity of osmic acid .1 p.c. for ten minutes, covering it up to prevent evaporation.

Remove it to a slide, and separate a small bundle of fibres, putting the rest back in osmic acid; tease out the small bundle thoroughly, add a drop of water, and put on a cover-slip. If it is desired to preserve the specimen the nerve should be washed with water before teasing and mounted in dilute glycerine.

Select a nerve that is isolated for a considerable part of its length, and observe

- a. The medullary sheath, stained black with osmic acid.
- b. The **nodes of Ranvier**. These will be seen as short but distinct breaks in the medullary sheath; with Zeiss obj. D. oc. 2 they occur at intervals of about twice the diameter of the field, varying considerably, however, in different nerves. The axis cylinder may be seen continuing across the nodes.
- c. The **nuclei** of the primitive sheath; one to each internodal nerve portion situated about half way between two nodes, and appearing as a small

transparent elongated body projecting usually into the medulla.

The nuclei of the primitive sheath may be stained by placing a piece of the nerve, after treatment with osmic acid, in Frey's carmine for two days. In such a preparation, also, the cells of the fine connective-tissue around the nerve fibres will be well seen.

4. Stain with hæmatoxylin, or carmine, a short piece of rather thick nerve (e.g. the sciatic of a mammal), previously treated with ammonium bichromate and alcohol. Imbed, and cut as thin transverse sections as possible; treat these with carbolic acid &c., and mount in Canada balsam. Observe
 - a. The cut ends of the nerve-fibres varying in diameter, and in each
 - b. The section of the stained axis cylinder surrounded by
 - c. A transparent ring indicating the former position of the medullary sheath, which has been dissolved out in the process of mounting.
 - d. The primitive sheath as a limiting circle.
 - e. The arrangement of the fibres in bundles. The perineurium between the fibres, and between the bundles of fibres.

5. Open the abdomen of a recently killed frog, stretch the mesentery smoothly over a small ring of cork, with a central hole of about one-third of an inch in diameter, and pin it in that position. Cut out from the body the piece so fixed to the cork, cutting away also the intestine immediately connected with it. Treat the

piece still attached to the cork with gold chloride .5 p. c. (Lesson v. B. § 2), taking care that the whole of the tissue is kept immersed in the fluid.

Cut out a piece of the mesentery so stained, and mount it in glycerine. Trace out the nerves (coloured with the gold) towards the periphery. Observe

- a. The division and branching of the nerves.
- b. The division of the nerve-fibres.
- c. The gradual loss of the medullary sheath.
- d. The continuation of the fine nerve-fibres, with the nuclei of their primitive sheath very distinct, into delicate threads, without a primitive sheath and with frequent varicosities.

B. SYMPATHETIC NERVES.

Cut out from the spleen of a large animal (e. g. ox) a small piece of one of the large sympathetic nerves running alongside the blood-vessels. Remove the loose connective-tissue sheath, and tease out the nerve carefully in normal saline solution. Note

- a. The scanty medullated nerve-fibres.
- b. The **non-medullated** nerve-fibres or fibres of Remak, constituting the bulk of the nerves: they are pale and granular, and having no medulla shew distinctly the oval nuclei of the primitive sheath.

C. SPINAL GANGLIA.

1. Take the head of a frog preserved in potassium bichromate. Remove the lower jaw and divide the skull in two down the middle line. Cut away the mucous membrane covering the roof of the mouth,

the inner and lower part of the eye will be laid bare; just behind the eye is a depression; from this two or three small filaments, the branches of the fifth nerve, will be seen issuing. Cut through the bone from the middle line to the place where the nerves issue, turn the piece of bone forward, and gently scrape out the brain.

A filament (the fifth nerve) will then be seen going towards the branches spoken of above. Between the two is a slight enlargement, the Gasserian ganglion, surrounded by tough connective tissue and by connective tissue attached to the bone. Cut away this tissue and excise the ganglion.

Tease a portion of it, in a *very small* quantity of water or of glycerine, into small fragments. Numerous **ganglionic corpuscles**, freed from their sheath, will be seen floating about, also others still surrounded by their sheaths and in position. Observe in the corpuscle

- a. The granular protoplasmic **cell-substance** often containing pigment.
 - b. The large transparent **nucleus** with its conspicuous **nucleolus**.
 - c. The **sheath**, of connective tissue with numerous small nuclei.
 - d. Processes of the cell-substance. These will, probably, in most instances, have been torn away in teasing.
2. Cut thin longitudinal sections of a spinal ganglion (mammalian) previously hardened in chromic acid and stained with hæmatoxylin. Mount in glycerine or in Canada balsam; and observe.

- a. The arrangement of the ganglionic corpuscles.
- b. The arrangement of the nerve-fibres.
- c. The connective tissue supporting both fibres and corpuscles.

The nuclei, cell-substance, and sheaths of the corpuscles may also be very well seen.

D. SYMPATHETIC GANGLIA.

Lay open the abdomen of a frog, and carefully cut away the intestines. The abdominal aorta will be seen lying in the middle line, with the large spinal nerves on either side. Cut out the aorta and the nerves of both sides, *in one piece*, and place *flat* in gold chloride .5 p. c. and treat as usual. Along the aorta and its branches, and on the sympathetic branches crossing from the spinal nerves towards the aorta, are numerous sympathetic ganglia. The whole piece may be searched with a low objective until the position of the smallest and least covered ganglia is ascertained. These can then be examined (in situ or after removal from the large piece) with a higher objective. Note

The pear-shaped cells with two processes, the thicker one straight, and having the thinner one turning spirally round it. In many cases the spiral fibre divides close to the cell and has nuclear (?) enlargements.

E. SPINAL CORD.

1. Cut a thin transverse section of the spinal cord of a mammal hardened in ammonium bichromate. Stain with hæmatoxylin, treat with carbolic acid as in Lesson v. D. § 4, and mount in Canada balsam. Observe

- a.* In the white substance, the cut ends of the nerve-fibres. Compare with A, § 4.
- b.* In the grey substance (especially in the anterior cornua), the *multipolar ganglionic cells*, each possessing a nucleus with nucleolus, and protoplasmic cell-substance, prolonged into branching processes. The cell-substance often contains pigment.
- c.* The connective tissue support of the nerve-fibres and cells, and the absence of the nerve primitive sheath.

(N.B. The structure of the spinal cord will be more fully studied in a future Lesson).

2. Cut a transverse section, without imbedding, of the spinal cord of ox, preserved in potassium bichromate 1 p.c. for two or three days. Tease out the section carefully, under a low power; the cells may thus be isolated. Note
 - a.* The nucleus, nucleolus, and protoplasmic cell-substance, the latter frequently containing a deposit of pigment.
 - b.* The branched processes frequently broken short.
 - c.* The undivided nerve-process about to form an axis cylinder.
 - d.* The obscure fibrillation of this process and of the cell-protoplasm.

DEMONSTRATION.

Preparations to shew the method of ending of motor nerves in muscle.

LESSON X.

GENERAL PROPERTIES OF NERVOUS TISSUE. AUTOMATIC ACTIONS.

A. REFLEX ACTION.

1. Place on its belly a frog, which has been previously deprived of its brain¹ by the demonstrator. Observe that its hind-limbs are drawn up under the body; but that it differs from the normal frog in the following respects.
 - a.* Its head is depressed, instead of being erect.
 - b.* Its fore-limbs are spread out, or flexed, instead of being held nearly vertical; thus the angle which the body makes with the table is diminished.
 - c.* There are no respiratory movements, either of the nostrils, or of the throat.
2. Gently pull out one of the hind-limbs, until it becomes quite straight, and then let it go. It will be immediately drawn up into its old position under the body. If this experiment be made soon after the operation of removing the brain, or if much blood has

¹ In order to ensure the complete removal of the medulla oblongata, it is advisable to destroy the parts a short distance down the spinal canal.

been lost, the leg may be drawn up slowly instead of sharply.

3. Gently tickle one flank with a feather or a blunt needle; a contraction of the flank muscles of that side will be observed.
4. Pinch the same spot rather sharply with a pair of forceps; the leg of the same side will be first extended, and then drawn up and swept over the flank, the movement tending to thrust away the points of the forceps.
5. Pinch with the forceps the skin round the anus; both legs will be drawn up and thrust out again; the movement tending as before to sweep away the points of the forceps.

Leave the animal alone for five minutes and watch it carefully: if no disturbing circumstances are brought to bear on it, it will remain perfectly motionless.

6. Place the animal on its back; it will make no effort to regain its normal position, *i.e.* all sense of equilibrium has been lost.
7. Pass a hook through the lower jaw, and fasten it to the cross-bar of a stand so that the body can be raised up and down. The hind-limbs, after a few movements of flexion and extension, will remain pendant and motionless.
8. Gently pinch the tip of one of the toes of either leg; that leg will immediately be drawn up.
9. Take two glasses, fill one with dilute sulphuric acid (.1 p. c.) and the other with water: lower the frog

until the tip of one of the toes just touches the dilute sulphuric acid. In a short time the foot will be withdrawn. At once let the foot dip into the second glass containing water, in order to wash away the acid. Measure with a rapidly beating metronome, the time between the moment when the toe comes into contact with the acid and the moment when it is withdrawn. Make three such observations; and take the mean of the three.

10. Cut a small piece of blotting-paper one or two mms. square, moisten it with strong acetic acid, and place it on the flank of the animal. The leg of the same side will be speedily drawn up and swept over the flank as if to remove the piece of paper.
11. Place similar pieces of paper dipped in acetic acid on different parts of the body; different movements will be witnessed in consequence; all however tending to remove the irritating substance.
12. Wash off all the acid from the frog, and when it has become perfectly quiet, place it in a bason of water; it will sink to the bottom (unless the lungs be accidentally much distended with air), and no movements of any kind will be witnessed.

Observe that all the movements produced in the foregoing observations, although complicated, co-ordinated, and purposeful in character, are partial, and only by accident bring about locomotion. However stimulated, the animal never springs or leaps forward.

In order that the same frog may serve for observations on the lymph-hearts, B. I. § 1 should be performed here.

13. Make a small cut through the skin of the back¹, and with a fine glass tube inject one drop of a 1 p. c. solution of strychnia. In a few minutes the slightest stimulus applied to any part of the animal will produce violent tetanic spasms of the whole body. A preliminary stage of increased reflex action may also be observed.
14. Through the opening at the back of the neck into the spinal canal made in destroying the brain, introduce a pithing needle or piece of stout wire, and destroy the whole of the spinal cord. Observe that the spasms immediately cease.
15. Repeat any of the above observations (§ 2—13). No reflex actions will now be produced.

B. AUTOMATIC ACTION.

I. The Lymph-Hearts.

1. Placing the animal on its belly watch the movements of the posterior lymph-hearts. They may be seen beating on either side of the extremity of the urostyle, in a depression between that bone and the hip-joint. The contractions are generally visible through the skin, but become more evident if the skin be removed, care being taken not to injure the lymph-hearts themselves.
2. Observe that after destruction of the posterior part of the spinal cord the lymph-hearts cease to beat.

¹ Immediately underneath the skin of the back of the frog is the dorsal lymphatic sac, and any fluid placed in this rapidly makes its way into the blood.

II. The Heart.

1. Lay the frog on its back, make a median incision through the skin, and from the middle of this make transverse incisions. Raising up the end of the sternum with a pair of forceps, cut it through a little above the end so as to avoid cutting the epigastric vein. Then again lifting up the sternum cut it through longitudinally, a little removed from the middle line, with a strong pair of scissors; pin back each part of the sternum, cutting through such muscles as may be necessary; the heart will be seen in the thin membranous pericardium beating with considerable regularity and force. Pinching up the pericardium with a fine pair of forceps, open the pericardial cavity; then tilt up the apex of the ventricle; a small band of connective tissue will be observed passing from the posterior surface of the ventricle to the adjoining wall of the pericardium. Seizing this band with the forceps, divide it between the forceps and the pericardial wall. Lift up the apex of the ventricle, by means of this band, and with a sharp pair of scissors cut through the aortæ, the superior venæ cavæ, the inferior vena cava, and the surrounding tissue. Take care not to injure the sinus venosus. Place the heart in a watch-glass, moistening it when necessary with normal saline solution. The beats will either not be interrupted at all or for a very short time.

In cold weather the heart may stop on being removed from the body, but if the heart be warmed by putting the watch-glass containing it in the palm of the hand, the beats will be resumed.

2. Lifting up the apex of the ventricle by means of the same band as before, cut through the ventricle with a

sharp pair of scissors at its upper third. The lower two-thirds of the ventricle will remain motionless without any spontaneous beat; the upper third and the auricles will continue to beat with regularity.

3. By means of a longitudinal incision divide the auricles with the attached portions of ventricle into two lateral halves. Each half will continue to beat.

III. **Cilia.**

Placing the frog on its back, cut through the lower jaw, in the middle line, and carry the incision as far as the point where the broad pharynx narrows into the œsophagus, so as to expose as much as possible the upper or dorsal wall of the throat. Moisten the mucous membrane, if it is at all dry, with normal saline solution, and place on it, between the two orbits, a small thin piece of cork. The cork will be seen to be driven by ciliary action down towards the œsophagus.

DEMONSTRATIONS.

The natural electric currents of nerves.

The negative variation attending a nervous impulse.

The phenomena of electrotonus.

Electrotonus as affecting irritability.

The law of contraction.

The transmission of nervous impulses in both directions.

The phenomena of urari poisoning.

The function of the anterior and posterior roots of the spinal nerves.

The peristaltic movements of the intestines and of the ureters.

LESSON XI.

STRUCTURE AND PROPERTIES OF BLOOD- VESSELS.

A. THE LARGER ARTERIES.

1. Cut transverse and longitudinal sections of a small piece of the aorta or carotid artery of a dog (or other animal), preserved in potassium bichromate 1 p.c. and imbedded in paraffin. Note
 - a. The thin **inner coat** thrown into longitudinal folds by the contraction of
 - b. The much thicker **middle coat**, consisting of alternating layers of elastic and circularly arranged muscular tissue. The disposition and relative amount of the elastic tissue will be found to vary much in different arteries.
 - c. The **external coat** (tunica adventitia), consisting mainly of white fibrous connective tissue, with some elastic tissue not unfrequently arranged in layers, especially at the inner part of the coat. Add acetic acid to bring into view the nuclei of the muscular fibres.
2. Cut sections as above, and stain with picocarmine, being careful to wash well with water before mounting. The fibrous connective tissue will be coloured

pink, and the elastic and muscular tissue in great part yellow.

As a rule in the more peripheral arteries, the middle coat is formed of bundles of muscular fibres separated from one another by only a small amount of connective tissue with elastic fibres.

3. Take the jugular vein from a freshly-killed rabbit, cut it open longitudinally, and pin it out with porcupine quills on a thin piece of cork; steam water gently over it, and immerse it for five minutes in a .5 p. c. solution of silver nitrate, then wash well with distilled water, and expose to light, also in distilled water, until it becomes of a brownish colour: place it in absolute alcohol for 15 to 20 minutes, and mount it in Canada balsam, with the epithelium upwards.

Observe the rather jagged dark lines of the cement substance between the cells. Observe further that the cells form a continuous layer, are more or less elongated in a longitudinal direction, and are flat; indications of the nuclei of the cells may be seen, and in some places of the muscular coat, as transverse markings caused by a deposition of silver between the muscle fibres. If the artery has been left too long in the silver nitrate solution, or exposed too long to light, silver will also be deposited in the substance of the cells.

A vein is here taken as being a somewhat easier preparation for a student than an artery, the main features in either case are the same.

4. Cut open longitudinally a large artery, e.g. carotid of sheep, from a freshly killed animal, and very gently

scrape the internal surface. Tease out the material so obtained in normal saline solution.

Observe in surface and profile the cells of the lining **epithelium**, with their somewhat oblong nuclei. Probably there will also be seen fragments of **fenestrated membrane**. These will become obvious after the addition of acetic acid. The perforations in them are rendered more distinct by staining.

5. Tear off a strip from the inner coat of a medium-sized artery that has been in potassium bichromate .5 p. c. for a week; tease it out in the fluid; it will be found to consist almost entirely of **elastic laminæ**.

Observe the gradations from an almost homogeneous elastic perforated membrane to a meshwork of elastic fibres.

6. From fresh arteries, and from arteries that have been preserved in potassium bichromate, tear off strips from the middle coat, and tease out thoroughly the pieces so obtained.

Note the bands of plain **muscular tissue** mingled with the elastic laminæ.

To the fresh specimens add acetic acid; the appearance of the rod-shaped nuclei will shew where the muscular element is present.

B. THE LARGER VEINS.

1. Cut transverse sections of a fairly large vein, as in A. § 1. Relatively the muscular element will be found to be less (though varying considerably in different veins); the elastic element also to be less, and the white fibrous connective tissue more plentiful.

2. Examine the structure and position of the valves in the veins of some large animal. Attempt to make fluid pass along them in the wrong direction, in order to shew the action of the valves.

C. CAPILLARIES AND SMALL BLOOD-VESSELS.

1. Tease out in glycerine the tail of a tadpole preserved in chromic acid, and either stained with hæmatoxylin¹ or left unstained. Abundant capillaries will be seen.
Note

- a.* The outline of the channels.
- b.* The nuclei on the walls, especially at the points of bifurcation.
- c.* The branched connective-tissue corpuscles, in places partially surrounding the capillaries, and constituting the simplest form of the tunica adventitia.
- d.* The connection of some of the processes of the connective-tissue corpuscles with the capillary walls.
- e.* The blood-corpuscles within the capillaries.

2. Remove a small portion of pia mater from a perfectly fresh brain of a chloroformed animal allowed slowly to bleed to death, and spread it out carefully in normal saline solution, washing it gently with the same, and mount. Note

- a.* The capillaries, with their nuclei and protoplasm bulging into the channels.

¹ See Appendix.

- b.* The small arteries, their scanty external connective-tissue coat or adventitia, and the indications of their muscular coat composed of a single layer of fibres wrapped round the intima.
- c.* The small veins generally filled with blood-corpuscles, with their muscular coat absent or developed only to a slight degree.

3. Gently irrigate with acetic acid 1 p.c. Note

- a.* In the capillaries, the more distinct nuclei.
- b.* In the small arteries,
 - (*a*) The fusiform cells and nuclei of the adventitia, arranged longitudinally, with elastic fibres.
 - (*β*) The nuclei of the muscular coat arranged transversely. By watching the earlier stages of the action of acetic acid, the outlines of the muscle fibres, as well as of their nuclei, will be distinctly seen.
 - (*γ*) The thin inner elastic layer internal to the muscular fibres seen as wrinkled longitudinal markings.
 - (*δ*) The oval nuclei of the epithelium arranged longitudinally.
- c.* In the small veins, similar appearances to *b*, consistent with the less development of muscular fibres.

A piece of fresh pia mater may be stained with aqueous hæmatoxylin to bring out more clearly some points of the above; the following will, however, be found a better method. Place a fresh brain, with the dura mater at

least in part removed, in potassium bichromate 1 p.c. for two or three days, then wash it with water, and place it in 75 p.c. spirit for half an hour to twenty-four as convenient, cut off then a small piece of pia mater, stain with hæmatoxylin, wash with alcohol, and mount in acid glycerine. Care should be taken to drag the membrane as little as possible, and to avoid creases.

4. Examine capillaries and small vessels previously injected with silver nitrate.
Note the pattern formed by the junction lines of the epithelium.
5. Take a frog with a pale web, and introduce under the skin of the back one drop of a 1 p.c. solution of urari, and leave it under a glass jar till it makes no motion on being pinched. It is of advantage that this should not be the case in less than three-quarters of an hour, otherwise the vessels will be abnormally dilated. Lay the frog on the frog-board, and tie not too tightly a piece of soft cotton round the end of the (e.g.) 3rd and 4th digits. Stick two pins into the board a little distance from the hole; by twining the cotton round them the web may be stretched out level above the hole. Surround the web, and cover the leg and body of the frog, with moist blotting paper. Put a *small* drop of water upon the web, and cover it with a triangular piece of cover-slip, taking care that the glass does not cut into the digits and that no fluid flows over it.

Examine, first with objective 3, and then with 7. Note

- a. The course of the blood from the arteries to the veins. Sometimes a slight pulsation may be observed in the arteries.

- b.* In the small arteries and veins the rapid median stream of red corpuscles, separated from the walls of the vessels by the slower stream or inert layer, in which the red corpuscles are rare.
 - c.* The white corpuscles in the inert layer, either stationary and clinging to the walls of the vessel, or moving slowly.
 - d.* The passage of corpuscles in single file through a small capillary; the distension of the capillary by the corpuscle.
 - e.* The elasticity of the red corpuscles, observing the way in which they bend and become deformed, but regain their normal shape.
6. Remove the cover-slip, and soak up the fluid on the web; touch the middle of the web with the tip of a pointed glass rod that has been dipped in creosote, so as to leave a minute drop on the web, and replace the cover-slip. The early stages of inflammation may be seen. Observe in succession
- a.* The dilatation of the arteries, the much more distinct appearance of the capillaries, and the enlargement of the veins.
 - b.* A quickening of the current followed by a slowing.
 - c.* The crowding of white corpuscles in the capillaries and veins, with a slowing of the current.
 - d.* Stasis, or complete stopping of the current, with a gradual obliteration of the outlines of the corpuscles.

- e.* The emigration of the white corpuscles.
- f.* The diapedesis of the red corpuscles from the veins.

Notice that these effects are local, that they are of greatest intensity in the spot touched, that they extend for some distance round, but that the circulation in the rest of the web is normal.

DEMONSTRATION.

Circulation in the mylo-hyoid muscle of the frog.

LESSON XII.

STRUCTURE AND ACTION OF THE HEART.

A. HEART OF SHEEP¹.

1. Observe the attachment of the parietal pericardium to the roots of the great vessels.

Remember that the parts of the heart which are right and left in the body are called right and left after removal. The front of the heart may be recognized by a groove filled with fat, the interventricular sulcus, which runs from about the middle of the base of the ventricles to rather below the middle of the right margin of the heart. The front is also more convex than the back. Holding the heart with the front towards you, note that the right ventricle, which will be on your left hand, is much more yielding than the left ventricle, which will be on your right hand. Note also the pulmonary artery arising nearly in the middle line of the heart at the upper part of the ventricles, and immediately behind this the aorta.

2. Tie a short glass tube into the superior vena cava and connect with it a piece of india-rubber tubing. Ligature the inferior vena cava and the left vena

¹ The heart should be obtained from the butcher with the pericardium; to secure this it is advisable to purchase the 'bag,' i.e. the heart with the lungs still attached to it.

azygos which opens close beside it. Tie a glass tube about two feet in length into the pulmonary artery. Fill the india-rubber tubing with water, and squeezing it press the water onwards. The water will mount in the tube connected with the artery, and will only descend a little way on unclasping the india-rubber tubing. Pour water into the long glass tube by means of a funnel, and observe the column of water which the semilunar valves will sustain. Note the distension of the arterial walls and the bulging at the attachment of the valves. When the pressure of the column of fluid is removed the artery by its elasticity returns to its previous dimensions.

3. Repeat the above observation with the pulmonary veins and aorta.
4. Compare the united sectional areas of the superior and inferior venæ cavæ when distended, with the area of the aorta below the origin of the innominate artery.
5. Having removed the tubes, lay open the superior and inferior venæ cavæ, and bring the incisions to meet in the front of the auricle. Note
 - a. The size and form of the auricular cavity.
 - b. The auricular appendage with its muscular fretwork.
 - c. The **septum auricularum**.
 - d. The **fossa ovalis**, or expression of the foetal foramen ovale, which is early closed by the growth of the septum auricularum.

- e.* The **Eustachian valve**, a slightly projecting membranous fold, immediately beneath the entrance of the inferior vena cava, and again beneath this,
 - f.* The opening of the comparatively large **left azygos vein**.
 - g.* The auriculo-ventricular orifice.
6. Cut open longitudinally the azygos vein, and observe the **coronary vein** opening into it a very short distance from the heart.
 7. Cut away most of the auricle, and holding the ventricle in the left hand, pour water suddenly into the auriculo-ventricular orifice. The valves will float up and close. Note the star-shaped junction.
 8. Introduce a pair of scissors between two of the valves, and cut through the wall towards the apex. Having arrived at the bottom of the ventricular cavity, turn the scissors sharp round and carry an incision at an acute angle with the previous one, alongside the septum, towards, but not into, the pulmonary artery. Lifting up the flap, note
 - a.* The thickness of the ventricular wall, the projection of its inner surface or *columnæ carneæ*.
 - b.* The projection of the septum at the apex.
 - c.* The **tricuspid valves**, their form, attachment to the auriculo-ventricular ring, the **chordæ tendineæ**, and their attachment to the summits of the papillary muscles.
 9. Holding the heart vertically, pour water into the pulmonary artery; observe from below the form of the semilunar valves, and their mode of closing.

10. To observe the valves from above, insert into the pulmonary artery a short wide tube, fill it with water, and cover it with a piece of glass, excluding air-bubbles.
11. Prolong the incision of § 8 so as to lay open the pulmonary artery. Note
 - a. The form and attachment of the semilunar valves.
 - b. The small nodule of tissue in the middle of the free edge of each valve, the **corpus Arantii**.
 - c. The slight depressions in the arterial walls opposite each valve, the **sinuses of Valsalva**.
12. Lay open the left auricle in a manner similar to that employed for the right. Study as on the right side the action of the left auriculo-ventricular valve (the mitral).
13. Lay open the left ventricle in a manner similar to that employed on the right side, carrying the incision at first along the extreme left of the heart. Note the thick walls, the mitral valve, &c.
14. Lay open the aorta, and examine its semilunar valves, corpora Arantii, and the sinuses of Valsalva, which are here very distinct. Note that the **coronary arteries** open respectively into the two anterior sinuses.

B. HEART OF FROG.

1. Expose the heart of a pithed frog in the manner directed in Lesson x. B. II. With the pericardium intact, observe the pulsations of the heart, noting the alternate beats of the auricles and the ventricle; and the synchronous beats of the two auricles.

2. Lay open the pericardium and observe
 - a. The synchronous contractions of the two auricles, followed almost immediately by
 - b. The contraction of the ventricle, note that the ventricle during its contraction or systole becomes pale and conical, and that its apex is thrown forwards and upwards.
 - c. The slight contraction of the bulbus arteriosus immediately succeeding the ventricular systole.
 - d. The pause, or diastole, which follows before the auricle again beats.
 - e. The increased redness and distension of the ventricle after the auricular, and immediately preceding its own systole.
3. Divide the band attaching the ventricle to the posterior pericardial wall, and turn the apex of the ventricle over. Observe
 - a. The junction of the two superior venæ cavæ with the inferior vena cava to form the sinus venosus.
 - b. The v-shaped white line marking the junction of the sinus venosus with the right auricle.
 - c. The cardiac branches of the pneumogastric, running along each superior vena cava and then plunging into the interior of the heart.
 - d. The wave of contraction; it starts in the vena cava, spreads to the sinus venosus, almost immediately after the auricles contract, then the ventricle, and finally the bulbus arteriosus.
4. Place a light lever on the heart, and bring the end of the lever armed with a bristle, to mark on the

revolving drum. (Cf. Lesson VIII. § 7.) Take a tracing of ventricular pulsations with the drum at a moderate speed.

Note the rise and fall of the lever, indicating the change of form during contraction. The rise increases at first rapidly, then more slowly, to a maximum, and the fall is similarly at first slight, then more rapid, but finally slow again.

5. Make now a transverse cut through the skin of the frog just below the jaw, and carry the cut as far as the vertebral column; cut through *all* the muscles proceeding from the head of the humerus and from the part of the sternum left attached to it, to the hyoid bone or to the angle of the jaw.

Coming up from underneath the angle of the jaw and stretching towards the lower extremity of the hyoid bone will be seen a thin narrow band of muscle and two small white fibres, one, the glossopharyngeal nerve, running along its upper border, the other, the pneumogastric nerve, running along its lower border. Very carefully separate the pneumogastric from the surrounding tissue, and place a loose ligature around it, it will be seen to divide into two branches, the smaller branch, the laryngeal, may be cut through. It will be safer not to attempt to dissect out the pneumogastric close to the heart. (Cf. Hdb. p. 269.)

Pass an interrupted current through the pneumogastric nerve.

- a.* Observe that during and for a short time after the passage of the current, the heart remains with all parts in diastole.

- b. The period of rest (inhibition) is followed by a period (reaction) in which the beats are quicker and more forcible; and then the previous normal condition is regained.
6. Take a tracing of the above on the drum, indicating on the curve the moment at which stimulation was begun, and ended. Note that the heart does not stop *immediately* after the current is sent into the nerve.
7. Cut across the aorta, to enable the heart to empty itself of blood. Pass a silk ligature underneath the bulbus arteriosus and two underneath the inferior vena cava. Tie them *loosely*, ready to be tightened at any moment. Raise up the wall of the inferior vena cava with a fine pair of forceps, as far from the heart as possible, consistently with making an incision into the vein near the liver. Make a V-shaped incision, and introduce into this a cannula as large as can be conveniently used. Tie the tube in the vein by means of the lower of the two ligatures. Fill the tube with normal saline solution, and by blowing gently, wash all blood out of the heart. Then partly fill the tube with a .5 p.c. solution of gold chloride. Inject this in the same manner, until the solution begins to issue from the aorta. Then ligature the bulbus arteriosus. Again inject, and whilst the heart is distended tie the remaining ligature round the inferior cava just beyond the end of the cannula. Immerse the whole heart in gold chloride solution. In a few minutes it will become rigid. Lay open the auricular wall on each side. Observe the distinct cavities of the auricles. Cut out the septum, expose it to light and subsequently examine in glycerine.

The branches of the pneumogastric and the ganglia with spiral cells may be seen in it. Examine in the same way the wall of the sinus venosus along which the cardiac branches of the pneumogastric were seen to run. Numerous ganglia are scattered over these.

8. Wash the ventricle thoroughly, and when, after exposure to the light, it has become stained, transfer to spirit and then to absolute alcohol, as directed in Lesson I. § 13. When sufficiently hardened, prepare transverse sections of it. Observe the interlacement of the bundles of fibres. The walls are of a distinctly spongy character, the small central cavity being continuous with a labyrinth of small passages. In this way the blood is brought into direct contact with the muscular fibres, though no capillaries or blood-vessels are present.

Note the absence of ganglia in all parts but the extreme base.

DEMONSTRATIONS.

Experiment of Stannius.

The antagonistic effects of physostigmin (or pilocarpin) and atropin on the heart.

The action of the mammalian heart.

Pneumogastric inhibition in the mammal.

Sounds of the heart.

Endocardial pressure of frog.

LESSON XIII.

BLOOD PRESSURE.

A. MINOR ARTERIAL SCHEME¹.

1. Clamp the india-rubber tube at its proximal end close to the pump, and leave the glass tube open so that all the water flows through the latter. Work the pump with a uniform force at about 30 to 40 beats a minute. To ensure regularity, the strokes had better be timed with a metronome. The water will flow from the open mouth of the glass tube in jerks, corresponding to the beats of the pump. At each stroke as much will issue from the distal end as enters at the proximal end.
2. Introduce into the open mouth of the glass tube a fine nozzle, so as to offer considerable resistance to the outflow of fluid. Work the pump with the same force and frequency as before. The outflow will still be intermittent, though less fluid will issue from, and consequently less enter into, the tube at each stroke.
3. Clamp the proximal end of the glass tube and unclamp the elastic tube. Let the distal end of the latter be quite open. Work the pump as before. There being little resistance to the outflow, the elasticity of the tube is not called into play, and consequently the flow will be, as in the case of the glass tube, intermittent.

¹ See Appendix.

4. Working the pump as before, insert the fine nozzle into the open mouth of the tube. Considerable resistance will now be offered to the outflow of fluid, the elasticity of the walls of the tube will be called into play, and the water will issue from the end of the tube in a continuous instead of an intermittent stream. If the tube be sufficiently long and sufficiently elastic, in proportion to the force and frequency of the strokes, the flow will be absolutely continuous.

B. MAJOR ARTERIAL SCHEME¹.

The pump represents the heart; the small tubes represent the resistance of the small arteries and capillaries. The tubes on the proximal side of this resistance represent the arteries, those on the distal side the veins.

1. **The Mercurial Manometer.**

The manometer A is connected with the arterial, V with the venous tubes.

- a. Open the clamps marked *c*, *c'* and *c''*, so that as little resistance as possible intervenes between the arterial and venous tubes. Bring the manometers to mark on the revolving cylinder, placing V about an inch under A, *in the same vertical line*. Work the pump steadily, regulating the time with the metronome.

In A, the mercury rises at each stroke, and in the interval between each two strokes falls again to its previous level. (The momentum of the mercury frequently carries it below this level,

¹ See Appendix.

and the descent may be followed by one or more oscillations.)

In V, a similar rise and fall is observed, of nearly if not quite the same extent.

- b. Close the clamps *c*, *c'* and *c''*, so that the capillary resistance becomes very considerable.

In A, the mercury rises rapidly at the first stroke, and at the end of the stroke begins to fall again, but more slowly than was the case in *a*. It has not fallen far before the second stroke raises it to a higher level than before. On falling still again, it is once more raised to a yet higher level, but the increase is not so great as before. Each succeeding stroke has a similar effect. Thus at the end of a few strokes, *the mean arterial pressure* is reached, with comparatively small oscillations corresponding to the strokes of the pump.

On the strokes ceasing, the mercury *gradually* falls until the previous level is reached.

In V the mercury rises to a much less extent than was the case in *a*, a slight mean pressure much less than in A is established, marked either with no oscillations at all or such as are much less conspicuous than those of A.

Owing to the presence of the resistance, a mean pressure (arterial blood pressure) is established on the proximal (arterial) side of the resistance. This pressure is marked by oscillations synchronous with the strokes of the pump. On the distal (venous) side the mean pressure is much less and the oscillations are either slight or altogether absent.

2. Flow from Arteries and Veins.

Remove the clamps from the fine nozzles a and v . Let the clamps c , c' and c'' remain closed. Set the pump going. The flow from a on the proximal (arterial) side is in jets; that from v (venous) side is uninterrupted or nearly so.

3. Sphygmograph.

Bring the levers S_a (arterial side) and S_v (venous side) to write on the revolving drum, one under the other.

- a.* Open the clamps c , c' and c'' , and set the pump going. The two levers describe two nearly straight lines, a slight rise only being evident (and that to about the same extent in both) at each stroke.

When there is little or no resistance in the capillaries, comparatively little distension of the arterial walls is produced at each stroke of the pump.

- b.* Close the clamps c , c' and c'' .

The lever S_a now describes a well-marked curve with each stroke of the pump.

Observe the sudden rise to a maximum, the commencing fall, the break in the fall, followed by a slight rise (dicrotic wave) and the final descent.

The lever S_v describes now a straight line.

The rise in pressure at each stroke indicated by the mercurial manometer is accompanied by a distension of the proximal (arterial) part of the tubing, indicated by the rise of the lever. This is the pulse.

On the distal (venous) side of the resistance no pulse is visible.

4. Progression of the Pulse-wave.

Place two levers, one S_a , as near as possible to the pump, the other S'_a , as near as possible to the resistance. Bring the two levers to mark on the cylinder *the one exactly beneath the other*.

(The pressure exerted by the two levers must be as nearly equal as possible.)

Observe that each rise of S_a begins a little before, and is over a little before that of S'_a . In other words, the pulse of S'_a is a little later than that of S_a .

(By means of a tuning-fork this interval may be measured, and the length of tubing between the two levers being known, the rate of progression of the pulse-wave ascertained.)

5. While the pump is working, the clamps being closed and the manometers A and V tracing their curves, *gradually* diminish the resistance by opening slowly first c' and then c'' .

The arterial pressure curve will gradually fall, still marked by the pulse oscillations; the venous curve will gradually rise.

Diminution of capillary resistance lowers arterial, but increases venous pressure.

6. Close the clamps c' and c'' , and take tracings with the manometers, then gradually reduce the strength of the strokes of the pump.

Both arterial and venous pressure will diminish.

7. The clamp c being closed, the main arterial trunk of the scheme divides into two chief branches, X and Y, each with its own resistance and venous tube.

Leave the clamps c' , c'' closed, and put clamps on the tubing immediately beyond x and y .

- a.* Work the pump with great regularity, and measure the quantity of fluid which escapes during a given time (say ten seconds) from the venous tube of X, and from that of Y, by the side tubes x and y .
- b.* The clamp c'' of X remaining closed, open that c' of Y, and the pump working exactly as before, measure again the outflow during ten seconds. The outflow of Y will be increased. That of X on the other hand will be diminished, though the resistance in X is the same as before.

The flow of blood through an artery is dependent not only on the resistance offered by its own small arteries and capillaries but also on that of other arteries.

DEMONSTRATIONS.

The effects in the rabbit on the temperature of the ear, and on the calibre of its blood-vessels, following

- a.* Stimulation of the central end of the great auricular nerve.
- b.* Section of the sympathetic nerve in the neck.
- c.* Stimulation of the peripheral end of the sympathetic.

Normal kymographic tracings of the blood-pressure of a mammal obtained by the use of a mercurial manometer.

The effects on the arterial blood-pressure, as indicated by the tracing, produced by

- a.* Inhibition of the heart through stimulation of the peripheral end of the vagus.
- b.* Dilatation of the small blood-vessels through stimulation of the central end of the depressor nerve.

Methods of measuring the velocity of the blood-current in large vessels.

Comparison of venous and arterial pressure.

Use of the sphygmograph.

Use of the cardiograph.

LESSON XIV.

STOMACH AND SALIVARY GLANDS.

STRUCTURE OF THE STOMACH.

1. MAKE transverse vertical sections from the middle or cardiac end of a *cat's* or a *dog's stomach* which has been hardened in potassium bichromate or absolute alcohol. Stain some of the sections with hæmatoxylin or carmine, leave others unstained; mount them in glycerine. The general features will best be made out with a low power. Observe
 - a. Externally, the connective tissue layer of the peritoneum.
 - b. The **muscular coat**, consisting of an outer longitudinal and an inner circular layer of unstriped muscle. If the sections are accurately transverse, the former will appear as a cross section of a number of bundles with connective tissue running in between them from the peritoneum, the latter as a continuous layer. On the inner side of this may also be seen a much thinner oblique muscular layer.
 - c. The **submucous coat** of connective tissue.
 - d. The **muscularis mucosæ**, divided more or less distinctly into an outer longitudinal and an inner circular layer.

- e.* The **mucous coat**. Note in this
- a.* The gastric glands with their openings and the ridges between the openings. Try to make out the bifurcation of some of the glands.
 - β.* The fine connective tissue immediately internal to the muscularis mucosæ, surrounding the bases of the glands, and sending up processes between them. Towards the surface the fibres have a much closer arrangement, and appear as a number of slender, comparatively dark, bands, which stain deeply: be careful not to confound these with the mouths of the glands. Mark the scarcity of leucocytes.
 - γ.* Using a high power, note further the clear slender **columnar** epithelium lining the upper portions of the glands and covering the free surface of the gastric mucous membrane forming the ridges between the glands.
 - δ.* The large coarsely granular **ovoid**¹, or 'peptic' cells, placed in the middle and lower part of each gland. They frequently cause a bulging outwards of the basement membrane, this is especially seen if the animal has been killed during digestion.
 - ε.* The small pale and finely granular **central** cells, cubical or polyhedral in form, intermixed with the ovoid cells, and best seen at the lower part of the gland.

¹ Since the functional importance of the different kinds of cells is still much disputed, it is thought best to employ names which do not imply any special function.

The columnar cells will stain little or not at all with hæmatoxylin, the central cells moderately, and the ovoid cells deeply, more especially their nuclei. The relative amount of colouration, however, depends very much upon the state of nutrition of the cells¹.

2. Make longitudinal vertical sections from the same part of the stomach. Note the difference in appearance of the muscular layers; in other respects the sections resemble the transverse ones.
3. Make transverse or longitudinal vertical sections from the pyloric end of the stomach, staining them with hæmatoxylin, and note
 - a. The greater thickness of the circular muscular layer, and the absence of the oblique layer.
 - b. The more frequent branching of the glands, and the absence of ovoid cells. The ovoid cells do not suddenly disappear as the pylorus is approached, so that glands containing a few such cells may be seen.
4. Prepare surface sections of a cat's or dog's gastric mucous membrane, which has been taken warm from the body and placed in absolute alcohol, cutting across the glands; stain some, leave others unstained. Observe

In sections of the upper part of the gland,

- a. The small central lumen.
- b. The basement membrane.
- c. The columnar cells with their broad ends abutting on the lumen, and their coin-shaped nuclei situated at the fixed extremities of the cells.

¹ To determine this, carmine staining by Heidenhain's method (see Appendix) offers perhaps the best means.

the upper part of the œsophagus shew no unstriped fibres.

- b.* The submucous tissue contains *serous* and *mucous glands*. Each of these consists of a duct, dividing and ending in dilatations, the alveoli.

The ducts are lined with columnar epithelium, and the alveoli with spheroidal or cubical cells flattened against one another.

- c.* Traces of the muscularis mucosæ.
d. The papillæ of the mucous membrane.
e. The epithelium forming a layer several cells deep, the deeper being columnar or spheroidal, the superficial cells flattened (cf. Epidermis, Lesson XXIII.).

STRUCTURE OF THE SALIVARY AND PANCREATIC GLANDS.

Mucous Glands.

1. Prepare sections of sub-maxillary gland of a *dog* which has been removed warm from the body, cut up into small pieces, and placed in absolute alcohol. Stain some with hæmatoxylin or carmine, leave others unstained.

With a low power observe

- a.* The division of the section into irregular angular areas, by connective tissue septa, which, if the section includes the circumference, will be seen to proceed from the sheath of the gland. These are the primary **lobules**; they may be seen to be divided into smaller lobules, but probably not distinctly.

- b.* The **alveoli**, appearing with objective No. 3 or 4 as small round bodies closely aggregated together to form the lobules; each will be seen to consist, more or less clearly, of a group of cells surrounded by connective tissue, continuous with that of the septa.
- c.* At intervals oblique and transverse sections of the small **ducts**. They are usually stained darker than the alveoli, are not surrounded by a sharp ring of connective tissue, and have a well-defined lumen.

2. With a high power observe that

- a.* The alveoli vary considerably in size, and frequently have no lumen; when visible the lumen is usually an irregular central space between the cells.
- b.* The **mucous** cells are comparatively large and as a rule globular, but modified in form by being pressed together; each contains a round or coin-shaped nucleus, situated generally in the outer part of the cell.

The nuclei of these cells will be stained, but the cell-substance usually not, except the part immediately surrounding each nucleus.

- c.* The **demilune cells** lie immediately beneath the membrana propria, stained throughout: they are generally half-moon shaped, with one, often two nuclei; they frequently send processes in between the mucous cells, and then appear simply to fill up the spaces between the mucous cells and the membrana propria.

- d.* The epithelium of the small ducts consists of a single row of slender columnar cells, the inner borders of which apparently coalesce and form a distinct ring bounding the lumen; there is no such distinct boundary to the outer (circumferential) part of the cell, which especially in hæmatoxylin specimens has a well-marked striation. Each cell contains an oval nucleus, staining deeply, situated rather to the inner part of the cell.
3. Take a small piece of a dog's submaxillary gland that has been for three to six days in a 5 p.c. solution of neutral ammonium chromate, and tease out in the same fluid. Observe the now isolated cells, noting in the mucous cells that the deep-seated end in which the nucleus lies is prolonged into a process, and that this, together with a varying amount of the cell-substance around the nucleus, is more granular and opaque than the rest of the cell. It represents, in fact, the protoplasm of the cell which has not undergone mucous metamorphosis.

Serous Glands.

Cut sections of the submaxillary gland of a *rabbit*, and compare with the above. Note that in the alveoli

- a.* The cells are more or less polyhedral and stain regularly and fairly deeply throughout.
- b.* There are no mucous cells.
- c.* The nuclei are globular, and placed approximately in the centre of the cells.

Pancreas.

Cut sections of the pancreas of a dog, and observe that its structure is in the general features given above like that of a serous gland.

LESSON XV.

SALIVA AND GASTRIC JUICE.

SALIVA.

1. INDUCE the secretion of saliva by chewing a small piece of india-rubber tubing, by filling the mouth with ether vapour, or by placing a crystal of tartaric acid on the tongue.

Allow the mixed saliva to stand until the turbidity has settled down into a sediment. To a portion of the clear fluid add acetic acid; a thick stringy deposit of **mucin** will take place, which does not dissolve (except with great difficulty) in excess of acid.

2. Filter off the mucin; to the clear filtrate add a few drops of a saturated solution of potassium ferrocyanide. The turbidity which results indicates the total quantity of albuminous bodies present (cp. Lesson III. § 10 c).
3. Take three test-tubes, *A*, *B*, *C*, and place in each the same quantity of starch mucilage¹. Dilute a little fresh saliva with five times its volume of water, and divide it into two parts. Add one part to *B*.

¹ To prepare starch mucilage, take a little wheaten starch, and rub it into a thin paste with cold water. Pour it into a beaker containing about two hundred times its volume of boiling water, boil for about five minutes and let it stand. Decant the clear supernatant fluid.

Thoroughly boil the other part for three or four minutes, and add it to *C*. Then place the test-tubes, *A* containing starch paste only, in the water bath at a temperature of 35° C. for ten minutes.

Divide the fluid in *A* into two parts.

- a.* Add a drop or two of a solution of iodine; the characteristic blue colour produced by starch and iodine will appear.
- b.* Add a few drops of Fehling's fluid, just sufficient to give the mixture a blue tinge, and boil; no decolouration or deposit will take place, shewing the absence of sugar.

Treat the fluid in *B* in the same way.

- a.* There will either be no blue colouration or but a slight one, shewing the disappearance or diminution of starch. There may be a violet colour due to the presence of dextrine.
- b.* There will be a copious yellow precipitate, due to the reduction of cupric to cuprous oxide, shewing that sugar has replaced starch. Take a little grape-sugar, and boil with Fehling's fluid, to observe the normal effects.

Treat the fluid in *C* in the same way.

Its behaviour as regards both *a* and *b* will be exactly the same as that of *A*, unless there happen to be an appreciable quantity of proteids present in the saliva, in which case the blue colour may be changed to violet (cp. Lesson III. § 11 *c*).

A shews that the mucilage does contain starch and does not contain any grape-sugar.

B shews that under the action of the saliva the starch disappears and grape-sugar appears in its stead.

C shews in the first place that the saliva itself contains no grape-sugar, and in the second place that the activity of the saliva is destroyed by exposure to the temperature of 100° C. This destruction by heat is one of the proofs that the activity of saliva is due to the presence in it of a *ferment*—the so-called **ptyalin**.

4. Take three test-tubes. Pour into each the same quantity of saliva and of starch. The quantity of saliva should be small; two or three drops of a diluted saliva is sufficient. Keep *A* at 35° C., *B* at the ordinary temperature, *C* surrounded by ice and salt. Examine portions from each at intervals, with iodine and Fehling's fluid.

The starch in *A* will be rapidly converted into sugar; that in *B* much more slowly, and in *C* hardly at all. Then expose *B* and *C* to 35° C.; the conversion will be rapid and complete.

This shews that the action of the saliva is favoured by a temperature as high as 35°, retarded at a lower temperature, and arrested without any *destruction* of the ferment at about the temperature of 0° C.

5. Pour saliva, diluted with five times its bulk of water, over raw starch¹, and expose it to 35° C., shaking frequently. The conversion will be extremely slow; the water above the starch will not contain sugar for an hour or two.
6. Place some dilute starch mucilage in one dialyser² (*A*), and another portion with saliva in another (*B*).

¹ Arrow-root will do very well.

² A dialyser can easily be made by tightly tying a piece of parchment paper over the mouth of a test-tube and cutting off the closed end.

Leave them for twenty-four hours. Then examine the external water in each. That from (*A*), tested with iodine and Fehling's fluid, will give no trace of starch or sugar. That from (*B*) will contain sugar, but no starch. Sugar dialyses, but starch does not.

7. Look at a little fresh saliva under the microscope with a high power. Disregarding the flat epithelial cells from the mucous membrane of the mouth, note the so-called salivary corpuscles, which are larger than the ordinary white blood-corpuscles, but in other respects indistinguishable from them. In many, a very active Brownian movement of the granules within the corpuscle may be observed.

GASTRIC JUICE.

1. **Artificial Gastric Juice.**

- a.* Remove the mucous membrane from the middle region of a pig's stomach. Mince it finely. Put it in a flask with two hundred times its bulk of hydrochloric acid .2 p. c., and place the flask in the warm chamber at a temperature of 35°C. After some hours nearly the whole will be dissolved. Decant, and filter the decanted fluid. A solution of pepsin in hydrochloric acid will be obtained; it will, however, contain a considerable quantity of peptones.
- b.* Cut a portion of the same mucous membrane into minute pieces. Remove with filtering paper as much moisture as possible. Cover the pieces with strong glycerine. After a few hours the glycerine will become strongly impregnated with pepsin. It may be kept for a great length of

time, and the glycerine may be several times renewed. A few drops of this glycerine extract added to 100 cc. of hydrochloric acid .2 p. c. will yield a fluid of high digestive power.

2. Action of Gastric Juice.

a. Take four test-tubes. In *A* place 5 cc. of hydrochloric acid .2 p. c. In *B* 5 cc. of artificial gastric juice. In *C* 5 cc. of the same juice, carefully neutralized. In *D* 5 cc. of the same juice, thoroughly boiled. Put the same quantity of fibrin¹ in each, and expose in the warm chamber. Examine after a few hours.

A, the fibrin will be swollen and transparent, but not dissolved; on neutralization it will appear unaltered.

B, the fibrin will be wholly digested.

C, the fibrin will be opaque and unaltered.

D, the fibrin will be like that in *A*.

These experiments shew that acid alone (*A*) and pepsin alone (*C*) will not digest, and that pepsin loses its power on being heated to boiling point (*D*). Now add acid again to *C*, and place it in the warm chamber. Digestion will take place. The neutralization has only suspended, not destroyed, the action of the pepsin.

b. Take two test-tubes, with 5 cc. of gastric juice and a morsel of fibrin in each.

Place *A* in the warm chamber. Surround *B* with ice, or put it in a cold spot.

¹ The fibrin should be previously boiled, in order to destroy the small quantity of pepsin frequently present.

The fibrin in *A* will be digested rapidly; that in *B* very little or not at all.

- c. To 5 cc. of gastric juice add a small piece of fibrin and keep it in the warm chamber. When digested throw in another flake of fibrin. Continue this as long as the fibrin disappears. When digestion appears to cease, add 10 cc. of hydrochloric acid .2 p. c. Digestion will begin again.

It was arrested by the presence of concentrated peptones. Dilution with weak acid sets it going again.

3. Products of Gastric Digestion.

- a. To 20 cc. of serum or egg-albumin add 20 cc. of .2 p. c. hydrochloric acid. Place it in the warm chamber. From time to time remove a few cc. and boil. The first specimens will coagulate as usual, but the coagulation becomes less and less until at last there is not even a turbidity on boiling. When this stage has been reached, carefully neutralize the remainder. A copious precipitate occurs, which, separated by filtration, is soluble in dilute acids and alkalis. This is *acid albumin*, or *syntonin*, or *parapeptone*. (Cp. Lesson VII. § 13.) If the neutralization has been perfect, the filtrate from the precipitate contains no albumin; the whole of the serum or egg-albumin has by the action of the acid become converted into acid albumin.
- b. Digest a handful of fibrin or other proteid with artificial gastric juice. Decant the fluid,

filter through a coarse filter; and carefully neutralize it; a deposit of parapeptone, variable in amount, will take place. Filter off the parapeptone. The filtrate contains peptones.

4. Determine the following *characters of peptones*.
 - a. Their solutions are not coagulated by boiling.
 - b. They are not precipitated by nitric acid.
 - c. They give Millon's and the xanthoproteic reaction.
 - d. With a very small quantity of Fehling's fluid they give a precipitate which dissolves in excess, forming a *red* and then a violet solution.
 - e. They dialyse readily. Pour on one dialyser (A) a solution of peptones, on another (B) egg-albumin. In a short time the external water of A will give evidences of proteids, but not that of B.

5. **Action of Gastric Juice on Milk.**

Prepare some artificial gastric juice either as in § 1 *a*, or by simply rubbing up the mucous membrane of any mammal with a little warm water, and filtering.

- a. Pour into a test-tube 5 cc. of fresh milk and add to it a little of the artificial gastric juice; there will be a flocculent precipitate varying in degree with the amount of acid in the juice. Place it in a warm chamber and observe from time to time. The precipitation will become more decided, so that in two or three hours there is a clot floating in a clear fluid. This is due to

the **casein** of the milk being precipitated by the gastric juice, and carrying down with it the fat-globules. If it be left in the warm chamber till the next day, the fluid will be found to be again 'milky' and to contain peptones; the gastric juice has acted on the precipitated casein, turning it first into para-peptone and then into peptones, and so setting the fat-globules once more free.

- b. Neutralize a little gastric juice carefully with sodium carbonate, add it to 5 cc. of milk, and place it in the warm chamber. Except that there is no precipitation on mixing the fluids, the results are the same, shewing that the clotting of the milk is not due to the *acid* of the juice.

The following experiments may be made on **Milk**.

1. Examine a drop of fresh cow's milk under the microscope with objective no. 7. Note that it consists of a clear fluid containing a large number of highly refractive (**fat**) globules of varying size. Add a drop of acetic acid; in a short time the globules in contact with one another will coalesce. The acetic acid dissolves the thin envelope of casein or alkali albuminate which prevented them running together.
2. Test the reaction of fresh cow's milk with litmus paper. It will be found to be **alkaline**: occasionally it is acid owing to the presence of free lactic acid.

Place about twenty cubic centimetres in a warm place for forty-eight hours; then again test the reaction, it will be found to be acid; this is due to **fermentation**, in the process of which the **milk-sugar** is converted into lactic acid.

3. Neutralize a little milk with dilute acetic acid; no precipitate will fall. Continue to add the acetic acid *carefully*, warming to 35° C.; a precipitate of **casein** will occur, carrying down with it nearly all the fat. When there is a distinct precipitate, no more acetic acid should be added, as casein is soluble, though not very readily, in excess; it is not precipitated on merely neutralizing, since there are alkaline phosphates present in milk. To precipitate the whole of the casein, the milk must be very much diluted.
4. Filter the milk from which the casein and fat have been precipitated, and test the clear filtrate for **albumin** (Lesson III. § 10); a small quantity will be found.

DEMONSTRATIONS.

The change in the microscopical appearances of the sub-maxillary gland of the dog, caused by prolonged stimulation of the chorda tympani.

The action of the chorda tympani and sympathetic nerves in the rabbit.

LESSON XVI.

INTESTINE. BILE AND PANCREATIC JUICE.

STRUCTURE OF INTESTINE.

THE outer coats of the intestine have the same general characters as those of the stomach (Lesson XIII. § 1, *a. b. c. d.*), except that there is no oblique muscular layer.

1. Prepare vertical sections of a cat's or dog's **ileum** hardened in chromic acid. Stain some with hæmatoxylin, leave others unstained, and mount in glycerine. Observe in the *mucous coat*
 - A. The conical projections of the mucous membrane, or **villi**, either extended and long, or contracted and short with the surface thrown into folds. Note
 - a.* The epithelium, consisting of **conical** cells, each with a hyaline or striated border, granular protoplasm and oval nucleus; the free borders of the cells frequently appear to have coalesced into a narrow highly refractive band.
 - b.* The **goblet** cells, irregularly scattered among the former, sometimes abundant, sometimes scanty or absent; they are seen in the section as transparent round or oval cells with sharp outlines.
 - c.* The **adenoid** tissue, forming the substance of the villus: this consists of a fine meshwork of fibres

with nuclear-like thickenings at the nodal points. The meshes are seen to be crowded with leucocytes.

There may also be seen with varying distinctness

- d.* Beneath the epithelium indications of capillary blood-vessels in the form of rows of blood-corpuscles, and sometimes the outlines of the walls with their nuclei.
 - e.* If the intestine be that of an animal killed during digestion, the 'lacteal radicle' in the centre of the villus as a club-shaped mass of finely granular matter.
 - f.* Unstriped muscular fibres as narrow bands running up the villus.
- B.** The depressions of the mucous membrane or **glands of Lieberkühn.** Note that
- a.* The epithelium lining them consists of short columnar cells. Observe their graduation into the cells covering the villi.
 - b.* There is a distinct basement membrane immediately beneath the epithelium. This is formed of connective-tissue corpuscles very much flattened and fused together into a membranous sac; the outlines of the cells are not seen in the section, but their nuclei are fairly conspicuous.
 - c.* The lumina of the glands are small, but in thin sections distinct.
- C.** The adenoid tissue around the bases of the glands of Lieberkühn and between them and the muscularis mucosæ. This, unlike the corresponding tissue in the

stomach (Lesson XIII. § 1. *e. β.*), has a large number of leucocytes in its meshes.

- D. The **closed follicles**, isolated or aggregated into **Peyer's patches**; the follicles are round or oval masses of adenoid tissue crowded with leucocytes, lying immediately beneath the surface epithelium and often stretching down into the submucous tissue. They are in the midst of the glands of Lieberkühn, and the villi are absent over them. They will be more fully studied under Lymphatics (Lesson XVI. §§ 1. 2. 3).
2. Tease out in water a vertical section from the ileum or jejunum, and observe more closely,
- a. The individual characters of the conical cells covering the villi, their often branched central process, and the hyaline peripheral border.
 - b. The goblet-cells; they will be seen to be flask-shaped cells with the greater part of the protoplasm replaced by a cavity filled with granules (of mucus) or clear fluid, a small portion only being left around a generally misshapen nucleus at the base of the cell. In the older goblet-cells may be seen a round opening at the top through which the mucus has been discharged.
The characters of these cells will be still better seen by teasing out a small fragment of intestinal mucous membrane which has been treated with osmic acid.
 - c. The characters of the cells and the basement-membrane of the glands of Lieberkühn.
3. Prepare sections of the ileum or jejunum through the glands of Lieberkühn parallel to the surface, and compare them with the vertical sections (§ 1, B. C.).

4. Prepare vertical sections of the duodenum at its commencement close to the pylorus. It will be seen that the villi and glands of Lieberkühn are present as in the rest of the small intestine, but that the closed follicles are scanty or absent. Note further

The **glands of Brunner**. Each has a duct with basement-membrane, columnar epithelium and distinct lumen. This dipping down into the submucous tissue forms a terminal knot of convoluted and branching tubes, usually without much change in the characters of the cells. (Cf. Sweat-gland, Lesson XXIII. § 2.)

5. Snip off a few villi from a perfectly fresh intestine of a mammal, and examine in normal saline solution.
- a. Observe the epithelium *en face*, and the characters of the individual cells.
 - b. Irrigate with dilute acetic acid; observe the nuclei of the plain muscular fibres.
6. Prepare vertical transverse sections of the **large intestine**. Observe
- a. The longitudinal muscular coat, thin except where the section has passed through one of the three conspicuous bands.
 - b. The circular coat, thick and well-developed.
 - c. The mucous membrane, frequently thrown into longitudinal ridges.
 - d. The entire absence of villi.
 - e. The glands of Lieberkühn; they are larger than in the rest of the intestine, and their features, through the absence of the villi, much more easily seen. The epithelium covering the free intestinal surface or the ridges between the glands, has the same

slender columnar character as that covering the free gastric mucous membrane.

7. Examine sections of a small intestine in which the blood-vessels have been injected, and note the capillaries running up between the glands of Lieberkühn, and forming a network in the villi close beneath the surface.

BILE.

Constituents and Reaction.

Take fresh ox-gall and dilute it with four times its bulk of water.

1. Test the reaction with litmus paper. If fresh it is distinctly *alkaline*.
2. To a small quantity add acetic acid. A curdy precipitate of *mucin* coloured with the bile-pigment will be thrown down. Since the mucin of bile is not obtained from the liver but from the mucous glands and cells in the gall-bladder and duct, the longer the bile has been in the gall-bladder the greater the precipitate which will be obtained.
3. *Gmelin's test for bile-pigment.* To a small quantity add gradually, drop by drop, shaking after each drop, some nitric acid, yellow with nitrous acid; the yellowish green colour gradually becomes first a bluish green, then blue, then violet, then a dull red, and finally a dirty yellow. Another method is to pour the acid carefully over a small quantity of bile in a test-tube, or to let a drop of bile mingle with one of acid on a porcelain slab; where the fluids mingle, zones of colour, green, blue, violet, red and yellow, from the bile to the acid, are seen.

This reaction is more strikingly shewn with yellow bile, taken direct from the body of a dog or rabbit and so free from mucus. The first change then is from yellow to green.

4. *Pettenkofer's test for bile-salts.* Take a little bile, or preferably a drop of prepared bile-salts, and dissolve it in a small porcelain basin in a small quantity of water: add a small pinch of powdered cane-sugar. Add strong sulphuric acid drop by drop, continually stirring and keeping the temperature¹ at about 70° C. The acid first causes a cloudy precipitate of cholic acid, and then dissolves it, giving a characteristic purple colour.
5. *Preparation of bile-salts.* Rub ox-gall with animal charcoal into a thin paste. Evaporate on a water bath to complete dryness, and exhaust with absolute alcohol. The alcoholic filtrate should be colourless. Add to it anhydrous ether as long as any precipitate is produced, and let it stand. The precipitate either crystallizes out or falls to the bottom as a thick viscid syrup; it is a mixture of sodium glycocholate and taurocholate.

Properties.

6. Moisten a small filter *A* with water, another *B* with a watery solution of bile-salts. Pour into each filter the same quantity of olive-oil. Take care that neither filter becomes dry, by moistening occasionally the outside. In a few hours some of the oil will have passed through *B*, but none at all through *A*.

¹ The bile and sugar solution may be placed in a test-tube, and the sulphuric acid poured down the side so that it collects at the bottom. On shaking the test-tube gently the two fluids mix, and the proper temperature can be easily obtained.

7. Shake up equal quantities of ox-gall and oil. An emulsion will be formed, and will remain for some time; but eventually the two liquids will separate. For comparison, shake up equal quantities of water and oil; the two liquids will separate much more quickly.
8. Digest some fibrin in gastric juice, and to the acid mixture when digestion is nearly complete, add bile, or a solution of bile-salts. A copious precipitate of parapeptone takes place. The clear supernatant liquid, even when acidified again, will not be peptic, the pepsin having been carried down with the precipitate.

PANCREATIC JUICE.

Artificial Pancreatic Juice.

1. Mince a piece of any fresh pancreas, and with lukewarm water make an infusion. If the infusion is at all acid, neutralize with sodium carbonate. Strain it through muslin. It will have all the properties of pancreatic juice, but its power of acting on proteids (*i.e.* the amount of the proteolytic ferment) will vary greatly with the nutritive state of the pancreas.
2. Make a glycerine extract of pancreas, in the same way as the glycerine extract of gastric mucous membrane was made. It will contain a considerable amount of the amylolytic ferment, and a variable amount (as in § 1) of the proteolytic ferment.
3. Mince finely a piece of fresh pancreas, and rub it up in a mortar with powdered glass or pure sand. For each gramme of gland-substance add 1 cc. of acetic acid 1 p.c., and mix thoroughly in the mortar

for ten minutes. Add ten times the volume of glycerine, and let the whole stand for two or three days. By treating the pancreas with acetic acid as above, the 'zymogen' or substance yielding the proteolytic ferment has been converted into ferment, so that there is a much greater proportion of it in this extract than in that of § 2.

Properties.

4. Melt some lard, and at a temperature not above 40° C. mix one part of melted lard with two parts of the pancreatic infusion (§ 1), rubbing them gently together in a warm water bath. A thick creamy emulsion results, which will remain an emulsion even in the cold for some hours.

The glycerine extracts will not cause an emulsion with oil, since they do not contain the alkali albuminate which is the chief agent in this action.

5. With the glycerine extract (§ 2) make observations similar to those made with the amylolytic ferment in saliva (Lesson xv. §§ 3—6).
6. Take two test-tubes, and add to each a few drops of the glycerine extract (§ 3) diluted with a 1 p. c. solution of sodium carbonate. Boil one (*A*), leave the other (*B*) unboiled. Place in each a fragment of boiled fibrin, and expose to a temperature of 35° C. In a short time the fibrin in *B* will have become dissolved, while the fibrin in *A* remains much as it was. In *B*, peptones will be found. The solution of the fibrin by the action of the proteolytic ferment of the pancreas differs from pepsin digestion in that no transparency is produced, and the fibrin appears as if corroded rather than dissolved.

DEMONSTRATIONS.

The appearance of the chyle in the lacteals of the mesentery of a rabbit a few hours after a meal,

- a.* Above the entrance of the pancreatic juice into the intestine,
- b.* Below the entrance of the pancreatic juice into the intestine,

The flow from the thoracic duct.

The process of absorption of fat. (Schäfer's *Practical Histology*, p. 194.)

LESSON XVII.

THE LYMPHATIC SYSTEM.

LYMPHATIC GLANDS.

1. PREPARE vertical sections of a rabbit's **Peyer's patch** which has been hardened in alcohol, and stain them with carmine. When stained, mount a section at once, to observe the immense number of leucocytes; shake up the others in a test-tube with distilled water. Look at them under a low power to see if the leucocytes are for the most part shaken out; if so, mount them in glycerine. Select a comparatively isolated follicle, and observe
 - a. The adenoid tissue of the follicle, continuous more or less distinctly with the neighbouring adenoid tissue, and resembling it in all respects except that the fibres are, as a rule, finer, and the meshes smaller.
 - b. Around parts of the follicle, narrow spaces between it and the surrounding tissue; these represent the **lymph-sinus** on the outside of the follicle.
 - c. The leucocytes scattered on the outside of, but especially abundant within, the follicle.

2. Examine prepared sections of a Peyer's patch with the blood-vessels injected. Note the small arteries passing into each follicle, and dividing into a number of capillaries which run nearly to the centre and then curve back again.
3. Examine prepared sections of a Peyer's patch with the lymphatic system injected (Hdb. p. 117). Note that the injected material envelopes to a greater or less extent the separate follicles; it occupies the lymph-sinus spoken of above, and does not penetrate into the interior of the follicle.
4. Examine sections, stained and unstained, of an ox's mesenteric **lymphatic gland**, hardened in ammonium bichromate or in alcohol alone. Pencil the sections, *i. e.* gently rub them with a fine camel's-hair brush, or shake them in a test-tube with distilled water. Mount in glycerine. Observe with a low objective the following general features:
 - a. The connective tissue surrounding the gland, and sending in
 - b. The **trabeculae**, which divide the whole gland into a meshwork of **alveoli**.
 - c. Towards the exterior the alveoli are large, elongate, and arranged in a radiate manner, forming the **cortex**.
 - d. In the centre and round the hilus the alveoli are smaller, and the meshwork close set, forming the **medulla**.
5. Examine sections as thin as possible of a small portion of medulla or cortex. Observe with a high objective.

- d.* The trabeculæ contain a variable number of unstriped muscular fibres: in some animals, *e.g.* dog, ox, muscular fibres are the chief constituents.
- e.* At the edge of the specimen a reticulum comes into view, in the meshes of which are still a few leucocytes: in the Malpighian corpuscles this reticulum is composed of anenoid tissue like that of the lymphatic glands, whilst in the splenic pulp, in some places at any rate, it may be seen to be composed of connective-tissue cells with communicating branches: the intimate structure is however not easy to make out satisfactorily, owing to the difficulty of getting rid of leucocytes.
3. Cut across a fresh spleen, preferably one from which the blood has been removed by injecting normal salt solution through the splenic artery, and examine it with the naked eye. Note the white **Malpighian corpuscles**. Cut out one with some surrounding tissue with curved scissors, and tease it out well in normal salt solution. Observe the large number of leucocytes of very varying size floating about, some not distinguishable from white blood-corpuscles; others twice, others three times as large: in some of the larger ones will be seen brownish-red fragments, stages of the breaking down of red blood-corpuscles. Try to make out the constituents of the reticulum (§ *e*).
- Note in the trabeculæ the white fibrous tissue, the few elastic fibres and the varying amount of unstriped muscular tissue; add acetic acid to bring into view the nuclei of the muscular fibres.
4. Examine a section of spleen injected from the splenic

artery, and observe that the injection spreads out irregularly into the splenic pulp.

LYMPHATIC CAPILLARIES.

The lymphatic trunks need not be noticed, since their structure is essentially the same as that of the veins. (Lesson x.)

1. Lay open the abdomen of a frog, and carefully remove the intestines, and if necessary the oviducts. It will be seen that the peritoneum above and to the outside of the kidney is not adherent to the lumbar muscles, but is separated by a space—the cisterna magna lymphatica. Cut out the piece of peritoneum which forms the partition between this space and the general peritoneal cavity, pin it carefully out flat over a ring of cork or paraffin, stream it gently with water, and immerse it for ten minutes in silver nitrate solution, .5 p. c. Wash it well with distilled water, and expose to light. After twenty-four hours, divide it in two pieces, mount them in glycerine, one (*a*) with the peritoneal surface uppermost, the other (*b*) with the cisterna surface uppermost. Observe

in (*a*)

- a.* The peritoneal epithelium, consisting of large flat cells with a slightly sinuous outline. This is the usual character of the cells lining serous cavities.
- β.* Where several more or less triangular cells seem to radiate from a common point, note at their apices the small granular nucleated cells surrounding the orifice or **stoma** leading from the peritoneum to the cisterna.

in (*b*)

- a.* The lymphatic epithelium, consisting of flat cells, smaller than the peritoneal epithelium, and with a very irregular sinuous outline.
- β.* The stomata; very much as in (*a*).

2. Look at prepared specimens of the diaphragm of a rabbit or guinea-pig stained with nitrate of silver (Hdb. p. 112), the peritoneal surface being uppermost. Observe

- a.* The bundles of fibres forming the tendon of the diaphragm. The spaces between these mark for the most part the course of the lymphatic vessels and capillaries.
- b.* The peritoneal epithelium, consisting of flat polygonal cells. These are larger over the tendinous bundles than over the intervening spaces. Stomata similar to those of § 1 *a. β.* may be seen; they are chiefly found in the epithelium over the intertendinous spaces. Pseudo-stomata, irregular patches of staining at the junction of several cells, are frequent.

3. Look at prepared specimens of the diaphragm of a rabbit or guinea-pig, pencilled and stained with nitrate of silver (Hdb. p. 110), the pleural surface being uppermost. Observe

- a.* The small lymphatic vessels, running between the tendinous bundles and lined with somewhat irregular spindle-shaped epithelium. In places the curved outline of a valve may be seen.
- b.* The lymphatic capillaries with their characteristic sinuous epithelium.

- c. The origin of the lymphatics. This is best seen in specimens deeply stained with nitrate of silver, so as to produce the so-called negative image. Note the clear branched spaces, whose sinuous outline resembles that of an epithelium-cell of a lymphatic capillary. The clear spaces, cavities containing unstained connective-tissue corpuscles, stand out in strong contrast with the surrounding stained matrix. The junction of these spaces with the interior of a lymphatic capillary, may here and there be seen.

DEMONSTRATION.

The injection of the lymphatics of the testis. (Schäfer's *Practical Histology*, p. 216.)

LESSON XVIII.

LIVER AND GLYCOGEN.

STRUCTURE OF LIVER.

1. PREPARE sections of a liver hardened in Müller's fluid or potassium bichromate. Observe with a low objective
 - a.* The division into **lobules**.
 - b.* The **hepatic cells** and their radiate arrangement in the lobule.
 - c.* The **intralobular** or **hepatic veinlet**. This frequently appears in the section as a clear space in the centre of the lobule.
 - d.* The **interlobular** or **portal veinlet**: branches of this, as well as of the **hepatic artery**, are seen between the lobules sending off capillaries towards the hepatic veinlet.
 - e.* The **bile-ducts**, recognisable by their distinct lining of cubical or columnar epithelium.

The distinctness with which *c* and *d* are seen will depend on the plane in which the section passes through the lobules.
2. Examine sections of a liver, the blood-vessels of which have been injected both from the hepatic vein (red

or blue) and from the portal vein (blue or red). Observe, comparing with uninjected specimens,

- a.* The hepatic veinlet, seen according to the plane in which the lobule is cut, either as a more or less circular section, or as a short veinlet passing from the centre of the lobule to the sublobular vein.
 - b.* The portal veinlet running on the outside of the lobule.
 - c.* The radial capillary network uniting the portal and hepatic veinlets.
3. Prepare very thin sections of the uninjected liver, and examine with a high objective. Observe
- a.* The polygonal outline of the hepatic cells.
 - b.* Their granular protoplasm, generally containing oil-drops.
 - c.* Their spheroidal nuclei. Many cells contain two.
 - d.* The capillary blood-vessels, traceable by their containing blood-corpuscles, running out from the centre of the lobule between the rows of cells, and joining with one another at intervals by cross branches.
 - e.* The bile-ducts, their columnar epithelium with distinct nuclei. In some of the sections the epithelium may be seen to become shorter and more cubical as the duct approaches a lobule. The duct itself often appears to end abruptly at the margin of the lobule.
4. Examine sections of a liver injected from the bile-duct. The bile-capillaries will be seen within the lobules

as a fine network of minute threads of injected material, passing between and over the surfaces of the cells.

5. Scrape a small portion of perfectly fresh liver, and examine the hepatic cells, comparing with § 3.

GLYCOGEN.

1. Open the abdominal cavity of a rabbit *immediately* after death, and, disregarding the bleeding, cut out the liver as rapidly as possible. Divide one half into pieces of about 2 cc., and throw them at once into a relatively large quantity of boiling water (prepared beforehand). Place the other half on one side in a warm place. In two or three minutes, when the pieces in the boiling water are all thoroughly coagulated, and the ferment has been destroyed, remove them and pound them in a mortar into a paste; mix this paste with the water previously used, acidulate with dilute acetic acid, and boil for three minutes. Let it stand till the sediment of proteids has settled, and filter the milky fluid through a coarse filter. The sediment may be squeezed in linen, and the expressed fluid thrown on the filter. This opalescent filtrate is a crude infusion of glycogen. The above will afford material for several students.

If it contains *much* proteid material, it should be carefully neutralized, boiled again, and filtered.

2. *a.* Place a few cc. of the fluid in a test-tube, and add a drop or two of a dilute iodine solution. A port-wine colour will result. Warm gently; the colour will disappear, but will return on cooling (unless much proteid matter be present).

LESSON XIX.

THE STRUCTURE OF THE LUNG. THE MECHANICS OF RESPIRATION.

1. Stain with gold chloride the lung of a freshly-killed newt, cut out a piece, and mount it with the inner surface upwards, note
 - a. The layer of flat epithelial cells,
 - b. The underlying connective tissue, with a close plexus of blood-vessels.
2. Distend the lungs of a frog with chromic acid .3 p. c., tie the trachea, and place the distended lungs in a relatively large quantity of the acid for a week and then treat with alcohol as usual. Stain a piece with hæmatoxylin; when it is well stained, soak it for a short time in bergamot oil, and imbed it in a mixture of spermaceti (1 part) and castor oil (4 parts), and let it cool. Cut sections, using olive oil instead of alcohol to wet the razor. Transfer the sections to a mixture of carbolic acid and turpentine, warm gently, and mount in Canada balsam. Observe with a low objective, the primary, secondary, and tertiary septa forming the alveoli, and with a high power the structure of the wall similar to that of the newt.
3. Make transverse sections from the posterior part of a small mammalian trachea, which has been hardened

in chromic acid .5 p.c. The section should be so taken as to cut through the ends of a tracheal ring and include the membranous part between them. Observe

- a. Externally, the **fibrous coat** of loose connective tissue, becoming denser towards the tube of the trachea; in this are imbedded the two ends of the ring of **cartilage**.
- b. Stretching between the ends of the cartilage, a **transverse band** of unstriped **muscular fibres**; there may also be visible outside this the cut ends of muscular fibres running longitudinally.
- c. The **submucous coat** continuous with the fibrous coat, but of finer fibres.
- d. The small **glands**, the alveoli of which form almost a continuous layer in the submucous tissue; the ducts will be less evident, but they may be seen running towards the surface, and occasionally opening on it.
- e. The cut ends of **elastic fibres**, which form a distinct longitudinal layer, on the inner side of the submucous tissue. It will be seen that this is most marked in the membranous part of the trachea; where, too, the fibres are frequently collected into bundles.
- f. The **mucous coat**. In this may be seen
 - a. A number of fine elastic fibres with a variable quantity of adenoid tissue, which becoming more dense towards the surface, forms a distinct basement membrane for

β . The epithelium, consisting of two, three, or more layers of small cells lying beneath and between the central processes of a layer of columnar ciliated cells. If the trachea has not been carefully hardened and prepared, the cilia may appear only as a granular border lying on the columnar cells. Goblet-cells will probably be seen amongst the ciliated cells.

4. Make longitudinal vertical sections of trachea, taken through the tracheal rings, and compare them with the transverse sections, noting especially the elastic and muscular elements.

5. Make sections, stained and unstained, of prepared mammalian lung, preferably the lung of a fœtus injected with and hardened in chromic acid .2 p. c. or potassium bichromate 1 p. c. Observe

a. Sections of blood-vessels (cp. Lesson XI.).

b. Sections of bronchia. Note that

The sections of the larger bronchia resemble sections of trachea, except that

a. The cartilages are irregular in form, and irregularly scattered throughout the fibrous coat.

β . The transverse muscular fibres now form a complete ring in the submucous coat.

From the smaller bronchia the cartilages are absent, but the muscular fibres still continue as scattered fibres arranged transversely.

c. The passage of a small bronchial tube into an infundibulum. Note that

- a.* The columnar ciliated cells become shorter and lose their cilia.
- β.* The muscular fibres apparently cease.
- γ.* The longitudinal fibres spread out into an irregular meshwork.

This may be occasionally seen in a section.

d. Sections of alveoli.

- a.* The outline of the alveoli: the distinct basement membrane.
- β.* The flat, tessellated epithelium. This will be seen best where a portion of the wall of the alveolus is left flat in the section; sometimes it may be seen in profile.
- γ.* The elastic fibres of the alveolar wall.
- δ.* The nuclei and collapsed walls of the capillaries.

6. Make sections of mammalian lung, injected with and hardened in alcohol acidulated with acetic acid. Observe more closely the abundant elastic fibres of the alveolar walls and the nuclei of the epithelium.
7. Make sections of a lung the blood-vessels of which have been injected. Observe the close-set capillary network over the alveolus, and the artery forming a circle round the mouth of each alveolus.

DEMONSTRATIONS.

1. The circulation in the lung of toad.
2. Tracing on the revolving drum of the movements of the column of air in respiration.
3. The movements of the diaphragm.
4. Apnœa.
5. Slight dyspnœa.
6. The action of the respiratory muscles in dyspnœa.
7. The collapse of the lungs on puncturing the thorax, and the consequent futility of the respiratory movements.
8. The action of the phrenic nerve.

LESSON XX.

THE COLOUR OF BLOOD. RESPIRATION.

1. PLACE a rat or guinea-pig under a bell-jar with a sponge moistened with chloroform. When it is thoroughly under the influence of the chloroform, quickly open the thorax, and cut across the heart. Collect the blood in a glass beaker, and whip it; pour one half of the defibrinated blood into a platinum crucible surrounded by a mixture of ice and salt. Leave it till it is frozen. Then remove it to a not too warm place, so that it may thaw slowly. By this means the blood-corpuscles will be broken up, and the blood will become of a dark 'laky' colour. If the blood does not become thoroughly laky it should be frozen and thawed again.

Compare the dark colour and transparency of this laky blood with the scarlet colour and opacity of the remaining half of the animal's blood which has been simply defibrinated. The opacity or transparency may be easily judged by attempting to read type through a drop placed on a glass slide.

2. Place the laky blood on one side in a cool place (a temperature of 0° C. is preferable) for 24 hours. A sediment will then have formed consisting partly of (oxyhæmoglobin) **hæmoglobin crystals** and partly of

broken up corpuscles. Or a drop of the blood, allowed to evaporate on a slide, will be found to contain crystals.

3. Examine the sediment under the microscope for oxyhæmoglobin crystals. Note
 - a. Their form. In the rat they are thin rhombic prisms, often almost needle-shaped.
In the guinea-pig they have the appearance of tetrahedra, but in reality belong to the rhombic system.
 - b. Their colour. It is that of arterial blood.
4. Examine the sediment for the stroma of the red blood-corpuscles. These will be seen as pale colourless rings mixed up with a good deal of granular débris.
5. Prepare a solution of oxyhæmoglobin. This may be done by dissolving the crystals in distilled water. In the absence of crystals the following method may be adopted.
Take a fresh blood-clot, and drain off as much serum as possible. Cut it into small pieces. Wash it with water, and throw away the first two washings. Treat it then with water, squeezing the pieces, and filter through a coarse filter.
6. Examine, by means of a spectroscope¹, the **absorption bands** of oxyhæmoglobin in a very dilute solution. Previously determine the position on the scale of the lines *B*, *C*, *D*, *E*, *F*, by examining the solar spectrum. If this is not practicable, determine at least the posi-

¹ The demonstrator will shew the method of using the instrument.

mediate between those of the two oxyhæmoglobin bands which have disappeared. The band is not quite intermediate; its mid-line lies nearer *D* than *E*. This single band is much less dark than either of the two bands produced by the same quantity of oxyhæmoglobin.

c. With stronger solutions, less of the blue end disappears. Instead of the green beyond *E* or *b* remaining, it is the blue beyond *F* which now remains.

9. Pour the reduced solution two or three times from one vessel into another so as to expose it well to air. The bright scarlet colour will be restored; the oxyhæmoglobin spectrum will reappear.

If allowed to remain at rest, reduction (from excess of reducing reagent present) soon returns.

10. Examine the spectrum of blood-crystals either with the microspectroscope or by placing a thick layer of crystals on a glass slide before the larger spectroscope. The spectrum of oxyhæmoglobin is seen.

11. Pass carbonic oxide through an oxyhæmoglobin solution for some little time.

a. Note the peculiar bluish tinge acquired. Examine the spectrum; two bands are seen like those of oxyhæmoglobin, but both placed more towards the blue end.

To compare their position, place some of the oxyhæmoglobin solution before the spectroscope, bring the micrometer wire *to the middle* of one of the bands, and fix the telescope in position. Replace the oxyhæmoglobin solution by the car-

bonic oxide hæmoglobin solution and examine; the middle of the band will now be to the blue side of the wire.

- b.* Treat the carbonic oxide hæmoglobin with either of the reducing agents used above. Reduction will not take place.
12. Place a drop of blood on a glass slide, and by *gently* warming evaporate it to dryness: add to it a very small grain of salt, and thoroughly mix it with the blood, rubbing the whole to a fine powder. Cover with a cover-slip, and let a couple of drops of glacial acetic acid run under it. Warm the slide, not too rapidly, over a flame till the bubbles appear under the cover-slip; then let it cool, and examine under a microscope with a high power. A large number of **crystals** of **Hæmin** as brown-red rhombic prisms will be seen. Care must be taken to use actual *glacial* acetic acid.

DEMONSTRATIONS.

The spectra of

- a.* Oxy-hæmatin.
b. Reduced hæmatin.

The gases of the blood.

The colour of venous and arterial blood in the living animal, and its dependence on the presence of oxygen in the lungs.

The respiratory function of the pneumogastric.

The action of the respiratory centre.

The effect of arterial and venous blood on the irritability of muscular tissue.

The phenomena of asphyxia.

LESSON XXI.

STRUCTURE OF THE KIDNEY.

1. FROM a mammalian kidney hardened in ammonium bichromate 5 p. c., prepare radial sections extending from the pelvis to the external surface. If any difficulty is experienced in cutting the sections, a microtome may be used. Observe with a low power
 - a. The **medulla**. Note the straight tubes, the **tubuli uriniferi recti**, radiating from the pelvis outwards. These, increasing in number by division, form the **pyramids of Malpighi**.
 - b. The **cortex**. Note
 - a. The pyramids of Malpighi, dividing at their base into a number of bundles, the **pyramids of Ferrein**. These, radiating outwards and becoming thinner, are lost as they approach the surface of the kidney.
 - β . The convoluted tubes, the **tubuli uriniferi contorti**, occupying the intervals between the pyramids of Ferrein, and forming a layer at the external surface.
 - γ . The **Malpighian capsules**, with their **glomeruli**, dispersed in double rows in the intervals between the pyramids of Ferrein.

The part of the cortex in which are the pyramids of Ferrein is frequently spoken of as the **marginal zone**. The part of the cortex containing the convoluted tubules is often distinguished from the pyramids of Ferrein by the name of **cortical substance**.

2. Prepare very thin radial sections of the medulla and of the cortex. Stain some with hæmatoxylin, and leave others unstained.
 - A. In the cortical substance observe
 - a. The **Malpighian capsules**. Note in each
 - a. The external wall of the capsule and the nuclei of the lining epithelium.
 - β. The glomerulus; the outline and nuclei of the blood-vessels (the nuclei of the investing epithelium).
 - γ. The narrow neck of the capsule. This is seen only when the section passes through the capsule in a particular plane.
 - b. The tubuli contorti: **secreting tubules**. Note in these that
 - a. The limits of the individual cells lining the tubules are very slightly shewn; a distinct cell-membrane being absent.
 - β. The cells consist of granular protoplasm, the outer part of which is often distinctly and coarsely striated.
 - γ. The lumen of the tubule is frequently indistinguishable. The nuclei are round, and more or less obscured by the striation.

B. In the medulla,

- c. The straight tubules: **collecting** or **discharging tubules**. Note in these
 - α. The short columnar or cubical epithelium, with round nuclei and well-defined outlines, leaving a considerable lumen in the centre of the tubule.
 - β. The distinct basement membrane.

C. In the pyramids of Ferrein,

- d. The **looped tubes of Henle**, consisting of
 - α. The **descending limb**. This may be recognized by its narrow calibre, and its transparent flattened epithelium, the nuclei of which project on alternate sides into the lumen, somewhat after the manner of a capillary blood-vessel. The basement membrane of the tubule is thick and conspicuous.
 - β. The **ascending limb**. This is wider than the descending limb, and in many cases does not differ in appearance from a collecting tube; frequently, however, its epithelium is imbricate. The nuclei of the cells are generally oval.

The change of character of the epithelium of the loop of Henle may take place either in the descending or in the ascending limb.
- e. The **connecting tubules**. These differ little from the secreting tubules, save that their course is zigzag, their bends being angular and not rounded.

Try and make out the following course of a tubule. The capsule is continuous by a narrow neck with a secreting tubule. This, after winding about in the cortical substance, descends (along a pyramid of Ferrein) towards the medulla as a descending limb of a Henle's loop, returns as an ascending limb, and, after a short course as a connecting tubule, redescends as a collecting tubule, and finally, by junction with others, becomes a discharging tube. No tube can be thus followed in a section, but the various transitions may be seen.

3. In sections through the cortex, and in tangential sections through the medulla, observe
 - a.* The firm, conspicuous, transparent membrana propria of the tubuli; often seen devoid of epithelium. This is thick in the loops of Henle, and thin in the other parts of the tubules.
 - b.* The nuclei of the membrana propria of the tubules, and of the interstitial connective tissue or stroma.
 - c.* The characters of the epithelium in the different tubules. Try to distinguish, in the sections of the pyramids of Ferrein, between the loops of Henle and the collecting tubules.
 - d.* The transverse, and other sections of the blood-vessels.

4. Examine sections of kidney injected from the renal artery. Observe

7. Scrape the internal surface of the mucous membrane, and observe more particularly the character of the epithelial cells.
8. Cut transverse vertical sections of a rabbit's or dog's **ureter**. Note that the structure is much the same as that of the bladder, but the longitudinal muscular coat is generally indistinct, and the submucous coat very loose.

With this as with other tubular organs it is of advantage to distend it moderately with the hardening fluid before removal from the body.

DEMONSTRATION.

Silver preparation to shew the structure of the Malpighian capsules.

LESSON XXII.

URINE.

1. TEST the reaction of fresh urine with litmus paper, it will be **acid**; this is mainly due to the presence of acid sodium phosphate, and *not* to free acid.
2. Put in a warm place 200 cc. of urine, and observe from time to time.
 - a. It will, after twenty-four or more hours, lose its acid reaction, and become alkaline. Gently warm the litmus paper turned blue by the urine, the blue colour will disappear, shewing that the alkalinity is due to the presence of ammonia or a salt of ammonium.
 - b. It will gradually become cloudy, and yield a deposit of various salts.
 - c. Its odour will become putrefactive.

The urine has undergone **alkaline fermentation**.

3. A small quantity of **mucus** derived from the urinary passages is occasionally present in the form of a faint cloudy precipitate. This may be rendered more opaque by the addition of acetic acid.

4. **Urea.** Place a few crystals of urea in a watch-glass, and dissolve them in a small quantity of water.
 - a. Let a drop of the solution evaporate on a glass slide, and observe under the microscope the crystals of urea, consisting of four-sided prisms. (Hdb. fig. 322.)
 - b. Add to another drop on a slide a drop of pure strong nitric acid; comparatively insoluble six-sided tablets of nitrate of urea will crystallise out. (Hdb. fig. 323.) Note the striation frequently present in these tablets.
 - c. Repeat (*b*), using oxalic instead of nitric acid. Rhombic tablets of oxalate of urea will be formed. (Hdb. fig. 324.)
 - d. Dilute considerably the remaining solution, and add to it a solution of mercuric nitrate. A white precipitate of mercuric oxide combined with urea will take place.
5. Evaporate 20 cc. of urine in a water-bath till its volume is reduced to about 2 cc. Filter, and examine the filtrate for urea (§ 4, *b. c.*)
6. **Uric Acid.**
 - a. Place a few crystals of prepared uric acid on a slide, and add a little liquor potassæ to dissolve them; then add nitric acid just to excess. Crystals of uric acid will be deposited, which may be examined under the microscope. They are generally rhombic plates with obtuse angles, but they vary largely (Hdb. fig. 305). Note the star-shaped and dumb-bell crystals.

- b.* Dissolve some uric acid in an evaporating dish, in a little dilute nitric acid, and evaporate nearly to dryness at a low heat in a water-bath. Add a drop or two of *weak* ammonia; a red purple colour will be formed. This is called the Murexide test for uric acid. If a drop of caustic potash be added the colour will turn to a blue purple.
7. Evaporate 50 cc. of urine to one-third its bulk; filter, and add to the filtrate a few drops of pure strong hydrochloric acid; set it aside till a red deposit is observed. Examine the deposit under the microscope for uric acid crystals, and subsequently apply the tests § 6, *a. b.*

TESTS FOR SOME ABNORMAL CONSTITUENTS OF THE URINE.

8. **Albumin.** The albuminous bodies found in the urine have, with rare exceptions, the reaction of serum albumin. Hence apply the tests for that substance. Lesson III. § 10.
9. **Sugar.** Diabetic urine. Coagulate any albumin that may be present, by just acidulating with acetic acid and boiling. Test with Fehling's fluid¹.
10. **Bile Pigment.** Use Gmelin's test. (Lesson XVI.)
11. **Bile-acids.** Soak a small piece of white blotting paper in a syrup of sugar, and allow it to dry. Let fall on it a drop of the previously concentrated urine supposed to contain bile-acids, and near it a drop of strong sulphuric acid, so that the two drops run into

¹ If only a small quantity of sugar or a large quantity of some other bodies as uric acid be present, this method cannot be relied on. Cf. Neubauer u. Vogel, p. 82 et seq.

one another. If bile-acids are present, there will be a purple colouration at the junction of the drops. This ready method can be adopted only when the quantity of bile-acids present is large.

QUANTITATIVE ESTIMATION OF UREA (LIEBIG'S METHOD).

12. The following standard solutions will be previously prepared by the Demonstrator.

- a.* A baryta mixture, consisting of two volumes of barium nitrate, saturated in the cold, and one volume of barium hydrate also saturated in the cold.
- b.* A solution of mercuric nitrate of such a strength that 1 cc. precipitates 10 mgr. of urea.

Take 40 cc. of urine, and add to it 20 cc. of the baryta mixture. A copious precipitate of barium sulphate, phosphate, etc. will fall. Filter and keep the filtrate. Fill a Mohr's burette with the mercuric nitrate solution, and let the solution fall drop by drop into 15 cc. of the filtrate, stirring constantly.

Have ready a glass plate on a dull black surface with a number of drops of sodium carbonate solution on it; from time to time add a drop of the urine to one of the sodium carbonate. When a yellow colour is thus produced, the mercuric nitrate is in excess, and all the urea has been precipitated. Since each cc. of the mercuric nitrate solution precipitates 10 mgr. of urea, the number used in the experiment multiplied by 10 gives the number of mgr. in 15 cc. of the filtrate, that is in 10 cc. of urine. But there is sodium chloride in the urine, and when this salt is

mixed with mercuric nitrate a double decomposition takes place; thus, until the quantity of sodium chloride present is exhausted, the mercuric nitrate is no longer available for precipitating the urea. Now the amount of sodium chloride in urine is tolerably constant; in each 10 cc. there is enough to act upon 2 cc. of the standard mercury solution. *Hence in reckoning the number of cubic centimetres of standard solution used, a deduction of 2 cc. must always be made.*

The method thus carried out is only approximately correct.

QUANTITATIVE ESTIMATION OF SUGAR.

13. Take the previously prepared standard solution of Fehling's fluid. This is of such a strength that 10 cc. are equivalent to .05 gm. of grape-sugar, *i. e.* 10 cc. contain just that amount of cupric oxide which .05 gm. of grape-sugar is capable of reducing to cuprous oxide: the cuprous oxide is precipitated, and the fluid is decolorized.

Take 10 cc. of diabetic urine, from which any albumin which may be present must be removed, and add to it 90 cc. of distilled water; place this in a burette.

Pour into a beaker exactly 10 cc. of the standard solution, dilute it with four or five times its bulk of distilled water, and boil.

Then run into it from the burette 40 cc. of the diluted urine, and boil again; let the precipitate settle, and look through the fluid at a sheet of white paper; if it is still blue, add another cc. from the burette and boil once more, and so on till the supernatant fluid

ceases to have a blue tinge; taking care, towards the end of the process, to add a few drops only, each time. If after adding the 40 cc. and boiling, the fluid is decolorized, too much urine has been added, and another 10 cc. of the standard solution must be measured out, running in, say 20, instead of 40 cc. of diluted urine.

Avoid delay in judging of the presence of the blue colour after each boiling; since on cooling the blue colour may partially return, and hence the amount of sugar present be estimated too highly. It is best to make two or three determinations; the first rapid and rough, the others more exact.

Suppose that the number of cc. of urine has been found which is just sufficient to decolorize the standard solution taken; that volume then contains just sufficient sugar to reduce the cupric oxide contained in 10 cc. of the standard solution to cuprous oxide; and we have seen that it requires .05 gm. of sugar to do this, therefore the number of cc. used contains .05 gm. of sugar, but of this one-tenth only was diabetic urine, therefore one-tenth of the number of cc. used gives the number of cc. of urine containing .05 gm. of sugar; from which the percentage can easily be calculated.

LESSON XXIII.

SKIN AND TOUCH.

SKIN.

1. Prepare vertical sections of human scalp which has been hardened by placing it in chromic acid .2 p. c. for a week. Stain the sections with picrocarmine, mount them in glycerine and observe
 - A. The **Epidermis**: proceeding from the outside will be seen
 - a. Cells without protoplasm, and apparently without a nucleus, very much flattened so that they present the appearance of a number of fibres. This is called the **horny layer**; in the stained sections it will be yellow.
 - b. Nucleated cells, more or less spheroidal in form. Some of these cells are frequently seen to be serrated or marked with ridges.
 - c. A row of columnar cells placed perpendicularly to the tissue beneath, and having no distinct cell-membrane. The spheroidal and the columnar cells together form the **Malpighian layer**.

B. The Dermis: in which may be seen

- a.* A thin layer of imperfectly differentiated connective tissue, the corpuscles of which are imbedded in an almost hyaline, very slightly fibrillated matrix. The upper portions of this form a kind of basement or limiting membrane immediately below the columnar epidermic cells. The lower portions pass gradually into
- b.* A fine meshwork of connective tissue, becoming coarser in the deeper parts, and there continuous with the subcutaneous connective tissue. The dermis is considered to cease with the appearance of fat-cells in the connective-tissue meshwork; but there is no definite line of demarcation, and in some places the deposit of fat does not occur.
- c.* Numerous elastic fibres, present both in *a* and *b*.
- d.* The **papillæ**: conical elevations, composed of *a* and *b*, rising up into the Malpighian layer, which therefore appears to dip down between them.
- e.* Indications of the blood-vessels, abundantly distributed all over the dermis, and forming capillary loops in the papillæ. These are better seen in injected specimens.
- f.* Nerve-fibres, for the most part becoming lost to view as they approach *a*. Some may be seen entering the papillæ.
- g.* **Hair-follicles** and the roots of hairs. Note
 - a.* The external sheath of the follicle formed of fibrous tissue continuous with that of

the dermis, but much denser in arrangement.

- β . The internal sheath of the follicle, consisting for the most part of indistinct transversely arranged fibres, amongst which oblong nuclei may be discerned.
- γ . A hyaline limiting membrane more marked than that of the dermis.
- δ . The external root-sheath, consisting of cells continuous with, and resembling those of the Malpighian layer.
- ϵ . The internal root-sheath, pale and transparent, passing into the horny layer of the epidermis. At the exit of the hair from the skin the horny layer dips down around it in the form of a cone.
- ζ . The papilla of the hair-follicle, consisting of connective tissue, with numerous cells, proceeding from the internal sheath of the follicle.
- h . The external root-sheath near the top has a diverticulum, which constitutes a **sebaceous gland**. There may be more than one. In the deeper part of the gland the cells become cubical.
- i . Below the base of the gland may be seen a band of plain muscular fibres, stretching obliquely from the inner sheath of the follicle to the upper part of the dermis.

2. Cut sections of the palm of the hand or of the forehead, hardened in chromic acid, picric acid, or alcohol, to observe the structure of the **sweat-glands**. Note
 - a. The terminal gland-knot in the subcutaneous tissue with its membrana propria continuous with that of the dermis, and lined by a single layer of cubical cells.
 - b. The gland-tube having columnar epithelium continuous with the cells of the Malpighian layer of the epidermis. In the epidermis the tube has no wall except that formed by the concentrically arranged epidermic cells; its course here is spiral.
3. Prepare the cornea of a frog as in Lesson v., B. § 4. Observe
 - a. A meshwork of nerves, without medulla, but with primitive sheath recognized by its nuclei and perineurium. This forms the **primary nerve-plexus**, it is at a slightly deeper level than
 - b. A meshwork of nerves with much closer meshes, consisting of fine axis-cylinders, without a primitive sheath, but having numerous varicosities in their course. This forms the **sub-epithelial nerve-plexus**.
4. Cut out the cornea of a recently killed rabbit, taking care not to drag it, and place it in gold chloride for an hour. Wash well and expose to light as usual, but do not pencil it. When it is well stained, if necessary harden with alcohol, imbed a piece of it vertically in paraffin, and cut sections as thin as possible. Observe

The primary nerve-plexus in the connective tissue, giving off branches which divide and form the sub-epithelial nerve-plexus, immediately underneath the epithelium; from this very fine fibrils are given off, which, penetrating between the epithelial cells, form there the **epithelial plexus**.

This may be considered as the type of nerve-termination in those parts of the skin where there are no special terminal organs.

5. Cut sections of the tips of fingers which have been kept in potassium bichromate 1 p. c. for a day, to observe special nerve-endings:

A. Touch-corpuses. Note that

- a. They are oval in form, and are found in the axes of the papillæ; many papillæ are without them, in which case a blood-vessel may generally be seen running up into the papilla.
- b. They appear to consist of a transparent matrix in which nuclei are disposed transversely.
- c. The medullated nerve-fibre enters near the base, and may be traced coiling round it spirally for a variable distance.

To observe the course of the nerve-fibre satisfactorily, a small piece of fresh skin from the tip of a finger should be placed in osmic acid 1 p. c. for about twelve hours till it is black, and then treated with alcohol as usual. The dark nerve-fibres can be distinctly seen entering the touch-corpuses; and occasionally in papillæ without these bodies, one or more nerve-fibres may be seen running up the papilla as far as the Malpighian layer of the epidermis; its

further course amongst the cells will probably not be made out in these preparations. Osmic acid specimens, after they have been well washed, may be mounted in dilute glycerine, or in a saturated solution of acetate of potash, or after clearing, in Canada balsam.

B. Pacinian bodies. These occur in the subcutaneous tissue; but their structure can be more readily studied in the mesentery of a cat, in which they appear as transparent oval bodies generally surrounded with fat. Cut out one of these, and mount it in normal saline solution. Observe

- a.* The twisting medullated nerve-fibre and the thickening of its connective-tissue sheath as it approaches the Pacinian body.
- b.* The division of the connective-tissue sheath to form the numerous concentric capsules, becoming closer together towards the centre.
- c.* The loss of medulla as the sheath splits up.
- d.* The colloid body inside the inner capsule.
- e.* The axis-cylinder penetrating the colloid body, and ending in it in a slight enlargement.

TOUCH.

1. Power of localisation.

Using a pair of small bone or wooden compasses, determine the distance at which the points must be placed from each other in order that they may be felt as two points when applied lightly and with the same force to various parts of the body. Try if the following order is correct: tip of tongue, tips of fingers, palm of hand, cheeks, back of hand, fore-head, front of fore-arm, back of fore-arm, back of neck, &c.

2. Sensation of temperature.

Dip a small metallic knob in hot water (*e. g.* 70° C.), and applying it to the same parts of the body as before, determine roughly the sensitiveness to temperature of these parts.

3. Estimation of weight. The muscular sense.

a. Determine the smallest difference in weight which can be appreciated when slightly differing weights are held in the palm of the hand.

b. Then laying the hand and arm supine on a table, so that they are motionless, and placing weights on the palm of hand, determine as before the difference of weight which can be appreciated. This will be much less in the case of (*b*) than of (*a*). In (*a*) the muscular sense is employed; in (*b*), only the sensation of pressure. The weight should be placed on the same part of the palm of the hand in each case.

4. Estimate (in either way) the difference of weight which can be appreciated

a. When the weights are light, *e. g.* 1, 2, 3, 4, or 5 grms.

β. When the weights are heavy, *e. g.* 10, 20, 30, &c., or 100, 200, &c. grms.

Smaller differences will be appreciated in *α* than in *β*. In fact the difference of weight which can be appreciated bears, roughly speaking, a constant ratio to the whole weight.

5. Plunge the finger into mercury, and then draw it out. The sensation will be that of a ring passing down and

up the finger, the greatest sensation being where there is the greatest variation of pressure.

6. Place two equal light weights, one cold the other warm, on the corresponding fingers of the hands; the cold one will feel the heavier.
7. Paint a ring of collodion on the palm of the hand, leaving only a small central space, and attempt to distinguish between the approach of a hot body and gentle contact of a feather.
8. Place the elbow first in warm water, and then in a mixture of ice and water. There will be a sensation of pain in the fingers and cold in the elbow. The application of cold to the *trunk* of a nerve does not cause a sensation of cold.

9. **Tactile delusions.**

Cross the second finger over the first or the third over the second, and place between their tips a small marble (or any solid round body a little larger than a pea) so that it touches the radial side of the first, and the ulnar side of the second finger-tip. On gently rolling the body about, a sensation as if of two distinct bodies will be felt.

The same delusion is experienced if the tip of the nose be gently rubbed with the tips of the fingers so placed.

Experiments 6 and 7 will need the assistance of a second person,

LESSON XXIV.

OLFACTORY AND GUSTATORY ORGANS.

1. Lay bare the olfactory chambers of a newt, and place them in osmic acid 1 p.c. for 24 hours. Tease out in water a small piece of the mucous membrane. Or place in Müller's fluid for a week or more, and tease out in the same fluid or in water. Observe
 - a. The **cylindrical epithelium cell**, its large oval nucleus, its broad, clear, peripheral process, and its branching, faintly granular, central process.
 - b. The **rod-cell**, with its spherical nucleus, its hyaline slender peripheral, and its still more slender varicose and branching central process.
 - c. Groups of the nuclei of *b*, forming the nuclear layer (2 B. *b*) lying in the meshes of a reticulate slightly granular protoplasm.
 - d. Cylindrical cells will frequently be seen, surrounded and partially hidden by numerous rod-cells.
2. Remove the lower jaw from the head of a newt, cut off the nose by an incision carried just in front of the eyes. Place it in chromic acid .5 p. c. for three days. Imbed it vertically, and cut transverse sections,

until the olfactory chambers are reached. These may be at once recognised by their peculiar epithelium. Stain with carmine or hæmatoxylin. Observe that

- A. In the non-olfactory portion of the mucous membrane
 - a. The surface-epithelium is cylindrical and ciliated, with the exception of a certain number of goblet-cells.
 - b. Below the ciliated cells there is a single row of small spherical granular nucleated cells.

- B. In the olfactory part of the mucous membrane the division of the epithelium into an outer and an inner layer.
 - a. The outer layer consisting of the peripheral processes of both cylindrical and rod-cells.
 - b. The inner or nuclear layer consisting of several rows of nuclei belonging to the rod-cells. The nuclei of the cylindrical cells form a single row in the upper part of this layer, but these, as well as the processes of the lower rod-cells, are generally hidden by the nuclei of the rod-cells. In parts of the section where the nuclei have fallen away the branched central processes of the cylindrical cells may be seen to form an irregular meshwork.
 - c. Beneath the epithelium will be seen fine connective tissue, in which lie cut bundles of plain non-medullated nerve-fibres.

A great number of simple serous and mucous glands will be seen beneath the mucous membrane both of A and B.

3. From a rabbit's tongue which has been hardened in chromic acid .2 p. c., or potassium bichromate 1 p. c., excise a papilla foliata and imbed in such a way that the sections will be at right angles to the ridges. The papilla will easily be recognized as an oval patch strongly marked with ridges, about 3 or 4 mm. in its longest diameter, at the side of the back of the tongue.

Prepare thin vertical sections and observe

- a. The section of the ridges with the intervening fossæ.
- b. In each ridge three papilliform processes of the dermis, one median, two lateral.
- c. The horny epidermis, consisting of cells very flattened, but still retaining their nuclei, covering the ridges and lining the fossæ.
- d. The Malpighian layer of the epidermis underneath the horny layer in the above situations, and also filling up the hollows between the lateral and median papillæ of the ridges. (Cf. *c* and *d* with Skin Lesson XXIII.).
- e. On the outside of each lateral papilla, and therefore lining each side of the fossa, the row of **taste-bulbs**.
- f. Each bulb reaching from the dermis of the papilla to the free surface of the horny layer lining the fossa, where its circular open mouth may be often seen.
- g. The imbricated epidermic cells forming the nest of the bulb.

- h.* The bulb itself, with
 - α.* The external **cover-cells**, granular, fusiform and flattened, with conspicuous oval nuclei.
 - β.* The **rod-cells**, with spherical nucleus, rod-shaped hyaline peripheral and central processes. These will be better seen on teasing out a section.
 - i.* Nerve-fibres running along the dermis of the papillæ, and branching off to the bulbs.
4. Tease out a small piece of a papilla foliata which has been placed in osmic acid 1 p. c. for one to two days, and observe the characters of the cells of the taste-bulbs.

SENSE OF TASTE AND SMELL.

1. Pinching the nose tightly, so as to suspend the sense of smell, attempt with the eyes shut to distinguish by taste between pieces of an apple, an onion, and a potato of similar consistency. They will taste alike; hence the so-called taste of an onion is an excitement of the sense of smell.
2. Wipe the tongue quite dry, and place on the tip a crystal of sugar or on the back a crystal of quinine; neither will be tasted until they are dissolved.
3. Apply with pointed, non-polarizable (Hdb. p. 345) electrodes a constant current to the tongue; a distinct sensation of taste will be felt, of acidity at the anode, of alkalinity at the kathode.

Keeping the electrodes at the same distance, say two or three millimetres, determine the amount of taste-

sensation in different parts of the mouth. It will be greatest at the tip and back (region of circumvallate papillæ) of the tongue, and edges of the tongue; least or absent in the anterior and middle surface, under surface of the tongue, and lips. The soft palate will be found to be highly sensitive, the hard palate little or not at all.

4. Take two pieces of sugar of equal size, and place one on the tip, and the other on the back of the tongue; the sensation will be most acute at the tip.
5. Place a drop of quinine solution on the tip of the tongue; it will hardly be tasted. Place it on the back; it will be tasted at once.

LESSON XXV.

THE EYE.

A. DISSECTION.

1. Take a fresh eye of an ox or sheep, and note
 - a. The transparent **cornea**.
 - b. Surrounding and continuous with this, the dirty-white **sclerotic** which forms the outer coat of the rest of the eye. The posterior two-thirds will probably be covered with fat.
 - c. The **conjunctiva**, a continuation of the mucous membrane of the eyelids. In taking the eye out of the orbit this membrane is cut through where it passes from the eyelids to the sclerotic. Dissect it forwards in any one place; it will be traceable to the junction of the sclerotic and the cornea. The epithelium is continuous over the cornea, forming the *conjunctiva corneæ* (cp. B. a.).
2. Clear away the fat surrounding the four straight muscles, it will be seen that their tendons form a layer under the conjunctiva of the sclerotic.
3. Cut away the conjunctiva and muscles, and remove the fat around the **optic nerve**; this pierces the sclerotic on one side, and not in the axis of the eye.

4. Cut through the cornea close to its junction with the sclerotic; the anterior chamber of the eye, containing clear, limpid **aqueous humour**, is thus laid bare. Observe the iris with its central aperture through which projects the anterior part of the lens.
5. At a little distance from the cornea, cut through the sclerotic, being careful not to cut too deeply; it will separate easily from the pigmented subjacent **choroid**, except at the junction of the sclerotic with the cornea, and at the entrance of the optic nerve. In other places there is only a loose connection, chiefly by means of blood-vessels. Remove a strip of a few mm. breadth between the optic nerve and the cornea. Note its dark inner surface, or **lamina fusca**; note also in the front part of the choroid, close to the cornea, the pale fibres of the **ciliary muscle** spreading from the junction of the sclerotic and cornea, backwards over the choroid.
6. Carefully pinch up the choroid about half-way between the optic nerve and the cornea with a fine pair of forceps, and snip it through. Underneath it will be seen a thin membrane, the **retina**.
7. Tear away the retina to expose the clear **vitreous humour** which occupies the posterior cavity of the eye.
8. Tilt the eye so that the cornea is underneath; through the vitreous humour can be seen the choroid coat becoming folded longitudinally as it approaches the lens, and so forming the **ciliary processes**.

The nervous elements of the retina cease at the level of the commencement of the ciliary process. Their termination is marked by an uneven line, the **ora serrata**.

9. Holding up the choroid and retina, cut them through as far forward as the ora serrata; it will be seen that the vitreous humour separates readily from the retina as far as that line, but in the region beyond becomes more firmly attached to the ciliary processes. If an attempt be made to separate them here with the handle of a scalpel, it will be found that the pars ciliaris retinæ (or the non-nervous continuation of the retina in front of the ora serrata) together with some of the pigment layer of the choroid will come away with the vitreous humour.
The so-called hyaloid membrane is the outermost layer of the vitreous humour, and is said to consist of fine fibres fused together. At the ora serrata it becomes united to the membrana limitans interna of the retina.
10. Turn the eye with the front uppermost, and cut away the free edge of the iris; make two incisions at right angles to one another on the surface of the lens, it will be seen that the lens is covered by a membrane; this is the anterior part of the **lens capsule**. Carefully remove the lens, and trace out the limits of the lens capsule, noting that it forms a complete investment for the lens.
11. Gently separate with the handle of a scalpel the lens capsule from the front part of the ciliary processes, and observe that a membrane, the **suspensory ligament** or **zone of Zinn**, passes from the edge of the capsule to the ciliary processes, of which it forms the innermost layer, dipping down into their depressions. On tracing it backwards it will be found to be continuous with the membrane spoken of above as adherent to the vitreous humour.

12. Looking into the eye from the front, observe
 - a. The entrance of the optic nerve.
 - b. The blood-vessels running in the retina and radiating out from the entrance of the optic nerve.
 - c. The iridescence, mainly below the entrance of the optic nerve, caused by the irregular reflection of light from the wavy course of the connective-tissue fibres of the choroid. The hexagonal cells of the retina have here no pigment.

13. Separate the rest of the retina from the choroid, and observe that
 - a. The pigment-layer generally adheres rather to the choroid than to the retina.
 - b. Apart from the pigment-layer the retina appears like an expansion of the optic nerve.
 - c. The retina is firmly attached to the choroid at the ora serrata.

14. Take the eye of a rabbit which has been preserved in potassium bichromate 1 p. c., and imbed in spermaceti and castor oil a piece containing the junction of the sclerotic, cornea, and iris. Cut transverse sections so that the arrangement of the several parts can be seen. Observe
 - a. The membrane of Descemet (cf. B. c.) splitting up at the junction of the cornea and sclerotic into fine transparent bundles, some of which curve round towards the iris, the others spreading out fan-like a short distance into the ciliary process and sclerotic. These bundles of fibres form the **ligamentum pectinatum iridis**.

- b.* The **ciliary muscle**; consisting of bands of unstriped muscle, radiating from the angle of the iris and cornea;
- (c.* The circular muscle of Müller may be seen as the cross section of a bundle of fibres lying to the inside of *b*, in the eye of man and of some other animals, but it is absent in the rabbit.)
- d.* The pigment-layer of the choroid continuing over the ciliary processes to form the uvea of the iris.
- e.* The canal of Schlemm (venous sinus) at the junction of the cornea and sclerotic.

B. HISTOLOGY.

Cornea. Prepare the cornea of a frog or a rabbit as in Lesson XXIII. § 4. Divide it into two pieces.

1. Imbed one piece so as to give vertical sections; in these observe
 - a.* The anterior epithelium, or conjunctiva cornea.
In this note
 - a.* The external flattened nucleated cells.
 - β.* The middle layers of roundish but irregular cells.
 - γ.* The internal single layer of columnar cells placed perpendicularly.
 - b.* The body of the cornea. Note
 - a.* The narrow transparent zone immediately beneath the epithelium with very few and small cells.
 - β.* The rows of connective-tissue corpuscles seen in profile, with numerous branches communi-

cating not only with the cells in the same row, but also with those below and above.

- γ. The fibrous laminae between which, for the most part, the cells are placed.
- c. The **membrane of Descemet** or Demours: a thick hyaline membrane, with very sharp outlines.
- d. The posterior epithelium, consisting of a single layer of large nucleated tessellated cells. In this section they are seen in profile, covering the membrane of Descemet.

2. Imbed the other piece to give horizontal sections, and observe

The branched cornea-corpuscles seen *en face*. (Cf. Lesson v. B. § 2.)

Mount the sections in glycerine. They will in time become darker, and their structure become much more evident.

Lens.

1. Place the lens of a rabbit or rat in osmic acid .25 p. c. for about three hours; it will swell up somewhat, and the outer coat becomes jelly-like and easily torn; to obviate this, place it in gold chloride .25 p. c. for a minute or less; then tear off as long a strip as possible of the outer coat, and tease out in water. Observe the long band-like fibres with serrated edges usually adhering together in layers but in some cases isolated.

In some of the fibres a nucleus; when the fibres form a layer, the nuclei appear as a scattered band running across it.

2. Cut vertical sections through the centre of the lens of rabbit which has been preserved in Müller's fluid

two or three weeks, and mount in glycerine. Spirit must not be used to moisten the razor. In these note the direction of the fibres, and the position of their nuclei.

Iris.

1. Cut out a piece of an iris from an eye which has been preserved in potassium bichromate, and imbed it so as to cut radial vertical sections. Observe
 - a. On the posterior surface the **uvea** or thick layer of pigment epithelium-cells. The pigment is too abundant to allow the outlines of the individual cells to be seen.
 - b. The cross sections of the bundles of plain muscular fibres forming the **sphincter pupillæ** near the edge of the pupil, and lying just above the pigment-layer.
 - c. The body of the iris, consisting of blood-vessels united together by a loose connective tissue in which branched pigment-cells are conspicuous. Near the anterior surface is a denser layer, the so-called anterior limiting membrane. The radial muscular fibres (dilatator) may (with difficulty) be seen near the posterior surface.
2. Take the iris from the eye of an albino rabbit or white rat which has been preserved in Müller's fluid. Cut out a piece from the free edge to the attachment, stain with hæmatoxylin, clear, and mount in Canada balsam with the posterior surface uppermost. Observe the arrangement of the sphincter and dilatator muscles,

Retina.

1. Cut away the anterior half of the eye of a mammal immediately after death: avoid dragging the vitreous humour that the retina may not be displaced. Place the posterior half in potassium bichromate for a week, frequently changing the fluid. Remove the retina carefully, carrying with it if possible the pigment-layer, and treat with alcohol. Stain a small piece with hæmatoxylin, imbed it in spermaceti and castor oil, clear the sections, and mount them in dammar.
2. Imbed an unstained piece, and mount the sections in glycerine.
3. Remove the retina from an eye still warm to osmic acid. After 6 hours, treat with alcohol. Imbed and mount the sections in glycerine

In all cases take a small fragment 2 or 3 mm. square for making sections. If long vertical sections are made they are very apt to turn over.

In one or other, observe the following structures from within (anterior surface) to without (posterior surface).

- a. The **inner limiting membrane**; from this the **fibres of Müller** are seen to start with a broad conical foot and to run vertically outwards; they may readily be traced as far as *f*.
- b. The **layer of optic fibres**. The nerve-fibres here are without medullary sheaths, or rarely possess them.
- c. The **ganglionic layer**; this consists of large multipolar cells with conspicuous nuclei.

- d.* The **molecular layer**, finely granular and opaque in appearance.
 - e.* The **inner nuclear layer**, consisting of two or three rows of somewhat large, spherical or oval nuclei with nucleoli.
 - f.* The **fenestrated membrane**.
 - g.* The **outer nuclear layer**. In this the nuclei are spherical or oval, smaller but more numerous than *c*.
 - h.* The **outer limiting membrane**, seen as a sharp well-defined line.
 - i.* The **layer of rods and cones**. Both limbs of the more numerous rods may be easily seen; the cones are recognized with difficulty.
 - k.* The **pigment of the choroid** with the fine pencil of processes enveloping the outer limbs of the rods and cones.
3. Tear off a small piece of the retina from the eye of a sheep; probably the pigment layer of the retina will be left adhering to the choroid. Take a small piece of this pigment-layer, and mount it in glycerine. Observe *en face* the single layer of hexagonal cells with large pigment-granules. (See also § 5.)
4. Tease out in water the small piece of the retina of a mammal treated with osmic acid for 24 hours. Observe
- a.* The isolated rods and cones, their broken, laminated, and often curled outer limbs.
 - b.* Loose nuclei, belonging to the inner or outer nuclear layer.

- c.* Isolated nerve-fibres and ganglionic cells.
- d.* Portions of the membrane shewing the fibres of Müller projecting, or fragments of the molecular layer with its reticulum of connective tissue.

Very excellent vertical sections may frequently be found in thus teasing out osmic acid specimens.

- 5. Remove the retina of a frog immediately after death, and place it in osmic acid for 30 minutes to 24 hours, as convenient; tease out in water. Observe especially
 - a.* The large outer limbs of the rods, their striation and transverse lamination.
 - b.* The pigment-cells, each consisting of a colourless outer part, containing the nucleus, and a coarsely pigmented part, which splits up into a number of fibres, amongst which are imbedded the heads of the rods.

LESSON XXVI.

VISION.

Accommodation.

1. Remove very carefully the sclerotic and choroid from a small portion of the posterior surface of the eye of an ox or a sheep. Place the eye in the end of a blackened tube just large enough to hold it, with the cornea outwards.

On looking through the tube at any object, the inverted image will be seen shining through the retina.

Or,

The eye of any small animal, *e. g.* rat, may be used without any preparation, the sclerotic being sufficiently thin to be transparent. It will be found convenient to place the eye, with the cornea downwards, on the stage of a microscope, and to direct light through it by means of the mirror.

2. Standing some feet before a window, close one eye and hold up before the other, at a distance of about six inches, a needle, so that it is at right angles to one of the horizontal bars of the window.

Look at the window-bar, the needle will appear dim and diffuse.

Look at the needle, the window-bar will appear dim and diffuse.

The eye can accommodate itself for either the needle or the window-bar, but not for both at the same time. The accommodation for the near object is accompanied by a distinct feeling of effort.

3. Facing a window, or a white surface, close one eye and hold a fine needle vertically before the other. At about six inches the needle will be seen distinctly. Bring it nearer the eye, the image will be dim and diffuse, and at the same time larger. The dimness and apparent increase of size are due to **diffusion**, resulting from imperfect accommodation.

Prick a small clean hole in a piece of card, hold it before the eye and again bring the needle close to the eye. It will be seen distinctly at a much smaller distance than before, and at the same time will appear magnified. It will seem larger because the rays, after passing through the aperture, diverge, and so produce a larger image on the retina. Construct a figure to shew this. It will be seen more distinctly because the diffusion circles are cut off.

For a similar reason an object at a distance viewed through the same hole will appear smaller when the eye is accommodated for a nearer object.

4. Prick in a card two small holes close together, so that both are within the diameter of the pupil. Holding the card before one eye (the other being closed) with the holes horizontal, hold a fine needle vertically at a distance of twelve inches. It will be seen distinctly as one when the eye is accommodated for it, but double when accommodation is made either for farther or

nearer objects. Both the double images will be dimmer than the single one.

When a double image appears and

- a.* The eye is adjusted for far objects; stopping the right-hand hole will make the left-hand image disappear.
- b.* The eye is adjusted for near objects; stopping the right-hand hole will make the right-hand image disappear.

When the eye is exactly accommodated for the object, the rays passing through the two holes are united at the focus on the retina.

In *a*, the rays fall upon the retina before they are so united, and from the inversion of images on the retina, the actual disappearance of the right-hand image is referred to the left-hand side.

In *b*, the rays are united, and cross at the focus before they fall on the retina. Stopping the right-hand hole removes the image on the left-hand side of the retina; and the disappearance is referred to the right-hand side. Construct a figure to shew this.

When a single image is seen, stopping either hole merely makes the field of vision appear dim.

This is called **Scheiner's experiment**.

5. The image being one, bring the needle closer to the eye; at a certain distance it will become double; this marks the *near* limit of accommodation.

Fixing the needle on a sheet of paper, walk away while looking at it through the two holes; at a certain distance it will become double, this marks the *far*

limit of accommodation. This experiment succeeds best with short-sighted people.

Compare the near and far limits of accommodation as fixed by looking at a vertical needle through horizontal holes with those fixed by looking at a horizontal needle through holes placed vertically. The results will differ according to the amount of astigmatism in the eye.

6. **Helmholtz's Phakoscope.** This should be used in a dark room. The observed looks with one eye through the hole opposite the needle. The observer looks through the hole at the side. A lamp or candle is placed at some little distance from the prisms and shifted about until the observer sees on the eye of the observed, when the latter looks at a distant object, two small bright patches of light on the cornea, two larger but dimmer patches on the anterior surface of the lens, and two small and very dim (not readily seen) patches on the posterior surface of the lens.

Let the observed now accommodate for the needle in front of him, making every effort not to move the eyeball. The observer will see the two patches on the anterior surface of the lens approach each other, while the other two pair remain motionless, thus shewing that during accommodation for near objects the *anterior surface* of the lens becomes more convex.

Observe that in accommodating for near objects the pupil becomes smaller, and in accommodating for far objects the pupil becomes larger.

7. **Astigmatism.** Hold before the eye a card marked with a number of parallel horizontal and vertical lines, and gradually bring the card near to the eye. At a

certain distance both vertical and horizontal lines will appear dim and diffuse, the near limits of accommodation for both having been passed. With care however (with most eyes) a distance may be found at which the horizontal lines are still sharp and well-defined, the vertical are already dim and diffuse, the near limit of horizontal accommodation being nearer than that of vertical accommodation.

A similar experiment, especially by short-sighted people, may be tried for the far limit.

Or,

Fix a needle vertically on a board. Looking at the needle with one eye, accommodate the eye exactly for it. Then hold another needle horizontally before the first, and move it backwards and forwards until both needles are seen distinctly at the same time. This will be found to be the case when the needles are at some distance apart.

More exact results are however gained by Scheiner's method (§ 4).

8. Irradiation.

Cut out two patches of exactly the same size, of white and of black paper.

Place the white on a sheet of black and the black on a sheet of white paper.

Place them some distance off and adjust the eye so as to throw them a little out of the range of accommodation.

The white patch will appear larger than the black one.

9. Blind Spot.

Make a bold mark on a sheet of white paper, place the sheet on the table, and, closing the left eye, fix the axis of vision of the other, by steadfastly looking at the mark at a distance of about 10 inches. Dip a new quill-pen in black ink and place it close to the paper near the mark. Keeping the axis of vision fixed, and the head at the same distance from the table, move the pen outwards (towards the right) from the mark. At a certain distance it will become invisible; mark this spot on the paper. Carry the pen still farther outwards. It will again come visible; mark this spot also. The two spots will indicate the outer and inner limits of the blind spot. Similarly the upper and lower limits may be traced, and with a little practice an outline of the blind spot, shewing even the commencement of the retinal blood-vessels as they emerge from the edge of the optic disc, may be constructed.

The size of the blind spot may be calculated from the formula $\frac{f}{F} = \frac{d}{D}$, where f is the distance of the eye from the paper, F the distance of the retina from the nodal point of the eye (average = 15 mm.), d the diameter of the outline on the paper, and D the outline of the blind spot.

10. Region of Distinct Vision.

Fix the axis of vision by steadfastly looking at some mark. Make on a card two dots so close that they can just be seen as two when placed close to the mark. Keeping the axis fixed, move the card towards the periphery of the field of vision; the dots will soon appear as one.

Or,

Make two dots on a card .5 mm. from each other. Fix the axis of vision. Place the card outside the whole field of vision and gradually move it inwards towards the mark; the dots will first become visible as one, and only appear as two as they approach the centre of the field, and enter the region of distinct vision.

It will be found on examination that the outline of this region is not circular but very irregular.

11. Purkinje's Figures.

Go into a dark room with a lighted candle: looking steadfastly with one eye towards a wall¹, hold the candle to the side of that eye so that while the eye is illuminated the image of the candle is not seen, and gently move the candle up and down. In a few seconds the subdued reddish glare caused by the candle-light will be marked by branching dark lines, which will be seen to form an exact image of the retinal vessels as seen with the ophthalmoscope. The dark lines are shadows of the blood-vessels, consequently the structures in which the physiological processes which give rise to the sensation of light begin must lie behind the retinal blood-vessels.

A round space, in which the blood-vessels are absent, may with care be seen; this is the yellow spot.

Or,

Turn the eye inwards towards the nose so as to expose as much as possible of the thin sclerotic

¹ A light-coloured wall or white blind is the best. A wall, the paper of which has any very marked pattern, should be avoided.

behind the cornea. Let an assistant with a lens concentrate the rays of direct sunlight or of a candle or lamp on the sclerotic as far behind the cornea as possible, so that the rays may pass directly through it towards the opposite side of the eye, and gently move the focus to and fro. The same image is still more distinctly seen. The smaller the focus on the sclerotic, the more distinct the image.

If the movement of the light is stopped, the image soon fades away.

In the first method the image moves in the same direction as the light when the light is moved from side to side, but in an opposite direction when moved up and down.

In the second method the movement of the image is in the same direction as that of the light, whether up and down or from side to side.

12. Look through a microscope with an empty field, illuminated, but not too brightly, by a white cloud, and gently move the head to and fro; an appearance of fine retinal capillaries will be seen as a dark meshwork on a finely punctated ground. In the centre may be seen a spot devoid of capillaries but still finely punctated. If the head be moved from side to side, the vertical meshwork will be seen; if up and down, the horizontal meshwork.

13. **The Yellow Spot. Maxwell's Method.**

Place a moderately strong, but perfectly transparent solution of chrome alum in a flat-sided glass vessel. Resting the eye for a minute or two, suddenly look through the vessel at a white cloud. A rosy spot

or cloud will appear in the centre of vision and remain for some little time, but will gradually become less distinct.

The pigment of the yellow spot absorbs the blue-green rays between the lines *E* and *F* of the spectrum, these rays removed from those passing through the chrome alum, viz. red and greenish blue, leave a rose colour.

14. Region of normal colour-vision.

Take small pieces of paper of various colours (about 10 mm. square). Fix the axis of vision, on a sheet of white paper, and place each of the coloured papers near the axis of vision, they will all be distinct.

Place a red piece near the axis, and then gradually move it towards the outside of the field of vision; the redness will vanish and it will appear to be black.

It will be found that passing from the centre towards the periphery, red is the first to disappear, next green, and lastly blue. Hence purple becomes violet and then blue, and rose bluish-white, before disappearing.

15. Positive After-Image.

When waking in the morning, close and shade the eyes for a minute or two, then suddenly look at the bright window for a moment or two, and then close and shade the eyes again. The image of the window exactly corresponding to the natural one, *i.e.* with the sashes dark and the panes bright, &c., will last for some little time.

To succeed, the retina should be in rest beforehand, and the exposure to the stimulus momentary or nearly so.

Or, in the evening, having closed and shaded the eyes, suddenly look at a lamp and immediately close the eyes. A similar positive after-image will be seen.

This positive after-image must not be confounded with the negative after-image which comes later. It simply shews that the sensation is of longer duration than the application of the stimulus.

16. Look for an instant at a coloured light, and then look at a white or grey surface, a positive image *of the same colour* will for a brief period be visible.

17. Negative After-Image.

Look fixedly for some time with one eye

- a. At a white patch (*e.g.* white wafer) on a black ground, and then look at a white surface; there will be visible a corresponding dark patch on the white ground.
- b. At a black patch on a white ground, and turn to a grey surface; there will be visible a white patch on a grey ground.
- c. At a red patch on a white, grey, or black ground, and turn to a white surface; there will be visible a green patch.

And so with the other colours, the colour of the negative image will be complementary to that of the actual object.

- d. Look fixedly at a brightly illuminated window and then close the eye. The *positive* after-image will probably not be seen; in its place

there will come the *negative* after-image with the sashes as bright lines and the panes as dark spaces. This will in turn be succeeded by coloured images.

18. Simultaneous Contrast.

- a. Cut out a small piece of grey paper about the size of a shilling, and place it in the middle of a sheet of bright green paper. Cover the whole with a sheet of thin tissue paper. The grey patch will appear pink. The exact tint of the patch will depend on the tint of the green, of which it will be the complementary colour.

Surround the grey patch with a broad dark black rim. The effect of contrast will be lost; the grey patch will appear grey.

On a red ground the grey patch will appear green, and with the other colours similar complementary effects will be produced; but the results are most striking in the case of red and green.

The effect is greatest when the patch is grey, not white, and is always heightened by covering with tissue paper.

- b. Cut a thin strip of grey paper and place it across the junction of a red with a green paper, and cover with tissue paper.

The grey will appear green on the red side and pink on the green side.

- c. Place a sheet of white paper on a table before a window illuminated by reflection from a white

cloud, not with direct sunlight. On the side of the paper opposite the window place a lighted candle, and between it and the paper place a book edge-ways, or any object which will throw a shadow on the paper. Between the paper and the window place a similar object, throwing a like shadow. The distance of the candle should be such that the two shadows are of nearly equal intensity.

The shadow from the candle, though illuminated by the white sunlight, will appear blue, the complement of the reddish yellow colour of the rest of the paper illuminated by the candle.

This effect of contrast is subjective, not objective. To shew this, blow out or place a screen before the candle so as to do away with the candle-light. The place formerly occupied by the shadow now appears white. Through a small black tube, *e.g.* a piece of black paper rolled up, with so small a bore that the whole field of view lies within the shadow, look at the centre of the area formerly occupied by the shadow. It still of course appears white. While looking, let some one light the candle, or remove the screen. No change will be visible to the observer looking through the tube.

If the tube however be directed partly on the area of the shadow, and partly outside, the blue tint of the shadow will, on the candle being lighted or the screen removed, become apparent as before.

The daylight-shadow heightens the effect on the candle shadow, but may be dispensed with.

In place of sunlight and candle, two coloured lights may be used.

In the above experiments (§§ *a*, *b*, *c*) avoid looking at the colours too fixedly and for too long a time. Otherwise the results will be modified by after-images.

LESSON XXVII.

THE EAR.

A. SKATE.

1. Cut through with a strong sharp scalpel or with bone forceps the cartilaginous roof of the skull transversely between the eyes; remove the posterior part of the roof. Opposite the hinder part of the brain the cartilage will be seen to be much thicker than elsewhere; it contains the vestibule and semicircular canals: slice it away till one of the semicircular canals is reached; when this is done, trace it, removing the upper portion with scissors or bone forceps.

Note

- a.* The almost transparent **membranous canal** much smaller than the cartilaginous canal in which it lies.
- b.* The **ampulla** or spindle-shaped dilatation of the membranous canal close to one end.
- c.* The opening of the semicircular canal at either end into a large membranous bag, the **utricle**.

place it in absolute alcohol for half an hour, imbed it carefully in vaseline mixture, and cut transverse sections using olive oil to moisten the razor; transfer the section to a glass slide, sop up with blotting-paper as much of the oil as possible, and clear on the slide with carbolic acid and turpentine; mount in Canada balsam.

In sections through the crista acustica observe

- a. The outer loose connective tissue, and
- b. The thick connective tissue wall or membrana propria.
- c. The numerous large nerve fibres with blackened medulla running from the outside towards this; the fibres may be traced through the membrane losing their medulla and becoming much smaller.
- c. Two or more layers of **cells with large nuclei**; long processes may be seen to proceed upwards from some of these.
- d. Superficial **columnar cells**.
- e. Fine **fibres** projecting beyond the columnar cells; if care has not been taken these will have been broken off; in any case it will be difficult to make out whether the processes run between the cells or from their extremities.

In sections through any other part of the ampulla observe,

- a. The thinner membrana propria,
- b. The single layer of short columnar or even flattened cells.

6. At the lower part of the utriculus and sacculus note the white calcareous paste, lift up the membranous bag and note that beneath the paste, nerve fibres enter through the cartilage. Remove the remainder of the membranous vestibule and canals, sop up any fluid with a sponge and moisten the cartilaginous vestibule and canals with osmic acid; in a short time the nerve fibres entering through the cartilage become blackened and so very distinct.
7. Trace towards the brain, cutting through the cartilage, one of the nerve bundles, *e.g.* that entering the utriculus.

B. MAMMAL.

1. Take the head of a cat¹, and cut away all the soft tissues surrounding the tympanic bulla, having snipped off the external meatus as close to the skull as possible, look down and observe the **tympanic membrane**; it is placed obliquely to the canal and faces forwards, outwards, and downwards. The attached handle of the malleus may be seen shining through it.
2. Place the head with the lower jaw uppermost, and with a strong pair of forceps break away piecemeal the projecting part of the bulla. The cavity thus exposed has a floor² made irregular by projections.

¹ The details of arrangement differ considerably in different animals: the following description applies to the cat, the more general features may however be made out in other mammals.

² It must be particularly noticed that the words floor, roof, exterior, posterior, etc. are here used with reference to the position of the head *during the dissection*; the position of the parts when the head is placed in the normal position should also be observed.

Note in the centre a projection of somewhat yellowish bone running in the long axis of the bulla; this is the **protuberance** of the **cochlea**: at a lower level in the exterior and posterior part of it will be seen a round depression, the **foramen rotundum**.

3. In front and outside the cochlea is a projection of thin bone which prevents the membrana tympani from being seen; it divides the tympanic cavity into two parts communicating by an aperture over the foramen rotundum; this arrangement is a characteristic of the Felidæ; break through the bone from above and very carefully remove it in pieces with forceps.

The rest of the cavity of the tympanum is thus exposed. Note the funnel shape of the membrana tympani; it has the handle of the malleus attached to it; this proceeds from the outside attachment of the membrane slightly upwards to a little past the middle point of the membrane (cf. Foot-Notes, p. 204).

4. Running out from a bony rim behind the membrana tympani in the outer part, will be seen a band of tissue stretching to the outer, anterior edge of the bony rim surrounding the foramen rotundum; from this a thin ligament proceeds at right angles to the former band to be inserted into the head of the malleus. This is the **posterior ligament** of the **malleus**.
5. On the opposite side to the head of the malleus and in the same straight line, note the **processus gracilis** running down to the lower edge of the membrana tympani; it is attached here to the bony wall by the **anterior ligament** of the **malleus**; do not attempt to

trace the ligament till the malleus is removed later on. The tissues in the straight line thus followed down form the **axis band** of the malleus, i.e. the axis about which the ossicula auditûs turn.

6. Proceeding from the head of the malleus nearly at right angles to the axis band, inwards and downwards is a bony process to which is attached, by a very short tendon, the **tensor tympani muscle**. Press this towards its origin with a seeker and note that it tightens the membrane. Press lightly on the end of the handle of the malleus, it has but a small excursion.
7. With a fine pair of scissors cut through the attachment of the membrana tympani, except at the handle of the malleus, and with a small pair of bone forceps remove the upper part of the bony ring to which it was attached. The malleus will remain in position. The incus and stapes may be indistinctly seen deep down on the outer side.

In order to make out well the relation of these great care is required. Take a fine saw and proceeding from behind in a plane passing just outside the incus, saw away the external piece of bone.

Observe then

- a. The rather long slender neck, and knobbed head of the malleus.
- b. The **incus** with two processes, one passing almost horizontally backward and by a ligament attached to the bony tympanic wall, the other proceeding upwards, and attached to the head of the **stapes**. When the bones are removed later, the saddle-

- d.* The entrance into the cord of the **anterior roots** of the spinal nerves in several small bundles.
 - e.* The entrance into the cord of the **posterior roots** of the spinal nerves in a compact mass.
 - f.* The **white substance** forming the outer part of the cord and divided on each side by the entrance of the nerve roots into **anterior, lateral and posterior columns**.
 - g.* The division of each posterior column into two by a wedge of connective tissue; the median smaller part is called the slender fasciculus.
 - h.* The **grey matter** divided on each side into **anterior and posterior cornua**, but with no distinct separating line between them. Note the numerous nerve-cells; they are much more conspicuous in the anterior than in the posterior cornua.
 - i.* The **central canal**; probably it will be plugged up with epithelial cells; in the young animal it is lined by a layer of ciliated epithelium.
 - j.* A layer of connective tissue surrounding the central canal, and
 - k.* On either side of this, the anterior and posterior **grey commissures**.
 - l.* The anterior **white commissure** in front of the anterior grey commissure.
 - m.* A round or oval deeply stained area, forming the hinder part of the posterior cornu, the **substantia gelatinosa**.
2. Cut transverse sections of the spinal cord of a rabbit or dog taken from the dorsal and lumbar regions,

treat as in § 1, and compare with that of the cervical region. Note that

- a. The sections taken from the cervical and lumbar regions are larger than those taken from the dorsal.
 - b. The enlargements in these regions are due to an increase in the quantity of grey matter.
 - c. The quantity of white matter is greatest in the cervical region, less in the dorsal, and least in the lumbar; that is, the quantity of white matter in the spinal cord increases from below upwards.
 - d. In the dorsal region there is a small lateral collection of cells behind and to the outside of the central canal; this is **Clarke's column**, or the posterior vesicular column. It becomes indistinct in the cervical and lower lumbar regions.
 - e. Another small group of cells, the tractus intermedio-lateralis, may be seen chiefly in the lower cervical and upper dorsal regions midway between the anterior and posterior cornua.
3. Take a short piece of the spinal cord of a calf or ox and divide it longitudinally through the anterior and posterior commissures. Divide one of the pieces so obtained into two through the central canal and lateral columns. The cord should have been hardened in ammonium bichromate 5 p.c. from fifteen to twenty days, and subsequently in alcohol. Imbed both pieces and cut sections. Treat as before. Note under objective No. 7 or 8,
- a. The division of the connective-tissue septa into fine fibres forming a fairly regular meshwork, the **neuroglia**. Blood-vessels can easily be seen running in the thicker parts of the meshwork.

- b.* The transverse sections of the nerve-fibres occupying the spaces of the meshwork spoken of above. The axis-cylinders will be deeply stained, the medulla forming a clear ring round them. Note their varying size.
- c.* Surrounding the medulla a clear matrix with a plexus of very fine fibres.
- d.* The large nerve-cells in the *anterior cornu* with distinct nucleus and nucleolus. They may have two, three, four, or more processes, some of which may be traced for a considerable distance, some divide very rapidly.
- e.* The collection of the nerve-cells in the anterior cornu more or less distinctly into three groups: a large lateral group, a small median group, and a still smaller anterior group. This is best seen in the cervical and lumbar regions.
- f.* In the *posterior cornu* the nerve-cells are smaller.
- g.* The cross section of vertical fibres, both in front and behind the substantia gelatinosa.
- h.* Throughout the whole of the grey substance, a close plexus of very fine fibres.

Note the following horizontal fibres :

- a.* Fibres going from the anterior cornu of one side across the anterior white commissure to the anterior columns.
- b.* Fibres proceeding from the anterior cornu to ascend in the lateral columns.
- c.* The posterior nerve-roots, entering the cord and some running through the substantia gelatinosa.

- d.* Fibres between the slender fasciculus and the posterior cornua.
4. Tease out under a low power one of the sections including an anterior cornu; observe in the nerve-cells the single unbranched axis-cylinder process and the branching processes forming a very fine mesh-work of nerve-fibrils, the protoplasmic processes.
5. Cut an antero-posterior longitudinal section passing through both the anterior and the posterior nerve-roots, staining with aniline blue black.

Note

- a.* The longitudinal medullated fibres of the anterior column.
- b.* The anterior nerve-roots entering obliquely.
- c.* The nerve-cells and fibres of the anterior cornu.
- d.* The substantia gelatinosa of the posterior cornu, with vertical fibres on either side and curved fibres running through it.
- e.* The longitudinal medullated fibres of the posterior columns, in which can be seen
- f.* The cut ends of the posterior nerve-roots.

LESSON XXIX.

DISSECTION OF THE BRAIN OF A DOG OR SHEEP.¹

1. CAREFULLY handling the brain to avoid breaking the nerve roots, observe
 - a. The **cerebrum**, forming the large anterior mass, divided into two hemispheres by a median longitudinal fissure, each hemisphere having on its surface many indentations or sulci, with elevations or convolutions between them.
 - b. The **cerebellum**, behind, and partially covered by, the cerebrum, divided into a middle and two lateral lobes, each having slight, and, for the most part, transverse, folds.
 - c. The **medulla oblongata**, continuous with the spinal cord. In the middle line are seen the

¹ The brain should be removed from the skull as carefully as possible, especial pains being taken to cut the internal carotid arteries and the cranial nerves close to the skull. When the brain is removed it is best to tie the internal carotid arteries, and inject spirit of about 90 p. c. into the basilar artery, and then place the brain in spirit. It may be dissected in a few days, but a longer time is preferable. If the brain be not injected, it should be placed for two or three days in *weak* spirit of about 50 p. c., and then transferred to 90 p. c. spirit. The time required for hardening will in this case be at least a week.

small **posterior pyramids**, and on either side the more conspicuous **restiform bodies**. The former are the forward prolongations of the slender fasciculi, the latter include fibres from all three columns of the spinal cord.

- d.* The **pia mater**, a thin membrane closely surrounding the whole of the brain, and dipping down into the sulci. In it run the vessels which supply the brain with blood.
2. Tearing away so much of the pia mater as necessary, turn forward the cerebellum to observe the upper part of the medulla oblongata. Note
 - a.* The posterior pyramids and restiform bodies diverging, and so forming two sides of a rhomboidal space, the **fourth ventricle**. Trace the restiform bodies forwards; they enter the lateral lobes of the cerebellum, and are then called the **inferior peduncles** of the **cerebellum**.
 - b.* The **choroid plexuses** of the **fourth ventricle** formed by projections of the pia mater.
 - c.* Having removed the choroid plexuses, the **calamus scriptorius**, or angle formed by the divergence of the posterior pyramids.
 - d.* The opening into the central canal of the spinal cord, at the point of the calamus scriptorius.
 3. Turn back the cerebellum, tearing away the pia mater which dips down in front of it, and observe
 - a.* Projecting from the under surface of the cerebrum two round bodies, the **testes**.
 - b.* Immediately above these, and extending on each side, a cleft, the **transverse fissure**.

4. Gently separate from the testes the pia mater, which enters through the transverse fissure to form the **velum interpositum** (see 18), and observe
 - a. Immediately in front of the testes two other round bodies. These are the **nates**, and, together with the testes, form the **corpora quadrigemina**.
 - b. Behind the testes are two rounded bands of fibres proceeding from the cerebellum towards and underneath the corpora quadrigemina. These are the **superior peduncles** of the **cerebellum**.
 - c. The **valve of Vieussens**, a thin layer of nervous substance stretching between the superior peduncles, and covering in the anterior part of the fourth ventricle. In the anterior part of the valve the roots of the fourth nerve may be seen rising from the middle line, and curving round to reach the base of the brain.
 - d. The small aperture in the median line below the valve of Vieussens and the corpora quadrigemina, and continuous with the anterior part of the fourth ventricle, leads to the third ventricle (cp. § 23).
5. Separate gently the cerebral hemispheres, and note the **corpus callosum** or connecting band of transverse fibres between them.
6. Note on the under surface of the brain
 - a. The medulla oblongata, with two eminences, the **anterior pyramids**, on either side of the median longitudinal fissure. Carefully separate with the handle of a scalpel the anterior pyramids, and observe the decussation of the fibres.

- b.* Externally to the anterior pyramids just below the pons, two oval elevations, the **olivary bodies**.
- c.* The **pons Varolii**, a broad band of transversely arranged fibres with a shallow median groove, immediately in front of the medulla. This connects the lateral lobes of the cerebellum with one another, and is called the **middle peduncle** of the **cerebellum**. At the lower edge of the pons will be seen a narrow 'supplementary' band, which passes underneath the anterior pyramids.
- d.* The **crura cerebri**, or peduncles of the cerebrum, two broad bands of fibres which appear at the anterior edge of the pons Varolii, and run forwards diverging from one another.
- e.* The posterior perforated space, or space between these diverging fibres; it forms part of the floor of the third ventricle. When the pia mater has been removed it will be found to be pierced for the passage of small blood-vessels (to the optic thalamus).
- f.* The **corpus albicans** or mammillare in front of the posterior perforated space. In the dog there is a shallow median groove dividing it into two.
- g.* Immediately anterior to this the **pituitary body**; a round body on a stalk, the **infundibulum**, springing from the tuber cinereum which forms part of the floor of third ventricle (§ 20 *c*). The pituitary body will probably have been broken off in removing the brain from the skull.
- h.* The **optic tracts**, two flat bundles of fibres coming obliquely forward over the front part of the crura cerebri, and meeting in the middle line

to form the optic chiasma. The optic nerves will probably have been cut off.

7. Looking at one side of a brain of a *dog*, observe
 - a. The **Sylvian fissure**, a deep fissure coming up from the under surface of the cerebrum and running backwards and upwards.
 - b. The **supra Sylvian convolution**, forming a curve round the posterior part of the Sylvian fissure.
 - c. The **inferior external convolution**, forming a fold immediately above (*b*).
 - d. The **middle external convolution**; this is nearly straight antero-posteriorly; in the posterior part there is a longitudinal sulcus giving it a bifid appearance.
 - e. The **superior external convolution**, bounding on one side the median longitudinal fissure.

It may be noticed that the above general plan of the convolutions is to a certain extent modified in different dogs by secondary sulci, so that in some the divisions of each half of the cerebrum into four convolutions may not be evident at first sight.

8. Note on the upper surface of the brain of a *dog*
 - a. The **crucial sulcus**; this is a sulcus at about the anterior third of the brain, running on each side from the median longitudinal fissure outwards in the superior convolution, and bifurcating. A line drawn through it to the end of the Sylvian fissure roughly divides the convolutions into frontal and parietal portions.

- b.* The **sigmoid gyrus**; this is that part of the external convolution which bounds the crucial sulcus.
9. Separating the hemispheres, note
- a.* The **calloso-marginal convolution**, running above the corpus callosum, and separated above by a fissure from the superior external convolution. This is marked by more or less distinct sulci.
- b.* The **hippocampal convolution**; this is the continuation of (*a*) on the under surface of the brain, cp. § 13 *b.*
10. Take now a fresh brain, reserving the brain used above for reference to any points that do not appear clear on the first dissection. Trace the chief blood-vessels running in the pia mater of the under surface of the brain. At the upper part of the medulla will be seen two arteries. These are the **vertebral arteries**, which having given off recurrent branches along the anterior fissure of the medulla, curve round to unite in the median line; the vessel formed by their union is called the **basilar artery**, and runs forwards in the median line of the pons Varolii. At the front edge of this it divides into two, called the **posterior cerebral arteries**, each of which running obliquely forward passes to the median side of the third nerve as it springs from the crus cerebri.

Just beyond this each posterior cerebral divides into two branches. One of these runs backward; the other proceeding forwards, is, a little behind the optic commissure, joined by the **internal carotid artery**. Each arterial trunk so formed passes round the optic

commissure, and divides into the **middle cerebral artery** which runs in the fissure of Sylvius, giving off numerous branches, and the **anterior cerebral artery** which passes forwards between the front lobes of the cerebrum, having a large transverse communicating branch with its fellow of the opposite side. The anastomoses between the branches of the posterior cerebral and the internal carotid arteries and those between the two anterior cerebral arteries complete the **circle of Willis**.

11. Carefully remove the pia mater and observe the origin of the nerve-roots.
 - a.* The olfactory nerves, or more correctly olfactory lobes, proceeding from the under surface of the anterior part of the cerebrum.
 - b.* The optic chiasma and tracts (§ 6 *h*).
 - c.* The third pair of nerves, arising from the inner surfaces of the crura cerebri in front of the pons Varolii (§ 10).
 - d.* The fourth pair of nerves, which will be seen curving round the front edge of the pons Varolii; they originate a little behind the corpora quadrigemina (§ 4 *c*).
 - e.* The fifth pair of nerves, large and conspicuous, arising from the sides of the pons Varolii.
 - f.* The sixth pair of nerves, arising in front of the olivary bodies and anterior pyramids close behind the pons.
 - g.* The seventh pair of nerves, arising from the depression between the olivary and restiform bodies close behind the pons.

- h.* The eighth pair of nerves, arising from the restiform bodies a little to the outside of the seventh pair. Sometimes fibres proceed from the seventh to the eighth, rendering it difficult to distinguish them.
- i.* The ninth, tenth and eleventh pairs of nerves, each arising by several roots from the restiform bodies, in a line with the eighth but more posteriorly.
- k.* The twelfth pair of nerves, arising between the anterior pyramids and the olivary bodies by several roots.

12. Slice away the surface of the cerebrum to the level of the corpus callosum, noting the central white medullary substance and the thin cortical grey layer.

In the dog the lateral ventricles project above the level of the corpus callosum; when they are reached it is as well to proceed at once to lay them bare.

Observe the curving of the corpus callosum in front and behind.

13. Make a slight incision along each side of the corpus callosum and so lay bare the **lateral ventricles**; removing the necessary parts of the cerebrum, trace out the anterior and descending cornua of the ventricles.

Note

- a.* The **corpus striatum**, a projection into the floor of the anterior cornu.
- b.* The **hippocampus major** or **cornu Ammonis**, a considerable projection into the descending cornu.
- c.* The **choroid plexus** of the **lateral ventricle**, lying immediately in front of (*b*), and continuing

in front as far as the commencement of the anterior cornu.

d. Between the corpus striatum and the choroid plexus is a ridge which is brought more into view by turning back the choroid plexus. This is part of the **optic thalamus**. It forms a larger part of the floor of the lateral ventricles in the sheep than in the dog.

14. Turn forwards the choroid plexus, it will be seen that it normally overlies a narrow band with a free edge; the part of this band adjoining the hippocampus is called the **corpus fimbriatum**.
15. Holding up the corpus callosum, the lateral ventricles will be seen to be separated by a thin membrane, the **septum lucidum**. It is really a double membrane. Cut through the corpus callosum behind and gently turn it forwards, separating it from the septum lucidum. In the anterior part of the septum lucidum a very small narrow cleft may sometimes be seen; the **fifth ventricle**.
16. Cut away the corpus callosum, and observe underneath it the **body of the fornix**. This is a triangular lamina, the narrow anterior part of which dips down just behind the anterior bend of the corpus callosum. Posteriorly it divides into two diverging bundles of fibres, the **posterior pillars of the fornix**, part of which spread out over the hippocampus major, the rest forming the corpora fimbriata. This will be rendered clearer on turning back the fornix (§ 18).
17. Trace forwards the choroid plexuses; they will be found to dip down and join under the anterior narrow part of the fornix through the **foramina of Monro**.

18. Pass the blade of a pair of scissors through the foramina, and cut through the fornix. Carefully turn back the fornix. A vascular membrane, the **velum interpositum**, will be seen underlying it; this folds round the edge of the fornix to form the choroid plexuses. Separate the fornix from the velum; the diverging posterior pillars will now be well seen; the part of the corpus callosum between them is called the lyra. The thickened posterior free edge of the corpus callosum forms the upper boundary of the transverse fissure.

19. Turn back now the velum interpositum, and note that the foramina of *Monro* form the anterior part of a space, the **third ventricle**, underlying the velum interpositum and continuous with the lateral ventricles. Normally the third ventricle is only continuous with the lateral ventricles by the foramina of *Monro*, since the thin epithelial layer of the lateral ventricles passes from the corpora striata to the fornix, *over* the choroid plexus. In separating the velum posteriorly, note two projections downwards into a median fissure, the **choroid plexuses** of the **third ventricle**; be careful not to injure a round body, the **pineal gland**, situated immediately in front of the corpora quadrigemina.

20. In the surface now exposed, observe
 - a.* The **anterior pillars** of the **fornix**, two vertically descending cords into which the anterior part of the fornix divides. They descend to the base of the brain, and curving round form the external part of the corpus albicans.

- b.* The **anterior cerebral commissure**, a small white bundle of fibres running transversely in front of the anterior pillars of the fornix, and seen between them. It connects the corpora striata.
 - c.* The central depression or **third ventricle**. Cutting away the necessary part on one side, trace the passage from this into the infundibulum.
 - d.* The **optic thalami**, forming the lateral boundaries of the third ventricle. Trace the optic tracts to these.
 - e.* Proceeding across the third ventricle connecting the optic thalami, a bridge of grey matter, the **middle cerebral commissure**. This is very easily torn through.
 - f.* On the inner edge of each optic thalamus a ridge proceeding to the pineal gland; these are the **peduncles of the pineal gland**.
 - g.* The small, white, **posterior cerebral commissure**, in front of, though partially covered by, the pineal gland.
21. Cut through the corpus striatum on one side, and observe the external layer of grey substance, and the central striated appearance from fibres running in from the crus cerebri.
22. Between the optic tracts and the corpora quadrigemina, note two oval bodies, the **corpora geniculata**, and the band of fibres on either side proceeding from the nates, and dipping down under the corpus geniculatum internum to join the optic tracts.

23. Trace out the passage from the third to the fourth ventricle, or **aqueduct of Sylvius**. It will be found to pass beneath the posterior cerebral commissure, and the corpora quadrigemina.
24. Divide the cerebellum by a longitudinal vertical incision in the median plane; observe the arborescent appearance (*arbor vitæ*) produced by the arrangement of the outer grey and inner white substance. Make a similar longitudinal section through the middle of one of the lateral lobes; note in the midst of the white substance the irregular outline of the grey matter of the **corpus dentatum**.
25. Divide a sheep's or a dog's brain in half, by a longitudinal section carried carefully through the median line, and observe

The corpus callosum, with its anterior and posterior bend, the latter being continuous with the fornix, the body of which is seen as a thin layer lying beneath the corpus callosum and curving downwards anteriorly towards the corpus albicans as the anterior pillars. Since these diverge, they will be visible only in part of their course.

The septum lucidum and the lateral ventricle.

The transverse fissure; the velum interpositum entering the transverse fissure, underlying the fornix and forming the roof of the third ventricle.

The aqueduct of Sylvius; the valve of Vieussens passing from the corpora quadrigemina and entering into the median lobe of the cerebellum.

The pineal gland with its peduncle.

The posterior commissure of the cerebrum: it is covered by a thin lamina formed by the united peduncles of the pineal gland. In the section this lamina appears as a band proceeding from that body. The large middle commissure, forming a considerable portion of the cavity of the third ventricle. The anterior commissure, a little below the apparent termination of the anterior pillar of the fornix.

The optic tract.

The pons Varolii.

DEMONSTRATION.

Preparations to shew the microscopic structure of cerebrum and cerebellum.

LESSON XXX.

DISSECTION OF THE LARYNX.

1. It is preferable to obtain a fresh larynx of a sheep or an ox from the butcher's; but the spirit-preserved larynx of the dog (Lesson I.) will serve. The larynx will probably be obtained with the upper part of the œsophagus attached, and surrounded by a mass of muscle and connective tissue.

Having slit up the œsophagus lengthways, turn back or cut away the sides and observe the opening into the larynx bounded in front by the epiglottis, at the sides by folds of the mucous membrane, and behind by the large converging yellow crests of the arytenoid cartilages. On looking down into the larynx the opening between the vocal cords, or **rima glottidis**, may be seen at some depth below. Observe that the mucous membrane of the œsophagus is continuous with that of the larynx. Bend down the epiglottis projecting from the front, upper, edge of the larynx, and note that the passage to the larynx is then quite closed.

2. From the posterior surface carefully remove the œsophagus with the pharyngeal muscles. From the

sides dissect away the sterno-thyroid muscle (Lesson I. § 24), taking care not to injure the muscle lying underneath it (§ 3), and clear away the whole of the thyro-hyoid muscle which covers the side of the thyroid. The hyoid bone and thyro-hyoidean membrane may be left. The outlines of the thyroid will now come into view, clear away the connective tissue until they are quite distinct. Note that

The **thyroid cartilage** consists of two lateral laminae, which meet in front and diverge behind, and have their upper and lower posterior angles prolonged, forming the upper and lower cornua. Observe in front the rounded projection or Adam's apple.

3. Observe the **crico-thyroid muscle** spoken of above (§ 2); dissect it away, noting its attachments. The **cricoid cartilage** will come into view, and it will be seen that the muscle in question passes from the posterior cornu and posterior portion of the lower margin of the thyroid, to the front part of the cricoid. Observe that below this muscle there is stretching between the two cartilages a membrane which limits the movements of the thyroid.
4. Observe the articulations of the posterior cornua of the thyroid to the cricoid. Disarticulate one cornu, cut through the crico-thyroid membrane, and remove one half of the thyroid, taking care not to injure any of the muscles. Trace out with the finger the outlines of the cricoid cartilage. Note that

It forms a complete ring, which in front is narrow, and is covered by the edge of the thyroid, but behind is deep and enclosed on either side by the thyroid.

5. On the posterior surface of the cricoid note on either side of a central ridge two laminae of muscle, the **posterior crico-arytenoids**; cut through their attachment to the cricoid, and reflecting them from below upwards note that they are attached above to the external angles of two cartilages, the **arytenoid cartilages**, placed on the posterior upper edge of the cricoid cartilage.
6. Carefully clear away the tissue from the back of the arytenoid cartilages above the cricoid, and observe on the posterior surface of the former the **arytenoid muscle**; cutting it through the middle, which in the sheep is frequently tendinous, reflect it on either side; it will be seen to be attached to the back of each arytenoid cartilage; the posterior surface of the arytenoid cartilage will now be laid bare, and its articulation with the cricoid cartilage can be made out.
7. Looking at the larynx where the thyroid has been cut away, observe the **lateral crico-arytenoid muscle**. Cut away its attachment to the lateral portion of the upper margin of the cricoid, and, reflecting it, observe that it passes backwards and upwards from the cricoid to be inserted into the arytenoid cartilage just in front of the insertion of the posterior crico-arytenoid.
8. Clearing away the fat and connective tissue from the side of the larynx, observe the **thyro-arytenoid muscle** stretching across from the thyroid in front to the arytenoid behind. Cut it through in the middle and reflect both ends. Note its origin from the angle of the thyroid and its insertion into the

lateral surface of the arytenoid in front of the insertion of the lateral crico-arytenoid.

Remove the muscle altogether, and observe the lateral surface of the arytenoid cartilage.

9. Cut away on the same side the underlying mucous membrane; the interior of the larynx will now be laid open. On the opposite side the indistinct vocal cord will be seen passing as a pale band of tissue from the anterior angle of the arytenoid cartilage to the angle of the thyroid. The inner or medium surfaces of the arytenoid cartilages will be seen to bound a large oval space, called the respiratory space.
10. Clear away on one side any muscle or connective tissue still attached to the arytenoid cartilage, and observe more fully its shape, noting particularly the anterior projection or processus vocalis, the posterior lateral projection or processus muscularis, and the articulation with the cricoid.
11. Dissect *from the inside* the thyro-arytenoid muscle of the opposite side, and observe more carefully its attachments (§ 8).

The larynx of the sheep differs materially from that of man, by the indistinctness of the vocal cords, by the absence of the false vocal cords and ventricles of the larynx, and by the peculiar crested conformation of the arytenoid cartilages.

DEMONSTRATION.

The use of the laryngoscope.

LESSON XXXI.

TISSUES OF REPRODUCTION.

A. OVARY.

1. Prepare sections of ovary of a mammal, *e.g.* cat, hardened in a mixture of equal parts of chromic acid .5 p.c. and 90 p.c. alcohol. Let some of the sections be longitudinal, and others transverse. Be careful that the sections are especially thin at the periphery of the organ. The section will probably not need staining; they may be mounted in glycerine, or after the usual treatment in Canada balsam.

Examine with no. 3 or 4 objective, and observe

- a.* The fibrous 'medullary' portion or **stroma**, radiating from the **hilus**, and forming the greater portion of the organ, especially in the case of young animals.
- b.* The cortical layer, consisting of small **Graaffian follicles**, and forming a zone immediately underneath the fibrous investment or *tunica albuginea* along the whole periphery except at the hilus.
- c.* Larger (older) Graaffian follicles which have sunk into the substance of the stroma, and are thus at some distance from the surface.

It has no distinct cell-wall. Within it lies a comparatively large, also transparent, nucleus, the **germinal vesicle**.

- β . A layer of columnar epithelium immediately surrounding the ovum and lining the follicle; this is the **membrana granulosa**.
- e. The larger Graaffian follicles. In these will be seen
- a. A fibrous investment of the follicle: the tunica or theca follicularis.
 - β . A lining of epithelium more than one cell deep.
 - γ . At one spot this epithelium is collected into a mass, the **cumulus proligerus**, in the midst of which is embedded
 - δ . The ovum, with its cell-substance or vitellus more distinctly granular, and its germinal vesicle marked with a nucleolar looking spot, the germinal spot. In these follicles the ovum has a distinct investing membrane, which in some is much thickened, so as to form a *zona pellucida*. From this the vitellus frequently shrinks in the process of hardening. The cells of the cumulus which lie next to this membrane are frequently arranged in a radiating manner.
 - e. The rest of the follicle is filled with fluid.
3. Tease out in dilute glycerine a thin and small section of the more superficial stroma. Observe, intermingled with the ordinary connective tissue and blood-vessels, the abundant spindle-shaped fibres.

4. Tease out in dilute glycerine a thin section taken from the centre of a corpus luteum. Observe
 - a. Cells similar in character to epithelium-cells, often large and loaded with pigment and fatty granules. (Crystals of hæmatoidin may be seen.)
 - b. Cells similar to white-blood or lymph-corpuscles.
 - c. Spindle and other shaped cells: developing connective tissue.

The appearances will vary much according to the age of the corpus luteum.

5. In some of the sections taken near the hilus there may be seen lying in the stroma groups of tubules, lined with a short cubical or flattened epithelium, and cut at various angles. These are the tubules of the **parovarium**.
6. Take the fresh ovary of a sheep or large dog; observe the bulgings due to the more or less ripe Graaffian follicles. Holding the ovary over a glass slide, carefully prick the most prominent follicle and receive the contents on a glass slide. Examine *without a cover slip*, with simple lens or low objective. If the ovum is present it will at once be recognized. When found carefully cover with a cover slip, inserting a ring of paper in order to *avoid pressure*, and examine with a higher power. Observe
 - a. The thick zona pellucida, with double contour (and radiating striation).
 - b. The granular vitellus.

- c. The transparent germinal vesicle, with its germinal spot. If the follicle be quite ripe these may have disappeared.
- d. The cells of the cumulus proligerus attached all round the zona pellucida.

B. TESTIS.

1. Take a small mammalian testis, *e.g.* of guinea-pig or rat, which has been hardened in Müller's fluid, and cut longitudinal sections through the testis and globus major of the epididymis. Observe with objective no. 3 or 4.
 - a. The **tunica vaginalis propria**, which is round the greater part of the testis firmly connected with the underlying tissue, and is hence called the tunica adnata. It separates from the testis near the epididymis.
 - b. The **tunica albuginea**, the thick investment proper of the testis; near the epididymis it is very much thickened, forming the **corpus Highmori**; towards this radiate bands of connective tissue from the rest of the albuginea, forming the septula testis and so dividing it into lobules.
 - c. The **tubuli seminiferi**, contorted and anastomosing tubes occupying the lobular spaces; near the corpus Highmori the tubes unite, and the tubes so formed, the **vasa recta**, have a short, tolerably straight course; in the corpus Highmori they anastomose with one another, forming the **rete testis**; from the outer edge of this may be seen one or two larger tubes, the **vasa efferentia**,

which originate from the rete and open into a still larger tube, the canal of the **epididymis**.

2. Cut thin sections of the lobular part of the testis of a dog, and observe with a high power
 - a. The tunica vaginalis, consisting of fine fibrous connective tissue, having externally a single layer of tessellated epithelium.
 - b. The tunica albuginea, of coarser connective tissue, with numerous blood-vessels running in it, and in the septula testis.
 - c. The intermediate tissue between the tubuli seminiferi. In the dog this is small in amount, and consists mainly of fine connective tissue containing numerous connective-tissue corpuscles, and of blood-capillaries.
 - d. The tubuli seminiferi. In these note
 - α. A tunica adventitia of elongated and branching cells.
 - β. A membrana propria.
 - γ. The cells filling the tubes, to a greater or less extent, so that there is no distinct lumen. They are for the most part polyhedral from compression, with large nuclei staining deeply with hæmatoxylin, and small nucleoli. Other forms of cells may be seen.
 - δ. The spermatozoa, lying generally in bunches in the larger cells; the heads, situated peripherally, and staining deeply. The method of development of these from the cells in the seminal tubes is still a matter of dispute.

3. Cut sections of the lobular part of the testis of a pig, cat, or rat, and observe that

The tissue surrounding the tubuli seminiferi or intermediate tissue differs from the corresponding tissue of the dog's testis in containing a large number of polyhedral cells with round nuclei, not unlike hepatic cells.

4. Tease out in water a small fragment from a piece of testis that has been treated with osmic acid 1 p. c. for twenty-four hours, and observe more particularly the characters of the cells.

5. Cut a section through the corpus Highmori, and observe that

- a. The tubuli form a network of passages without distinct walls.
- b. The passages are lined with tabular or cubical epithelium.

6. Cut a transverse section through the globus major of the epididymis, and note both in the vasa efferentia and in the canal of the epididymis,

- a. The external fibrous coat.
- b. The circular muscular coat.
- c. The basement membrane.
- d. The epithelium, consisting of cylindrical ciliated cells, with two or more rows of small cells between them and the basement membrane. In the canal of the epididymis the cylindrical cells are long and slender.

- e.* The distinct lumen.
 - f.* The mass of spermatozoa, occupying in some cases the lumen.
7. Cut a transverse section of the vas deferens. Note
- a.* The external fibrous coat.
 - b.* The muscular coat of three layers, two longitudinal and one circular, the latter being the most developed.
 - c.* The ciliated columnar epithelium.
8. Cut in half the fresh testis of a rat, and gently press the cut surface on a glass slide. Observe the spermatozoa, each consisting of
- a.* An ovoid head.
 - b.* A long tapering tail.
 - c.* A short intermediate part.
- Note that the spermatozoa move by a whip-like movement of their tails.
9. Observe in like manner the spermatozoa of a frog. In *Rana temporaria* there is no head, but only a long thread of protoplasm.

APPENDIX.

NOTES ON THE USE OF THE MICROSCOPE¹.

See that the tube of the microscope moves easily, but not too easily, up and down. It should be occasionally rubbed round with a little olive-oil, and the oil then wiped off with a dry cloth.

With a piece of soft chamois leather or silk, remove any dust that may be on the lenses of the eye-piece or on the lower lens of the objective. If by accident the objective has been smeared with glycerine, stream it with water from a wash-bottle, and wipe it dry with chamois leather: if with Canada balsam, place on it a drop of chloroform, and rub gently, repeating till the balsam is quite removed: this must be done very cautiously, since the lenses are sometimes fixed in with Canada balsam.

All *unnecessary* rubbing of lenses however should be avoided; hence take care to put them away after they have been used.

It is advisable for the student not to unscrew the separate lenses of a high objective; when however the dimness of an object under observation renders it necessary to do so, care must be taken not to remove the black coating

¹ The microscope to which reference is made in the text is Hartnack's Stativ III. with oculars 2 or 4 and objectives 3 or 4 and 7 or 8. Nearly corresponding to this on Zeiss' model is Stativ III^b. no. 20 with oculars 2 and 4, objectives A and D.

on the inside of the tube in cleaning the lenses, and when cleaned to restore them, in proper order, to their previous positions.

With No. 4 objective, twist down the microscope-tube till it is about a quarter of an inch from the object; then looking through the eye-piece, twist the tube *upwards* till the specimen is in focus.

With objective No. 7, lower the tube till it is $\frac{1}{8}$ of an inch from the object, and then slowly twist the tube down, moving the slide about, till the object just becomes visible, then focus by means of the fine adjustment.

Direct sunlight should not be used to illuminate the field; in selecting a permanent position to work with the microscope, it is best, if possible, to face the north,—or if this is not practicable, to have the light on the left-hand side.

With high powers, use the corresponding small diaphragm; otherwise although the field may look brighter, the outlines of the cells, etc. will not be so well defined.

The student should accustom himself to keep *both* eyes open when using the microscope, and to use *either* the right or the left eye for looking at specimens. The fatigue of microscope work is thus very much lessened. It generally requires a little practice to keep both eyes open, but a few minutes' trial every time that the microscope is used will soon overcome the difficulty.

When an object appears dim, it may be caused by some fault in the specimen itself, or by the object-glass not being clean. In the latter case the dimness remains, whether the object is in focus or not. Dust upon the eye-piece can be recognized by the outlines of the particles appearing well defined; they do not look dim and diffuse.

To determine the *magnifying power* of a microscope with any given ocular, objective, and length of draw-tube, com-

pare the drawing of the apparent size of the divisions of the stage micrometer seen under the microscope (see Lesson II. § 3) with the actual size. Thus, if the stage micrometer consists of a centimetre divided into millimetres, and the space between one division of the drawing and the next is just a centimetre, then one millimetre has been magnified to a centimetre, and the magnifying power is 100.

OBSERVATION OF FRESH TISSUES.

There are but few of the tissues of the body, which in the fresh state are sufficiently consistent and firm to allow thin sections to be cut with the razor.

This, however, is of no very great importance, since the main end of observing the fresh tissue is to ascertain to what extent the various hardening and staining agents, which enable one or another constituent part of the tissue to be clearly seen, alter the tissue components. By taking a small piece of a tissue, and teasing it out carefully in a normal solution, enough can generally be gathered of the normal appearances to judge whether the reagents used cause any structural modification, or simply bring more clearly to view already existing outlines.

With tolerably firm bodies, *e.g.* the kidney, it is best to cut as thin sections as possible with a razor, either not moistened at all, or covered with normal saline solution, and observe one section under the microscope, mounted in some normal solution, whilst another is carefully teased out.

With structures too yielding to cut sections, a piece should either be snipped off, as with the villi of the small intestine, with a fine pair of scissors, or a strip torn off with a forceps, as with the coat of an artery, and then teased out.

There are certain fluids which, when fresh, cause very slight changes in the tissues; they more or less resemble the fluids with which the tissues in the body are surrounded.

These **normal fluids** are

- a.* The aqueous humour of the eye.
- b.* Blood-serum.

If, then, a fresh tissue is to be observed from *e.g.* a rabbit, the corneæ should be punctured to obtain the aqueous humour, or the blood should be allowed to clot in a flat vessel, to obtain the serum. In one of these fluids the tissues should be mounted.

- c.* Normal saline solution.

This may be prepared by dissolving 7·5 gm. of sodic chloride in 1000 cc. of distilled water.

- d.* Iodized serum.

Iodine is sometimes added to serum to preserve it, so that it may be at hand when required; serum thus iodized is, however, far less a 'normal' fluid than the others. It may be prepared by dropping a few crystals of iodine into fresh serum, and shaking occasionally. The fluid should be of a light brown colour.

Teasing.

Be careful to take a *small* piece only: it should be viewed with a low power before teasing, to ascertain the general relation of the parts, and hence to guide the teasing: thus, if it consists of parallel fibres, with one needle fix the piece at one corner and draw the other needle through it in the direction of the fibres; in teasing out to shew special objects, *e.g.* ganglion-cells, the arrangement of the parts should be *particularly* noticed under a low power.

In teasing, it is important to place the slide on an appropriate ground; if the object is clear, the slide should be placed on a piece of black paper, if it is dark, on a piece of white paper. Stained sections should also be teased out against a white or grey ground.

DISSOCIATING FLUIDS.

These are fluids which, whilst preserving certain parts of a tissue, dissolve or partially dissolve others, principally the cementing or ground substances, so that the former can be isolated by teasing or shaking. As a rule the piece of tissue so treated should be only a few mm. square.

Weak iodized serum of a light brown colour is in most cases the best. As the tissue absorbs the iodine, a little strongly iodized serum should be added; or the fluid renewed. The tissue may often be teased out after one day; but a longer time may be necessary.

Chromic acid .02 p. c. is useful for nerve-cells in spinal cord.

Müller's fluid answers well for olfactory mucous membrane, stomach, kidney.

Weak spirit 36 p. c. is frequently used for isolating epithelial cells.

Baryta water, for tendons, &c.

Osmic acid .1 to 1 p. c. is a dissociating fluid of general application; it has the advantage of altering the normal appearances very slightly.

Neutral ammonium chromate 5 p.c. gives good results with mucous glands.

As a rule tissues to be teased out should not be transferred to alcohol, but separated in a drop of the dissociating fluid after a time varying from a hour or so to three weeks.

There are various other dissociating fluids, but the above will be sufficient to illustrate their use to the beginner.

HARDENING AND HARDENING AGENTS.

General Directions.

The tissue should be removed from the body to the hardening agent as soon as possible after the death of the animal.

Be careful to divide the tissue to be hardened into *small* pieces before placing in the hardening fluid. As a rule the pieces should not be more than 3 to 4 mm. square.

If the tissue be moderately resistant, it is better to cut it up with a razor or sharp scalpel, than with a pair of scissors.

In all cases where a tissue is put in a fluid to harden or have lime-salts extracted from it, the fluid in which it is placed should be relatively abundant, *e.g.* 15 to 20 times the volume of the tissue; it should be renewed after a time varying from 12 to 24 hours.

After the substance has been hardened it should be transferred to *weak* alcohol, *e.g.* 50 p. c., and there be left for two days.

It should then be placed in a little stronger alcohol, *e.g.* 70 p. c., and left for one day; and finally placed in 90 p. c. till required for sections.

This method answers fairly in most cases, but it is more satisfactory, especially with chromic-acid specimens, to change the 50 p. c. alcohol every day, till on being left for twenty-four hours the alcohol remains uncoloured. Tissues permeated with chromic acid are not stained by carmine or hæmatoxylin; moreover chromic acid is not soluble or but very slightly in strong alcohol, hence the repeated change of the 50 p. c. In particular cases the tissues should be transferred from 90 p. c. to absolute alcohol.

The tissues should be placed in a flat short bottle to harden, rather than a narrow high one; and they must be kept *cool*, especially when they are first removed from the body to a hardening agent.

Preparation of Solutions.

In making solutions containing a definite percentage of hardening or other substance, remember that 1 cc. of

water at 4° C. and 760 mm. pressure weighs exactly 1 gm., and that under the ordinary variations of temperature and pressure it may be taken always to weigh 1 gm.; a 5 per cent. solution of (*e.g.*) ammonium bichromate may therefore be made by dissolving 5 gm. of the salt in 95 cc., *i.e.* 95 gm. of distilled water, the resulting mixture must weigh 100 gm. of which 5 are ammonium bichromate, hence it is a 5 p. c. solution; and a .5 solution of gold chloride by dissolving .5 gm. of the salt in 99.5 cc. of distilled water.

Since it is not important to have the solution *exactly* 5 p. c. or .5 p. c., it is usual to take 100 cc. of water in the above and other similar cases.

A solution of any given percentage can easily be diluted to one of a lower percentage: thus, if it is required to dilute a 5 p. c. solution of ammonium bichromate to a 2 p. c. solution; 100 parts of the 2 p. c. solution contain 2 parts of the salt, therefore 250 parts of the 2 p. c. solution contain 5 parts of the salt, but 100 parts of the 5 p. c. solution contain 5 parts of the salt, hence by diluting the 100 to 250 parts the 2 p. c. solution is obtained.

Chromic Acid.

Dissolve 10 gm. in 1000 cc. of distilled water.

The .5 solution is that most frequently used; it is easily prepared at any time from the above 1 p. c. solution by diluting with an equal volume of water.

For acting on bone and teeth, 1 cc. of nitric acid may be added to the above; the action is much more rapid, but care must be taken to transfer to alcohol as soon as the salts are extracted.

Chromic acid hardens the tissues by an action analogous to tanning; but renders them, if they are left in it too long, brittle and friable.

Potassium Bichromate.

The 1 p. c. solution is the most useful. Dissolve 10 gm. of the salt in 1000 cc. distilled water.

Ammonium Bichromate.

Dissolve 50 gm. ammonium bichromate in 1000 cc. distilled water. This gives a 5 p. c. solution.

Müller's fluid.

Dissolve 25 grms. of potassic bichromate and 10 grms. of sodic sulphate in 1000 cc. of water.

Picric acid. (Kleinenberg's method.)

Make a cold saturated solution of picric acid, and to 100 cc. of this add 2 cc. of concentrated sulphuric acid; filter, and to the filtrate add 300 cc. of distilled water.

Tissues should be left in this for a comparatively short time, varying from three hours to twenty-four, with the exception of bone, which requires some days, since there are lime salts to be extracted.

A simple concentrated aqueous solution is also frequently useful.

Osmic acid.

A 1 p. c. solution of this is the most useful. To avoid reduction of the osmic acid great care should be taken to obtain *pure* water. The bottle should be washed out with sulphuric acid and then with distilled water. If the osmic acid turns dark it must be covered with black paper or kept in the dark.

Most tissues are sufficiently hardened by a stay of twenty-four hours in 1 p. c. osmic acid to allow of sections being at once cut. If not sufficiently hardened, but deeply enough stained, which with some tissues takes place in one to four hours, they should be transferred to spirit,

In the presence of organic matter osmic acid is reduced in the light. This takes place quickly in the presence of fatty substances, so that in a tissue which has been stained with osmic acid, the medullated nerve-fibres can be easily traced.

Osmic acid specimens which it is desired to preserve should be mounted in dilute glycerine or in a concentrated aqueous solution of acetate of potash.

Alcohol.

Alcohol, besides its general use of completing the hardening begun by other fluids, is sometimes used alone. It coagulates the albumin in tissues and then renders them more opaque. Absolute alcohol should be used, since dilute alcohol causes more or less disintegration.

IMBEDDING.

Take a *small* piece of tissue only to imbed; of course this cannot be done in many cases, where it is desired to make out the general relation of the parts of an organ, *e.g.* the eye.

Before imbedding press the piece of tissue very gently between blotting-paper, to remove as much as possible of the fluid in which it has been placed. Spirit and the other hardening agents, if not removed, cool the imbedding mixture immediately round the tissue, and not mixing with it, prevent any adherence between the mixture and the tissue: with spirit specimens the excess of fluid should not be removed till the imbedding substance, etc. is ready, since the spirit rapidly evaporates, and the tissue dries. If it is desired that the imbedding substance should not only adhere to the outside of the tissue so as to form a support for cutting, but should also penetrate its spaces and render it firm to cut right through, it should be placed in absolute alcohol for about five minutes to remove all water, and transferred for about half an hour to oil of

bergamot. It should then be imbedded in spermaceti and castor oil, with which the oil of bergamot mixes. To cause a thorough filling up of cavities it is advisable to soak the tissue, removed from the oil of bergamot, in the *just melted* imbedding mixture for a minute or two before imbedding.

For the method of imbedding see Lesson IV. § 4. Note also that

Instead of using a block of imbedding mixture, the following method will frequently be found useful. Cut a small oblong piece of tolerably stiff paper from the angles toward the centre, fold the sides and fasten them together with sealing-wax, so that a small box open above is obtained. Pour the melting imbedding mixture into this $\frac{1}{3}$ of an inch in depth and allow it to cool. The tissue to be imbedded can then be placed on this and the mixture poured over it.

The imbedding substance should be heated as little as possible above its melting point. To keep it at a constant temperature, a sand-bath heated by a small gas jet may with advantage be used.

When the tissue is moved about to remove air-bubbles, etc. in the still liquid imbedding substance, by means of a heated needle, bring down the temperature of the needle to that of the substance by moving the needle about in it before touching the tissue.

Before cutting sections, cut away as much of the imbedding substance around the tissue as possible without causing the tissue to become loose. It is easier to cut thin sections when the surface to be cut is small than when it is large.

The substance in which different tissues should be imbedded varies with the consistency of the tissue. As a rule the imbedding substance should be of about the same degree of hardness as the tissue. Loose tissues with many cavities must generally, in order to obtain satisfactory sections,

be imbedded in a material which will penetrate the tissue and fill up the cavities, *e.g.* spermaceti and castor oil: in this case the sections are usually of little value except for teasing out, unless the imbedding mixture be removed by carbolic acid and turpentine.

In some cases thin sections may be obtained which may be mounted in glycerine by carefully removing the excess of fluid from the outside of the tissue, and then imbedding it in a mixture which has but little penetrating power, not moving it about to remove air-bubbles.

If the tissue has been stained before imbedding, and it is intended to clear it in carbolic acid and turpentine, and mount in Canada balsam, the section should be cut with a razor wetted with *olive oil*; in other cases the razor should be wetted with alcohol.

In preparing the following mixtures, the constituents should be placed in a capsule on a sand-bath and kept at a temperature just above melting point for an hour or more, the liquid being occasionally stirred.

Paraffin A.

Solid paraffin 15 grms.

Liquid paraffin 15 cc.

This is used to surround the cover-slip in observing the amoeboid movements of white blood-corpuscles, on the warm stage. It begins to melt at about 37° C., and thus serves as an indication of the limit of temperature that can be used in the observation without injury.

Paraffin B.

Solid paraffin 30 gm.

Cocoa butter 10 gm.

Hog's lard 30 gm.

This is a soft imbedding mixture, melting at a low temperature, and not dissolved by carbolic acid and turpentine. It does not easily penetrate tissues.

Paraffin C.

Solid paraffin 30 grms.
Cocoa butter 20 grms.
Spermaceti 10 grms.

This is a moderately hard imbedding mixture, soluble in carbolic acid and turpentine.

Paraffin D.

Solid paraffin 20 grms.
Cocoa butter 10 grms.
Spermaceti 10 grms.

This is a harder mixture, also soluble in carbolic acid and turpentine.

Spermaceti and Castor Oil.

Spermaceti 40 gm.
Castor oil 10 gm.

[An excellent mixture is the following :

Paraffin 2 parts,
Vaseline 1 part.

This is transparent enough to enable the position of the imbedded tissue to be made out ; it penetrates tissues well, is consistent, cuts easily, and is readily soluble in carbolic acid and turpentine.

If a harder imbedding material is required a little more paraffin may be added.]

STAINING.**Hæmatoxylin.** (Prepared according to Kleinenberg.)

1. Take crystallized calcium chloride and add it in excess to 70 per cent. alcohol; shake well and let it stand. Draw off the saturated solution and add alum to excess, shake up and let stand. Filter.

2. Make a saturated solution of alum in 70 per cent. alcohol by the method above given for calcium chloride. Add this to the filtrate in 1 in the proportion of 8 to 1.
3. To the mixture thus obtained, add drop by drop a saturated solution of hæmatoxylin in absolute alcohol, till it is a *moderately* dark purple. In dissolving the hæmatoxylin in absolute alcohol remember that it is very soluble, and use as little as possible of the spirit.

The solution will become considerably darker after some days. It is better to make it some weeks before it is required for use.

It may be diluted to any extent required with the mixture of (1) and (2), but as a rule a tolerably quick staining is preferable. If a section is placed in hæmatoxylin for some time it must of course be covered up, or the spirit will evaporate and the solution become concentrated. In many cases it is well to stain a piece of tissue as a whole in hæmatoxylin before imbedding; a tolerably porous tissue naturally serves best for this method. A small piece only should be taken.

If a section which it is wished to preserve has been stained too deeply, the colour may be partially extracted by placing the section in dilute acetic acid. At the same time it must be remembered that the acetic acid will exert its own proper action on the tissue.

The hæmatoxylin after it has been used should be put aside in a separate bottle, since after filtration it may be used again.

An aqueous solution of hæmatoxylin may also be used; but in this fungi readily grow; it does not penetrate well, so that it is not a favourable fluid for staining tissues before imbedding, it does however stain the nuclei more and the protoplasm less relatively to Kleinenberg's hæmatoxylin.

Carmine. (Frey's method.)

<i>a.</i>	Carmine	0·3 gm.
	Glycerine	30·0 „
	Alcohol	4·0 „
	Distilled water	30·0 „
	Ammonia	q. s.

Add the distilled water to the carmine, and then add dilute ammonia drop by drop until the carmine is dissolved, taking care that the least possible excess is added. If the solution smells strongly of ammonia expose it in a flat vessel to the sunlight for a day or two. Finally add the glycerine and alcohol, and shake. It should be kept in a stoppered bottle, since otherwise the ammonia evaporates and the carmine is precipitated.

It may be diluted with water to any extent required.

For staining fresh tissue the carmine may be prepared thus:

- b.* Mix in a mortar 1 gm. of carmine with a little water into a thin paste; add ammonia, drop by drop, till the whole is lake-red, then add 100 cc. of water, and evaporate on a water-bath till the excess of ammonia is evaporated off, and the carmine begins to be precipitated: filter. The excess of ammonia must be got rid of, otherwise the staining becomes diffuse.

This solution will not keep long, and fungi readily grow in it.

As a rule tissues stain better with carmine when they are left in a dilute solution for 12 to 24 hours.

The following method (Heidenhain) frequently gives good results.

The sections to be stained are placed in a watch-glass under a bell-jar, with very dilute carmine prepared as in (*b*). Under the bell-jar there is also placed a dilute solution of ammonium carbonate. The staining is complete in about twenty-four hours.

Most preparations stained with carmine are best preserved in glycerine containing 1 p. c. formic acid 1.16 Sp. Gr.

Picrocarminate of Ammonia or Picrocarmine.

Prepare a saturated solution of picric acid, and to it add a saturated ammoniacal solution of carmine till a precipitate occurs. Evaporate in a water-bath till the volume is reduced by four-fifths. Filter, and evaporate the filtrate to dryness. A crystalline mass of picrocarmine is thus obtained. It dissolves readily in distilled water; a 1 to 5 p. c. solution should be made, and further diluted as occasion requires.

A great deal of the yellow colour may be removed from tissues stained with picrocarmine by careful washing with water.

Iodine.

Dissolve 2 grms. of iodide of potassium in 100 cc. of distilled water, and add flakes of iodine to slight excess.

Aniline blue-black.

Dissolve 5 grm. of aniline blue-black in 100 cc. of water.

This may be diluted with water to any strength required.

It may also be dissolved in 90 p. c. spirit, to stain tissues that have been placed in spirit.

Gold Chloride.

The method of using this is for ordinary cases sufficiently given in the text (Lesson v. B, § 4).

The following rather complicated method is used by Gerlach to trace fine nerve-fibres in the spinal cord.

The fresh spinal cord is placed from fifteen to twenty days in a 1 to 2 per cent. solution of ammonium bichromate at a low temperature.

Sections are cut and placed in a .01 per cent. solution of the double chloride of potassium and gold *very* faintly

acidulated with hydrochloric acid for ten to twelve hours in the dark. They should be then of a pale lilac colour.

They are washed in hydrochloric acid .05 per cent., and then left for ten minutes in a mixture of one part of hydrochloric acid to one thousand of sixty per cent. alcohol, and finally placed for a few minutes in absolute alcohol, cleared and mounted in Canada balsam. The nerve-fibres are most distinct in three or four days.

Silver Nitrate.

This is used mainly to trace out flat tessellated epithelium, such as that of arteries, veins, or lymphatics. By exposure to light, the silver is reduced in very fine granules; in a fresh tissue that has been placed in nitrate of silver the reduction on exposure takes place more readily in the homogeneous substance between the cells or 'cement substance' than in the cells.

The tissue should be washed *rapidly* with water to remove sodium chloride before placing in silver nitrate.

As a consequence, where there is a single layer of cells with a small amount of cement between them, the reduced silver in this substance marks very distinctly the outline of the cells.

The success of silver preparations largely depends upon not dragging the tissue, and on washing it well before it is exposed to the light.

The reduction of silver goes on slowly in the other parts of the tissue, so that it becomes darker and darker, until it is useless; this is rendered less rapid by mounting.

MOUNTING.

Some fresh and nearly all hardened tissues are too opaque even in thin sections to enable a satisfactory microscopic examination of them to be made. They are accordingly placed in some fluid which will thoroughly penetrate them and render them more transparent,

Glycerine.

This causes fresh tissues to shrink considerably, since by exosmosis the water is drawn out of them; hence they should never be mounted in concentrated glycerine; if, however, they are not sufficiently transparent they may be mounted in it when diluted with two parts of water. Even with hardened tissues it is often better to use a mixture of equal parts of glycerine and water: in the text this is called *dilute glycerine*.

When spirit is used in cutting sections, it is best to allow them to soak about ten minutes in glycerine before mounting, so that the glycerine and alcohol may thoroughly mix.

Glycerine, besides clearing the tissue, acts as a preservative agent; specimens mounted in it may be kept for a considerable length of time. When it is desired so to preserve a specimen, care should be taken that the drop of glycerine is of such a size that the simple pressure of the cover-glass will cause it to spread out just to the edges of the cover-slip; the glass slide round the cover-slip and the edges of the cover-slip should be overlaid with tolerably consistent Canada balsam. If too large a drop of glycerine is taken, so that it spreads out past the edges of the cover-slip, the Canada balsam will not stick to the glass. In this case it is generally less trouble to remount the section than to wipe away the superfluous glycerine.

Clearing with Carbolic Acid and Turpentine.

Add 1 part of carbolic acid to 4 of turpentine. The carbolic acid may be replaced by creosote; in this case shake well and set aside till the cloudiness, which forms on mixing the liquids, disappears. This mixture is used for stained and injected sections which it is desired to render very transparent; they must be mounted in Canada balsam. The carbolic acid (or creosote) is the clearing agent, but this alone cannot be used since it does not dissolve Canada balsam, accordingly turpentine is added, which mixes with

the acid and also dissolves the balsam. Gently warming in carbolic acid and turpentine hastens the clearing.

Before mounting sections all superfluous fluid should be removed by means of a piece of blotting paper with the edge not torn but cut clean.

Injected specimens should, as a rule, be cleared with carbolic acid and turpentine; if soluble Berlin blue has been used as the injection material, it is advisable to leave the sections in a little turpentine in an uncovered watch-glass for a day to restore the colour which probably has been weakened by alcohol.

Canada Balsam.

Put some Canada balsam into a capsule and place it in the warm chamber at about 65° C. for twenty-four hours to drive off all water. Let it cool and dissolve it in a small quantity of benzole; it should be kept in a bottle with a ground glass cap fitting over the neck of the bottle, instead of a stopper, as the stopper is apt to become fixed in the bottle; the neck of the bottle should be rubbed round with lard, to prevent the cap sticking. Dammar may be used instead of Canada balsam.

Canada balsam renders tissues much more transparent than glycerine.

Tissues stained in carmine or any watery solution should be placed in absolute alcohol previously to being mounted in Canada balsam. It is however most used for tissues which have been cleared with carbolic acid and turpentine.

Acetate of Potash.

A saturated solution of this is often used to mount osmic acid specimens in.

GENERAL DIRECTIONS.

Mounted specimens may be preserved temporarily by heating the end of a small wax taper in a flame, and smearing the wax round the cover-slip by the aid of the wick.

Fresh specimens should be teased out or examined in normal solutions.

Osmic acid specimens should be teased out in the fluid itself or in water.

Potassium bichromate and ammonium bichromate specimens should be teased out in the fluid itself; dilute glycerine may also be used, but is commonly not necessary.

Chromic acid specimens should be teased out in water or dilute glycerine.

Sections hardened in potassium bichromate, chromic acid, &c. when unstained should be mounted in glycerine.

When stained they should be mounted in glycerine or cleared and mounted in Canada balsam.

Gold chloride specimens should be mounted in glycerine; to diminish the continued reduction of gold they may be kept in the dark.

Silver nitrate specimens should be cleared and mounted in Canada balsam.

Never mount in glycerine sections cleared with creosote and turpentine.

CHEMICAL REAGENTS.

Millon's reagent.

Weigh out 50 grms. of purified mercury and an equal weight of pure strong nitric acid. Place the mercury in a flask in the closed chamber, add the nitric acid to it, and leave the mixture as long as any chemical action continues. If all the mercury is not dissolved warm it *gently* to complete the solution.

Add then to it twice its volume of water, and place aside for some hours; a white crystalline precipitate will fall; the supernatant fluid is Millon's reagent.

Fehling's fluid.

(a) Dissolve 34.65 gm. of pure crystallized cupric sulphate in about 160 cc. of distilled water.

(b) Dissolve also 173 gm. of pure crystallised potassic-sodic tartrate in 600 to 700 gm. of sodic hydrate sp. gr. 1.12.

Add (a) to (b) stirring well to cause a thorough mixture, and dilute with distilled water to a litre.

Fehling's fluid should be fresh made whenever it is required, since it decomposes on keeping; it will keep some little time if kept in a cool place in the dark and in completely filled well-closed bottles (Hoppe-Seyler).

The solution (b) may be prepared and kept for adding to (a) freshly prepared when required.

Before using a kept solution to test for sugar, always boil a little of it by itself to see if any reduction will take place.

From 1 cc. of this solution the copper is completely reduced by .005 gm. of grape-sugar.

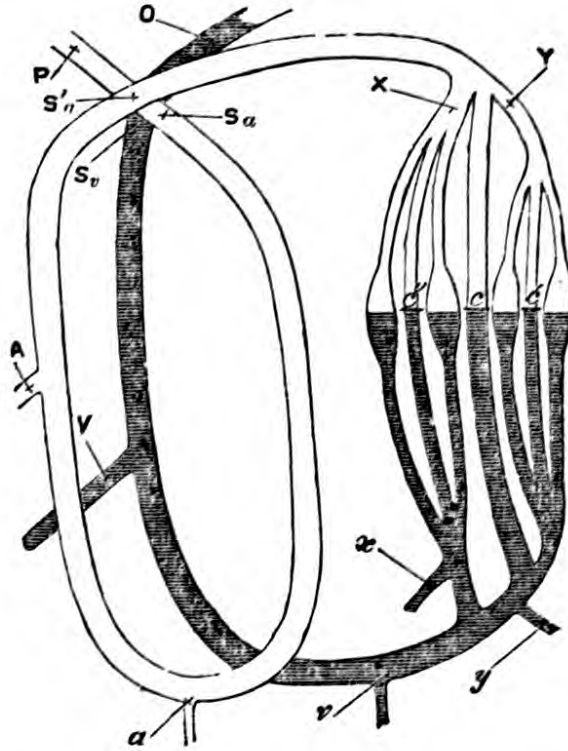
Stokes' fluid.

This should be made afresh when required; it consists of a solution of ferrous sulphate, to which ammonia has been added after the previous addition of sufficient tartaric acid to prevent precipitation. An excess of tartaric acid is not of consequence; roughly speaking, three parts by weight may be added to two parts of ferrous sulphate.

MAJOR ARTERIAL SCHEME.

This (see Fig.) is a modification of Weber's original scheme of the circulation. It is not intended to imitate the details of the circulation of the blood, but simply to illustrate the points to which attention is called in Lesson XIII. It can without much difficulty be made by joining together india-rubber tubing by means of three-way glass tubes.

Clamps are placed upon the straight tubes c , c' , c'' , and the dilated tubes along the same line are stuffed with sponge, until on closing the clamps and pumping steadily, a mean pressure of two or three inches of mercury is obtained in the artery tube.



The artery tube P is connected with an egg-shaped india-rubber bag; from the opposite end of which a tube passes to a vessel full of water. The bag has two valves, one at each end, opening in the same direction, so that when it is compressed with the hand the water it contains is driven onwards through the artery tube, and on its dilating water is drawn up from the vessel.

Any other form of pump can be used.

At S_a , S_a' , S_a'' , are placed vertically above one another either the usual sphygmograph levers or light levers such as are used to take tracings of the movements of the frog's heart (Lesson XII. B). The tubing can be supported on pieces of lead fastened to a stand, and bent to fit its course. Each

of the tubes *A* and *V* communicates with a mercurial manometer (Hdb. p. 210).

The rest of the scheme requires no further explanation than is given in the text.

MINOR ARTERIAL SCHEME.

This consists of an india-rubber bag like that used in the major arterial scheme. By means of a three-way tube the end of this towards which the valves open is connected both with a piece of glass tubing about a yard and a half in length, and with a piece of india-rubber tubing of similar length and bore.

There are clamps upon the long india-rubber tube close to its junction with the three-way tube and upon the small piece of india-rubber which connects the three-way tube with the glass tube, so that the flow of water may be through either the glass or the india-rubber tube.

A small piece of india-rubber tubing is also placed on the end of the glass tube, into which a tube finely drawn out can be inserted.

PITHING.

If it is desired to pith a frog, place it under a small bell-jar with a sponge moistened with ether; when the animal is motionless and under the influence of the anæsthetic, take it up in a cloth, hold the hind legs between the third and fourth fingers, and with the fore-finger press down the head. Cut transversely through the skin a little behind the skull with a pair of scissors, carrying the incision only a short way on either side of the median line; make a slight incision also through the skin in the median line. The end of the occipital bone can then be easily made out; it is just above the level of the anterior edges of the scapulæ. With a sharp scalpel cut through the muscles just behind the occipital bone and as nearly as possible in the median line, so as not to cut the

vertebral arteries ; the spinal cord will be exposed. Thrust then a blunt stout needle into the brain and move it about so that the brain is quite destroyed.

The following rough table may be useful to the student.

1 litre	= 1 cubic decimetre = $1\frac{3}{8}$ pints.
1 cubic inch	= 16·39 millilitres or cubic centimetres.
1 cubic foot	= 28·32 litres.
1 gallon	= 4·54 litres.
1 gram	= 15·43 grains.
1 kilogram	= 32·15 Troy oz. = 35·27 Avoird. oz.
1 grain	= 0·065 gram.
1 Troy ounce	= 31·1 gram.
1 pound (Avoird.)	= 0·45 kilogram.
1 centimetre	= $\frac{2}{5}$ inch.
1 metre	= 1 yard $3\frac{1}{3}$ inches.
1 inch	= 2·54 centimetres.
1 foot	= 3·05 decimetres.
1 yard	= 0·91 metre.

INDEX.

A.

- Accessory nerve, 10, 21
 Accommodation, (vision), 188
 Adam's apple, 229
 Adenoid tissue, 122, 123, 124, 131, 133, 144
 Agents, hardening, 245
 Albumin, acid, 118; of egg, 118; milk, 121; saliva, 113; serum, 34, 118; test for, in urine, 161
 Albuminate, alkali, pancreatic juice, 129
 Alcohol, 245, 246, 249
 Alveoli, glands, œsophageal, 110; lymphatic, 132, 133; pulmonary, 146; salivary, 110, 111; splenic, 134; tracheal, 144
 Ammonis, cornu, 222
 Ammonium bichrom. sol., 247, 248; neutral amm. chromate, 245
 Ammonium chromate, neutral, 245
 Ampulla, dilatation, 201, 203; dissection of, 202
 Aniline blue-black, 255
 Appendix of the cæcum, 2, 5
 Aqueduct of Sylvius, 226
 Aqueductus Fallopii, 207
 Arachnoid of dog, 9
 Arantii, corpus, 94
 Arbor vitæ, 226
 Arterial scheme, major, 100, 260; minor, 99, 262
 Arteries, aorta, arch, 14, 91, 92, 94; bulb, 95, 97; dorsal, 3, 12; basilar, 10, 215, 220; carotid, common, 13, 14, 16; internal, 215, 220; cerebral, anterior, 221; middle, 221; posterior, 220; transverse communicating, 221; circle of Willis, 10, 221; cœliac, 3; coronary, 94; innominate, 14; mesenteric, superior, 3; pulmonary, 15, 91, 92, 93, 94; alveolar, 146; renal, 157; subclavian, 14; vertebral, 220; structure of, 83, 85, 243; epithelium of, 256; pulsation in, 88; blood-flow from, 102, 104; in normal, 88; abnormal, 89
 Arytenoid, cartilage, 23, 228, 230; muscle, 230, 231
 Astigmatism, 191
 Auditory nerve, 10
 Auricle, frog, 94, 95, 97; sheep, left, 94; right, 91
 Auricular nerve, great, 18; posterior, 19
 Automatic action, 80
 Axis cylinder, 71, 76, 168, 170, 213, 214

B.

- Baryta water, 245
 Basement membrane, œsophagus, 109; large intestine, 125; stomach, 107; epidermis, 165; hair follicle, 166; glands, Brunner's, 125; gastric, 107, 108, 109; Lieberkühn, 123; pulmonic alveoli, 146; tubuli recti, 155, 156, 157
 Bile, capillaries, 140; ducts, 139, 140; salts, 127; constituents and reaction, 126; properties of, 127; test, Gmelin's, 126, 161; Pettenkofer's, 127; for acids in urine, 161
 Bladder, of rabbit and dog, 8; structure of, 157; muscular fibres of, 60; preservation of, for micros. exam., 8
 Blind spot, 193
 Blood, crystals, 151; pressure, 99; coagulation of, 31; colour of, 148; serum of, 33, 244; structure of, frog and newt, 24; human, 29
 Blood-vessels, in iris, 184; kidney, 154, 156; lung, 143, 145; optic

- thalamus, 218; pia mater, 216; retina, 181, 193, 194, 195; skin, 166; spinal cord, 210, 212; testis, 126; structure and properties of, 83, 85
- Bone, hyoid, 22, 229; turbinated, 22; microscopic examination, 40; softening, 42, 249
- Boracic acid (action on frog's blood), 28
- Brain, dissection of, 215; convolution of, 219, 220
- Brain of, rabbit, 8; dog, 8, 215; sheep, 215
- Brownian movement, 116
- Brunner's glands, 125
- Bulbus arteriosus, 95, 97
- C.
- Cæcum (dog), 6
- Calamus scriptorius, 216
- Calf, spinal cord, 212
- Canada balsam, 258
- Canaliculi, 41, 43
- Canaliculi, of Haversian System, 42, 43
- Canal, of Schlemm, 182; central (cord), 211, 212, 216
- Capillaries, of, bone, 42; kidney, 157; liver, 140; lung, 146; lymphatic glands, 132; lymphatic vessels, 136; Peyer's patches, 132; retina, 195; villus, 123, 126; blood flow in, normal, 89; abnormal, 89; epithelium of, 137; resistance in, 102, 103; structure of, 86
- Capsule, lens, 180; Malpighian, 153, 154, 156; Pacinian, 170; spleen, 133
- Carbolic acid, 257
- Carmine staining, 254
- Cartilage, of cuttle-fish, 40; arytenoid, 23, 54, 230, 231; costal, 12; cricoid, 23, 229; epiglottis, 22, 228; inter-articular, 17; thyroid, 23, 229; microsc. exam. of, bronchial, 145; costal, 39; elastic, 54; fibro, 52; hyaline, 52, 54, 55; parenchymatous, 40, 54; tracheal, 144
- Casein, 120, 121
- Castor oil and spermaceti, 252
- Cat's, ear, 204; dissection of, 205; gastric mucous membrane, 108; ileum, 122; mesentery, 170; ovary, 235; stomach, 106; testis, 238
- Cells, columnar (ear), 203, 208; cubical, 208, 209
- Cement, of teeth, 43
- Cerebellum, of rabbit, 9; of dog, 9, 215; sheep, 215, 216, 217, 218, 226
- Cerebrum, 215; crura of, 218
- Cervical nerves, 3rd, 19, 2nd, 19
- Chiasma, optic, 219, 221
- Chorda tympani, 18, 20, 21
- Chordæ tendineæ, 93
- Choroid coat, ox or sheep, 179, 180, 181, 182, 185, 186; plexus (4th vent.), 216; lateral ventricle, 222, 223, 224
- Chromic acid sol., 245, 247
- Cilia, frog's structure, 56; automatic action, 82
- Ciliary muscle, 179, 182; processes, 179, 180, 181, 182; portion of retina, 180
- Circulation, of frog, 88
- Cisterna magna lymphatica (frog), 136
- Clearing (of sections), 257
- Coagulation, of blood, 31
- Cochlea, protuberance of, 205; axis of, 208; coils, 207; of guinea-pig, 207
- Colloid body (Pacinian), 170
- Column, anterior, 211, 213; lateral, 211, 213; and posterior (spinal cord), 211; Clarke's, or posterior vesicular, 212
- Columnæ carneæ, 93
- Commissure, grey cord, 211; white, 211, 213; optic, 219, 220, 221; cerebral, anterior, 225, 227; middle (3rd vent.), 225, 227; posterior cerebral, 225, 226, 227
- Cones, retina, 186
- Conjunctiva (ox or sheep), 178; cornea, 182
- Connecting tubules, 155, 156
- Connective-tissue, 106, 107, 110, 166; fibres (elastic), 45, 83, 85; (fibrillæ proper), 45, 51; perineurium, 70, 75, 76, 170; of sheath of ganglionic corpuscles, 74, 75, 76; of lymphatic glands, 132, 133; of splenic pulp, 134; corpuscles (fixed), 46, 51, 123, 166; of capillaries, 86; of lung, 143; of trachea, 144; of kidney, 156; of cornea, 182; subcutaneous con. tiss., 166; con. tiss. of papilla (hair-follicle), 167; of olfactory mu-

- cous, 174; of choroid, 181; of cornea, 46, 182, 183; of iris, 184; of retina, 186; of pia mater, 210; of spinal cord, 211, 212; connective tissue, corpus luteum, 235; of testis, 236; fine fibrous connective-tissue, testis, 237, 238
- Contractile tissues, 56
- Contraction, single, in muscle, 63, 66; in heart, 94
- Contrast, simultaneous, 198
- Convolution of brain, 219, 220
- Cord, vocal, 22, 23, 228, 231; spinal, 210, 215, 216; micros. exam. of, 76; medullary (lymph. alveolus), 133
- Cornea, ox or sheep, 178, 181, 182; connective-tissue corpuscles of (frog), 46; nerve plexus of frog, 168; conjunctiva of, 178; microsc. exam., 182
- Cornua, anterior, 211, 212, 213, 214; and posterior (cord), 211, 212, 213, 214; of lateral ventricle, 222, 223; cornu Ammonis, 222
- Corpora quadrigemina, 217, 224; geniculata, 225
- Corpus, Arantii, 94; callosum, 217, 222, 224, 226; albicans, or mammillare, 218, 224, 226; striatum, 222, 225; fimbriatum, 223; dentatum, 226; luteum, 233, 235; Highmori, 236, 238
- Corpuscles, blood-, 55, 86; of frog or newt, red, 24, 89, 90; colourless, 27, 89, 90; of man, red, 29; mammalian, red, 134, 149; colourless, 30; of cartilage, 37, 52; ganglionic, 74, 75; salivary, 116; touch, 169; of connective tissue (fixed), 46, 51, 123, 166; (of capillaries), 86; of cornea, 46, 182, 183; white corpuscles (corpus luteum), 235
- Cortex (lymph. gl.), 132; kidney, 153, 154, 156; ovary, 232, 233
- Corti, inner and outer rod of, 208; organ, 209
- Creosote, 257, 259
- Crico-thyroid, 229; -arytenoid, posterior, 230; lateral, 230
- Crista acustica, 202, 203
- Crucial sulcus, 219
- Crura cerebri, 218
- Crural artery, vein, and nerve of rabbit, 18
- Crusta petrosa, 43
- Cumulus proligerus, 234, 236
- Current, constant, 62, 176; interrupted, 64, 66
- Cuttle-fish, cartilage of, 40
- Cylinder, axis, of nerve-fibre, 71, 76, 168, 170, 213, 214
- D.
- Dammar, gum, 258
- Demilune cells, 111
- Demours, membrane of, 183
- Dentary nerve, inf. (dog and rabbit), 21
- Dentine, 43
- Dermis, 166, of tongue, 175
- Descemet, membrane of, 181, 183
- Descendens noni, of dog and rabbit, 13
- Dialyser, 115
- Diapedesis, through veins, 90
- Diaphragm, of dog and rabbit, 4, 10; structure in rabbit and guinea-pig, pleural and peritoneal, 137
- Diastole, 95
- Dicrotic wave, 102
- Diffusion, (vision), 189
- Digestion, of fibrin, 117, 118
- Directions, use of microscope, 241; observations of fresh tissues, 243; general, 259
- Disc, optic, 193
- Dissection, of dog and rabbit, abdomen, 1, 11; cranium, 8, 18; thorax, 11; neck, 12, 18; knee-joint, 16; of a muscle, 16, 17; of sub-maxillary region, 20; of nasal cavity, 22; of larynx, 22, 228; of eye, 23; of brain, 215
- Dog, dissection of, 1; arachnoid of, 9; differences from rabbit, 16; stomach, 107; gastric mucous membrane, 108; ileum, 122; bladder, 157; ureter, 158; lens of, 183; spinal cord (microsc. exam.), 210, 211; dissection of brain of, 215; of larynx of, 228; ovary, 235; testis of, 237
- Double image, 189
- Duct, hepatic and cystic, of dog and rabbit, 4, 138, 140; Stenon's, 18; sub-maxillary, 20; sublingual, 20; of salivary lobules, 110; of glands of Brunner, 125; of mucous glands (trachea), 144

- Duodenum, of dog and rabbit, 2, 6;
structure of, 125
- Dura mater, of dog and rabbit, 9
- E.
- Ear, cartilage of, 40; dissection and
structure of; fish, 201; mammal,
204; anterior and posterior canals,
202; membranous canals, 201;
vestibule and semicircular, 201,
207
- Eighth cranial nerve, of dog and rabbit,
10, 222
- Elastic fibrous tissue, 45, 83, 85;
laminae, 85
- Elasticity of muscle, 66
- Eleventh cranial nerve, of dog and
rabbit, 10, 222
- Enamel, 43, 44
- Epidermis (human scalp), 165, 166,
167, 168; horny (tongue), 175
- Epididymis, of dog and rabbit, 7;
prep. for micros. exam., 8, 236, 237,
238
- Epiglottis, 22, 228
- Epithelium, ciliated (frog), 56, 82;
sinuous of capillaries, 137; of arte-
ries, 84; of veins, 85; ovoid or pep-
tic (gastric gland), 107, 108, 109;
central cells, or polyhedral or
cubical, 107, 108, 109; spheroidal,
110; conical cells, ileum and je-
junum, 122, 124; goblet cells,
ileum, 122; olfactory region (newt),
174; peritoneal (frog), 136; rab-
bit and guinea-pig, 137; of lymph-
atic capillaries, 137; of lymph-
atic vessels, 137; pleural of lung
(newt) flat, 142; columnar cili-
ated, trachea, 145; infundibulum
(lung), 145; epithelial cells (isolating),
245; flat or tessellated, 256; cubical
of tubuli recti, 155; of Malpighian
capsules, 154; of glomerulus, 154;
imbricate of looped tubes of Henle,
155; of the various kidney tubules,
156; ciliated columnar (vas de-
ferens), 239; epithelium of bladder
(mucous coat), 157, 158; epithe-
lium (superficial or germinal) (cortex
of ovary), 233; ciliated cylindrical
(vasa efferentia epididymis), 238;
cubical or flat (parovarium), 235;
tessellated epith. (tunica vaginalis),
237; tabular or cubical epith. (tubuli
seminiferi) corpus Highmori, 238;
columnar (gastric glands), 107, 110;
(oesoph.), 109, 110; (salivary ducts),
112; (glands of Lieberkühn), 123;
ducts of glands of Brunner, 125;
large intestine, 125; bile ducts, 139,
140; of tubuli recti, 155; gland-tube
(sweat), 168; of cornea, 169; cylin-
drical (newt's mucous membrane of
nose), 173; non-olfactory portion
cylindrical and ciliated, 174; olfac-
tory, outer layer, inner layer, 174;
anterior of cornea, 182; posterior
of cornea, 183; fibrous (lens), 183;
central canal (cord), 211; epithelial
layer (internal and third ventricles),
224; columnar epithelium (cortex
ovary), 233; ovum, 234
- Estimation, quantitative, urea, 162;
sugar, 163; weight, 171
- Eustachian tube, 22, 207; valve, 93
- Exhaustion of muscle, 67
- Eye, of dog and rabbit, prep. of, 10;
of frog (cornea), 46; dissection of
(ox or sheep), 178; aqueous humour
of, 244
- F.
- Facial nerve, of dog and rabbit, 10,
18
- Falx cerebri, of dog and rabbit, 9
- Fascia lata, of dog and rabbit, 16
- Fasciculus, slender, (cord), 211, 214
- Fat-cells, 50, 51
- Fehling's fluid, 260
- Fenestra ovalis, 207
- Fenestrated membrane, 186
- Ferment (in blood, prep. of), 35; in
saliva, 115; in milk, 120; amylo-
lytic, 128; proteolytic, 128, 129;
in urine, 159
- Ferrein, pyramids of, 153, 154, 155,
156, 157
- Fibrin of blood, 31; digestion of,
(gastric juice), 117, 118, 128; pan-
creatic, 129; -ferment, 34, 35
- Fibrinogen, 34
- Fibrinoplastin, 34
- Fifth cranial nerve of dog and rabbit,
10, 221; gustatory, 20; ventricle,
223
- Fimbriatum, corpus, 223
- Fissure, Glaserian, 21; anterior (spi-

- nal cord), 210, 221; posterior spinal cord, 210; transverse (cerebrum), 217, 224, 226; Sylvian, 221
- Fluid, serous, 33; of hydrocele, 33, 34; pericardial, 34; normal, for microsc. observ., 244; dissociating, 245; Müller's, 245, 248; Fehling's, 260; Stokes', 260
- Fœtus, lung, structure of, 145
- Follicles, closed, ileum, 124; duodenum, 125; of lymphatic gland (closed), 131; hair-, 166; Graafian, 232, 233, 234, 235
- Foramen, jugular, 21; condyloid, 22; of Monro, 223; rotundum, 205
- Fornix, 223, 224, 226, 227
- Fossa ovalis, sheep, 92
- Fourth cranial nerve, 10, 217, 221; ventricle, 216, 217
- Frey's carmine, 254
- Frog, micros. exam. of, (blood), 24; tendon, 45; connective-tissue, 45, 48; pigment-cells, 49; ciliated cells, 56; goblet cells, 56; muscular fibre, (striated), 57; constant current in muscle, 62; single induction shocks on muscle, (single contraction in spasm), 63; tetanus of muscle, 64, 66; muscle, stimulation of, (chemical), 65; (mechanical), 65; muscle curve, 65; reaction, 67; micros. exam. of nerve-fibre (spinal), 70; Gasserian ganglion, 74; (of posterior root), 74; reflex action in, 77; automatic action in, 80; circulation in, 88; heart of, 81, 94; lymph-hearts of, 80; cisterna magna lymphatica, 136; lung, structure of, 143; cornea (nerve plexus), 168; cornea of (microsc. exam.), 182; retina of, 186; spermatozoa of, 239; to pith, 262
- Fusca, lamina, (choroid), 179
- G.
- Gall-bladder, 4
- Ganglia, Gasserian, of frog, 74; of posterior root, 74; of sympathetic, 75; cardiac (frog), 98
- Ganglionic layer (retina), 185; cells of, 187
- Gasserian ganglion, of dog or rabbit, 23; of frog, 74
- Gastric juice, artificial, prep. 116; action of, on fibrin, 117; on milk, 119
- Geniculata, corpora, 225
- Gerlach's method (fine nerve-fibres), 255
- Germinal epithelium, 233
- Germinal vesicle, 234, 236; spot, 236
- Glands, ductless, supra-renal body of dog and rabbit, 3, 7; submaxillary, 16, 20; thymus, 13; parotid, 18; sublingual, 20; gastric, 107; mucous, 110; salivary structure of, 110; of Lieberkühn, ileum and jejunum, 123, 124; duodenum, 125; large intestine, *ib.*; of Brunner, *ib.*; sweat-gland, 125, 168; lymphatic, 131; mucous (trachea), 144; sebaceous, 167; mucous (olfactory region), 174; pineal, 224, 225, 226; serous, structure of, 112
- Glandular substance (lymph alveolus), 133; (spleen), 134
- Glaserian fissure, 21
- Glomeruli, 153, 154, 157
- Glossopharyngeal, of dog and rabbit, 10, 21, 22
- Glottis, 22; rima of, 228
- Glucose, 142
- Glycerine, 257, 259
- Glycerine, extract of, gastric juice, 116; pancreatic, 128
- Glycogen, 141, 142
- Gmelin's test for bile-pigment, 126, 161
- Gold chloride (use of), 39, 47, 48, 73, 75
- Gold chloride sol., 247, 255, 259
- Graaffian follicles, 232, 233, 234, 235
- Granules, movements, Brownian, 116
- Guinea-pig, cochlea, 207; diaphragm, and peritoneum (microsc.), 137; diaphragm and pleura, *ib.*; blood colour, 148, 149; testis of, 236
- Gustatory nerve (dog and rabbit), 20, 21; organs, structure of, 175
- Gyrus, sigmoid, 220
- H.
- Hæmatoidin, 235
- Hæmatoxylum, 208, 252
- Hæmoglobin, 148; reduced, 150; carbonic oxide, 151, 152
- Hair-follicles, 166, 208
- Hardening, 245

Haversian, system, 41; canals, 41, 43; spaces, 41
 Heart (rabbit and dog), anat., 15, 16; lymph (frog), automatic action, 80, movements, 94; of sheep, structure of, 90
 Heidenhain's carmine staining, 254
 Helmholtz's phakoscope, 191
 Henle, looped tubes of, 155, 156
 Hilus, lymph. gl., 132; ovary, 232
 Hippocampal convolution, 220
 Hippocampus major, 222
 Humour, aqueous, 179; vitreous, 179, 180
 Hyaline border of cells, 57
 Hydrocele fluid, 33
 Hydrophilus, structure of muscle, 58
 Hyoid bone, 22, 229
 Hypoglossal, of dog and rabbit, 10, 19, 20, 21, 22

I.

Ileum, structure of, 121
 Imbedding, 249
 Imbedding substance, 143
 Incus, 206
 Infundibulum, in lung, 145; cerebral, 218, 225
 Inhibition (pneumogastric), 97
 Interglobular spaces of teeth, 43
 Inter-lobular, liver vein, 139, 140; arteries, kidney, 157
 Intestine, large, of dog and rabbit, 2; prep. for microsc. exam., 7; structure of ileum and jejunum, 122, 124; duodenum, 126; large intestine, 126
 Intima, tunica, 87
 Intra-lobular vein, 139, 140
 Iris (ox or sheep), 179, 180, 181, 182; ligamentum pectinatum of, 181; microsc. exam., 184
 Irradiation, 192
 Isolation of cells, 245

J.

Jejunum, of dog and rabbit, 2, 7; prep. of for microsc. exam., 7; structure of, 124

K.

Kidney, of dog and rabbit, 7; prep. for microsc. exam., 8, 245; structure of, 153, 243

L.

Lacteal radicle, villus, 123
 Lacunæ, of Haversian system, 41, 43
 Lamellæ, of Haversian system, 41
 Lamina, elastic (arteries), 85; fusca (choroid), 179; fibrous, cornea, 183; spiralis, 207, 209
 Laryngeal nerve, superior, of dog and rabbit, 13, 19; recurrent, 14
 Larynx, 22, 223
 Lateral ventricles, 222, 226
 Lens (ox or sheep), 179; -capsule, 180; microsc. exam., 183; accommodation, 190
 Leucocytes, stomach, 107; ileum, 124; lymphatic glands, 131, 133; spleen, 135
 Lieberkühn, glands of, 123, 124, 125
 Liebig's quantitative estimate of urea, 162
 Ligament, capsular of knee, of dog and rabbit, 17; lateral of knee, of dog and rabbit, *ib.*; crucial of same, *ib.*; of neck, 45; suspensory (eye), 180; pectinating of iris, 181
 Ligamentum teres (junction with femur), 53
 Light, sensation of, 196, 197
 Limit, near (vision), 190, 192; far, 190, 192; outer and inner upper and lower of blind spot, 193
 Linea alba, of dog and rabbit, 1
 Lingual nerve, (dog and rabbit), 20, 21
 Liver, of dog and rabbit, prep. of, for microsc. exam. 5; structure of, 139
 Localisation, power of (touch), 170
 Lumen, central (gastric glands), 108, 109; salivary, ducts, 110; alveoli, 111; glands of Lieberkühn, 123; glands of Brunner's ducts, 125; tubuli contorti, 154; tubuli recti, 155; tubuli seminiferi, 236; epididymis and vasa efferentia, 238
 Lung, of dog and rabbit, 11; structure of, 143
 Lymphatic, epith. of, 131; glands, 131; vessels, 133, 136, 137; epithelium, 137; capillaries, origin of, 138
 Lymphatic glands in mesentery, 3

- Lymph-hearts—frog, automatic action, 80; dorsal lymph-sac (frog), 80; -gland from mesentery, 132; -sinus (lymphatic gland), 131, 132; -corpuscles (Graaffian vesicles), 235
 Lyra, 224
- M.
- Magnifying power, determination of, 242
 Malleus, anterior and posterior ligament of, 205; axis band, 206
 Malpighian bodies, or capsules, spleen, 134, 154; corpuscles, 135; kidney, 153, 157; pyramids, 153, 157; layer (epidermis), skin, 165, 166, 167, 168, 169; tongue, 175
 Manometer, mercurial, 100
 Marginal zone (kidney), 154
 Matrix, of cartilage (hyaline), 37, 54, (elastic), 39; touch-corpuscles, 169
 Maxillary, nerve, inferior, 21, 23; superior, 23
 Maxwell's method (yellow spot), 195
 Measures and weights, 263
 Meatus, auditorius ext., 22
 Mediastinum, 12
 Medulla, oblong. of rabbit, 8, 9; dog, 9, 215, 216, 217; sheep, 215, 216, 217; of lymph gland, 132; of kidney, 153, 156; of nerve, 70, 71, 72, 168, 170, 213; of ovary, 232
 Medullary cord (lymph, alveolus), 133
 Membrana, basilar, 208, 209; propria (see "basement membrane") limitans interna retinae, 180, 203; thyro-hyoidean membrane, 229; crico-thyroid m., 229; granulosa, 234; tympani, 206; tectoria, 209
 Mesentery, of dog and rabbit, 2
 Microscope, use of, 241
 Milk, digestion of, 119; exam. of, 120; fermentation of, 120; -sugar, 120; alkaline phosphates, 121
 Millon's reagent, 259
 Modiolus, 207
 Molecular layer, retina, 186
 Monro, foramen of, 223, 224
 Motor oculi, of dog and rabbit, 10
 Mounting, 256
 Mounting osmic acid preparations, 170
 Mouse, cartilage of ear of, 40
 Mucilage, starch, 113
 Mucin, 113, 126
 Mucous coat or membrane (stomach), 107, 109; large intestine, 126; of bladder, 157; (oesophagus), 109; trachea, 144; intestine, ileum, 122; mucous membrane (olfactory region), 173, 174, 245; gland, structure of, 110
 Mucus (urine), 159
 Müller's circular muscle, 182; fibres, 185, 187; fluid, 245, 248
 Multipolar ganglionic cells, 76
 Murexide test, 161
 Muscle, of dog and rabbit, ext. obliq. abd., 1; rect. abd., 1; int. obliq. abd., 2; transversalis, 2; diaphragm, 11; pectoralis major, 11; serratus magnus, 11; ext. intercost., 11; int. intercost., 11; serratus anticus, 11; levatores costarum, 12; platysma, 13; sterno-mastoid, 13, 16; sterno-thyroid, 15, 229; sterno-hyoid, 15; thyro-hyoid, 16, 229; motor, 16; digastric, 19, 21; mylohyoid, 20; recti and obliqui oculi, 23; micros. exam. frog's striated, 57; mammalian, 109; hydrophilus, 58, 59; plain or non-striated, 59, 83, 85, 106, 108, 109; cardiac, 61, 98; of villus, 123, 125; lymph gland, 133; spleen, 134; trachea, 144; bronchia, 145; plain muscular fibre in infundibulum (lung), 145; internal sheath of hair-follicle, 167; of ciliary muscle, 182, 184; properties of muscle as shewn by constant current, 62; single induction shocks, 63; interrupted current, 64; stimulation (chemical), 65; (mechanical), 65; muscle curve, 65; tetanus, 66; elasticity, 66; exhaustion, 67; reaction of muscle, 67; muscular coat, stomach, 107; oesoph. 109; intestine, 123; muscularis mucosae, 106, 110; muscular sense, 171; ciliary muscle, 179, 182; circular muscle of Müller, 182; sphincter pupillae, 184; dilator iridis, 184; crico-thyroid, 229; crico-arytenoid post., lateral, 230; arytenoid, 230; thyro-arytenoid, 230, 231
 Muscular coat (stomach), 106, 108; bladder, 157; of ureter, 158; circular (tubes of testis), 238; of vas deferens, 239

Muscularis mucosæ, 106, 110, 123
Myosin, 68

N.

Nares, anterior and posterior, 22
Nates, 217, 225
Negative after-image, 197
Nervous system. Cerebro-spinal, of dog and rabbit, pneumogastric, 3, 13; nerves of base of brain, 9; cervical nerve (4th, 5th, 6th, and 7th), 14; microscopic examination of spinal nerves, 70; sympathetic, 73; spinal ganglia, 73; sympathetic ganglia, 75; spinal cord, 75; properties of nervous tissue, 77; automatic action of, 77; nerves, skin, 166; cornea, frog, 168; rabbit, 168; medullated nerve of touch-corpuscles, 169; medullated nerve-fibre of Pacinian body, 170; nerves of olfactory mucous, 174; of taste papillæ, 176; optic nerve, 178, 181, 185, 186; spinal cord, 211; spinal anterior roots, 211; posterior roots, 211; nerve-fibres (cord), 213, 214; nerve-cells, (anterior cornu), 213; fourth cranial nerve, 217; nerves, olfactory, 221; optic chiasma and tracts, 221; third nerve, 221; fourth, 221; fifth, 221; sixth, 221; seventh, 221; eighth, 222; ninth, tenth, eleventh, 222; twelfth, 222; nerve-cells, 245; nerve-fibres, 249; fine nerve-fibres, (spinal cord), 255
Nervous system, sympathetic, of dog and rabbit, 3, 13, 15, 16, 19; cœliac ganglion, left splanchnic nerve, 3; inferior cervical ganglion, 14, 16; first thoracic ganglion, 15, 16; rami communicantes, 15; splanchnic, 15; superior cervical ganglion, 19; sub-maxillary ganglion, 20
Neuroglia, 212
Newt, structure of blood of, 24; of cartilage of, 37; of lung, 143; of olfactory region, 173, 174
Ninth cervical nerve of rabbit and dog, 2, 18, 19, 20, 222
Nucleolus, of ganglionic corpuscles, 74, 75, 76; nuclear layer, retina,

186; nerve-cells, 213; of cells of tubuli seminiferi, 307
Nucleus of cells, (hyaline cartilage), 37; lacunæ of bone, 42; of connective-tissue corpuscles, (tadpole), 46; (newborn mammal), 49; of fat-cells, 50; of ciliated cells, (frog), 56; of sarcolemma, 58; of fibre-cells, 60, 83; of cardiac muscle, 61; of nerve-sheaths, 71, 72; of ganglionic corpuscles, 74, 75; of ganglionic corpuscle sheath, 74, 75, 76; of capillaries, 86, 87; 123, 146; of cells of epithelium (gastric glands), 108; of alveolar cells, (salivary gland), 111; nucleus with thickening of adenoid tissue, 122; nodal, adenoid, lymph glands, 133; plain muscular fibre, 135; hepatic cells, (spheroidal), 140; columnar epithelium of bile duct, 140; of epithelium (Malpighian capsules), 154; (of glomeruli epithelium), 154; of blood-vessels of glomeruli, 154; lining cells of tubuli contorti, 154; of columnar epithelium of tubuli recti, 155; of basement membrane, (tubules of kidney), 156; of dermic muscular fibres, 166; primitive sheath, nerves of cornea, 168; of matrix of touch corpuscles, mucous membrane nose, newt, 173; cylindrical epithelium cell, (oval), 112, 173; rod cell (spherical), 173, 174, 176; of nuclear layer, 173, 174; of cylindrical cell, 174; of flat cells (horny epidermis), tongue, 175; fusiform cells (taste-bulb), oval, 176; nucleus larger retina, spherical or oval, 186, 187; of nerve-cells, 213; nucleus of ovum cell, 234; of cells of tubuli seminiferi, 237; of cells in intermediate tissue of ditto, 238

O.

Oesophagus, 2, 5; of dog and rabbit, 4, 11, 14, 228; structure of, 109
Oil, castor, and spermaceti, 252
Olfactory, lobes, of dog and rabbit, 8, 221; organs (newt), structure of, 173; mucous membrane, 245
Olivary body, 218
Omentum, great, of dog and rabbit, 2
Ophthalmic nerve, 23

Optic nerves, of dog and rabbit, 10 ;
fibres, retina, 185 ; tracts, 218, 221,
225, 227 ; chiasma, 219, 221 ; tha-
lamus, 223, 225
Ora serrata, 179, 180, 181
Osmic acid (use of), 40, 50, 56, 245,
248, 259
Ossiculus auditus, 207
Ossification, 55
Osteoblasts, 55
Ovary, of dog and rabbit, micros.
exam., 8, 232
Ovoid cells, 107
Ovum, 233, 234, 235
Ox, eye of, 178 ; lens of, 183 ; vision,
188 ; spinal cord, 212 ; larynx, 228
Oxyhæmoglobin, 148, 149 ; spectrum
of, 149, 150, 151

P.

Pacinian bodies, 170
Palate, sensation (taste) in, 177
Pancreas, of dog and rabbit, 2 ; pre-
paration of for micros. exam., 6 ;
structure of, 112 ; juice of, 128 ;
properties of, 129
Papillæ, œsoph. 110 ; (skin), 166, 169 ;
tongue, 175 ; nerves of, 176 ; cir-
cumvallati, 177
Paraffin (imbedding), 251
Parapeptone, 118, 119, 120, 128
"Parenchymatous" cartilage, 40, 54
Parovarium, 235
Pars ciliaris retinae, 180
Peduncles, inferior (cerebellum), 216 ;
superior, 217 ; middle, 218 ; of cere-
brum, 218 ; of pineal gland, 225, 226
Pepsin, 116, 117, 128
Peptic or ovoid cells, 107, 108, 109
Peptones, 116, 119, 120, 129
Pericardium, dog and rabbit, 12 ;
sheep, 91 ; frog's, 94, 95
Perineurium, 70, 75, 76, 168
Peritoneum, 106, 157
Pettenkofer's test for bile-salts, 127
Peyer's patches, of dog and rabbit, 5 ;
preparation of, for micros. exam.,
7 ; structure of, 124, 131
Phakoscope, Helmholtz's, 191
Pharyngeal nerve, 19
Pharynx, 22
Phosphates, alkaline, in milk, 121

I.

Phrenic nerve, of dog and rabbit, 12,
14
Pia mater, of rabbit, 9, 86, 87 ; dog, 9,
86, 216 ; and sheep, *ib.* ; spinal cord,
210, 218
Picric acid, 248
Picrocarmine or picro-carminate of
ammonia, 255
Pig, gastric mucous membrane (gas-
tric juice), 116 ; testes, 237
Pigment-cells, 49 ; bile-, Gmelin's test
for, 126 ; -layer (choroid), 180, 181,
182, 184, 186 ; branched (iris), 184 ;
pigment layer of retina, 181, 186
Pillars, posterior (fornix), 223, 224 ;
anterior, 224, 225, 227
Pineal gland, 224, 225, 226
Pithing, 262
Pituitary body, 218
Plasma, of horse's blood, 32
Plasmine, 33
Pleural cavity, of dog and rabbit, 11,
12
Plexus nerve (cornea), primary, 168,
169 ; sub-epithelial, 168, 169 ; epi-
thelial, 169 ; choroid (4th v.), 216 ;
lateral vent., 222, 223, 224
Pneumogastric, of dog and rabbit, 3,
10, 13, 16, 19, 21 ; of frog, 96, 97 ;
ganglion of the trunk, 19 ; cardiac
branches (frog), 95
Pons Varolii, 218, 220, 227
Positive after-image, 196
Potash acetate, 258
Potassium, bichromate, 248, 259
Pressure, blood-, 99
Processes, ciliary, 179, 180, 181, 182 ;
protoplasmic (nerve-cells), 214 ; pro-
cessus vocalis, 231 ; muscularis (ary-
tenoid cart.), 231
Processus gracilis, 205
Prostate, of dog and rabbit, 8
Proteids, tests for, 35 ; in saliva, 114 ;
in liver, 141
Proteolytic ferment, 128, 129
Protoplasm, of cells (cartilage), 37 ;
bone lacunæ, 42 ; of connective-tis-
sue corpuscles (tadpole), 46 ; of fat-
cells, 51 ; of ciliated cells (frog),
56 ; of fibre cells, 51 ; of ganglionic
corpuscles, 74, 75, 76 ; of epithelial
cells (conical) ileum, 122 ; (goblet)
ileum and jejunum, 124 ; (hepatic
cells), 140 ; of lining cells of tubuli

- contort., 154; reticulate (olfactory mucous), 173; protoplasmic nerve processes, 214; of ovum, 233; of spermatozoa (frog), 239
- Pseudo-stomata (guinea-pig and rabbit), 137
- Ptyalin, 115
- Pulp, cavity of teeth, 43
- Pulp (spleen), 134
- Pulsation, ventricular, tracing of, normal, 95; abnormal, 96
- Pulse, 102; progression of pulse-wave, 103
- Purkinje's figures, 194
- Pyramids, of Malpighi, 153, 157; of Ferrein, 153, 154, 155, 156, 157; medulla oblongata, posterior, 216, anterior, 217
- Q.
- Quadrigenina corpora, 217, 224
- Quantitative estimation (urea), 162; sugar, 163
- R.
- Rabbit, dissection of, 1; differences from dog, 16; transition of connective-tissue corpuscles to fat-cells, 51; œsophagus, 109; Peyer's patch, 131; diaphragm and peritoneum (micros.), 137; diaphragm and pleura, *ib.*; liver for glyco-gen, 141; bladder, 157; ureter, 158; cornea, nerves, 168; tongue (papillæ), 175; eye of, 181; cornea (micros. exam.), 182; spinal cord (micros. exam.), 210, 211
- Radicle, lacteal, villus, 123
- Ranvier's node, 71
- Rat, connective-tissue corpuscles, 47; blood-colour, 148, 149; eye of, 188; testis of, 236, 238, 239
- Reagents, chemical, 259
- Recessus vestibuli of mammals, 202
- Reflex action, 77
- Reissner, membrane of, 208
- Remak, fibres of, 73
- Respiration, 148
- Rete testis, 236
- Reticulum (lymphatic alveoli), 133; (splenic pulp), 134; (retina), 187
- Retina, ox or sheep, 179, 180, 181; micros. exam., 184
- Rima glottidis, 228
- Rods (retina), 186, 187; of Corti, 208
- Roots, spinal nerves, anterior and posterior, 211, 213, 214
- S.
- Sac, dorsal lymphatic (frog), 80; of ear, 202
- Saliva, exam. of, 113
- Salivary gland, structure of, 110
- Saphena vein (external) of rabbit, 17
- Sarcolemma, 58
- Scheiner's experiment, 190, 192
- Scheme, arterial, minor, 99, 262; major, 100, 260
- Schlemm, canal of, 182
- Schneiderian membrane, 22
- Schwann, white substance of, 70
- Sciatic nerve of rabbit, 18
- Sclerotic (ox or sheep), 178, 181, 182
- Semilunar valves, 92, 93, 94
- Sensation, of temperature, 171; of taste and smell, 176; of light, 196, 197
- Septula testis, 236, 237
- Septum, heart, sheep, 92, 93; frog, 94; lung of frog, 143; lucidum, 223, 226
- Serous gland, structure of, 112
- Serum, of blood, 33, 244; iodised, 244
- Seventh cranial nerve, of dog and rabbit, 10, 18, 221
- Sheaths, (of nerve), medullary, 70, 71, 72, 168, 170; primitive, 70, 71, 72, 168; of ganglionic corpuscle, 74, 75; of salivary gland, 110; of spleen, 133; of hair-follicle, 166, 167
- Sheep, heart of, 91; eye of, 178, 186, 188; brain, 215; larynx, 228; differences from man, 231; ovary of, 235
- Shocks, single induction, 63, 66
- Sigmoid gyrus, 220
- Silver nitrate, 256, 259
- Simultaneous contrast, 198
- Sinus, Valsalva, 94; venous, 95, 98; lymph-, (lymph. gland), 131, 132, 133; (spleen), 134; venous (eye), 182
- Sixth cranial nerve, of dog and rabbit, 10, 221
- Skin, structure of, (human scalp), 165; palm or forehead, 168; nerve endings in, 169
- Smell, sense of, 176

- Solutions, normal saline, 244; preparation of, 246
 Space, posterior perforated, 218; respiratory, 231
 Spasm, single, 60, 66
 Spermaceti and castor oil, 252
 Spermatozoa, 237, 239
 Sphincter pupillæ, 184
 Sphygmograph, 102
 Spot, blind, 193; yellow, 194, 195; germinal, 236
 Spinal accessory, of dog and rabbit, 10, 21; cord, 212
 Spleen, of dog and rabbit, 2; structure of, 133; splenic pulp, 134
 Staining, 252
 Stapes, 206, 207
 Starch mucilage, 113
 Stasis, 89
 Stokes' fluid, 150, 260
 Stoma, (frog), 136, 137; rabbit and guinea-pig, 137; pseudo- (rabbit and guinea-pig), 137
 Stomach, of dog and rabbit prep. of, for micro. exam., 6, 245
 Stomach, structure of (cat, dog), 106
 Stroma, kidney, 156; ovary, 232, 233, 234
 Subcutaneous tissue, 166, 168, 170
 Sublobular vein, 140
 Submaxillary gland, 16
 Submucous coat, stomach, 106; œsoph. 109; ileum, 121; duodenum, 125; trachea, 144; bronchia, 145
 Submucous coat, (stomach), 106; bladder, 157
 Substance, glandular (lymph. alveolus), 133; (spleen), 134; cortical (kidney), 156, 157; white (spinal cord), 211, 212
 Substantia gelatinosa, 211, 213, 214
 Sugar, in glycogen, 142; test for (urine), 161; quant. estimation, 163
 Sulcus (cerebrum), 215, 216; crucial, 219
 Supplementary band, 218
 Sweat-gland, 125, 168
 Sylvius, fissure of, 219; supra, convolution of, *ib.*; aqueduct of, 226
 Synovia, 17
 Synovial sac, 17
 Syntonin, 69, 118
 Systole, 95
- T.
- Tactile delusions, 172
 Tadpole, connective-tissue corpuscles of, 46
 Tannic acid (action on blood), 30
 Taste, bulbs, 175, 176; sense of, 176
 Teasing, 244
 Teeth, microsc. exam. of, 43; interglobular spaces of, *ib.*; softening of, 247
 Temperature, sensation of, 171
 Tendo Achillis (frog), 48
 Tendon, 17, 18, 54; microsc. exam. of (frog), 45; rat, 47; rabbit and guinea-pig (diaphragm), 137
 Tensor tympani muscle, 206, 207
 Tenth cranial nerve of dog and rabbit, 10, 222
 Tentorium of dog and rabbit, 9
 Testes, of dog and rabbit, 7; prep. of for microsc. exam., 8; exam. of, 236; (cerebrum), 216, 217; of rat, 236, 238, 239
 Tetanus (muscle), 64, 66
 Thalamus opticus, 223, 225
 Theca follicularis, 234
 Third cranial nerve, of dog and rabbit, 10, 220, 221; ventricle, 218, 224, 225, 226
 Thoracic duct of dog, 12
 Thymus of dog and rabbit, 13
 Thyro-hyoid, 229; arytenoid, 230, 231
 Thyroid cartilage, 23, 229
 Tissues, contractile, 56
 Tongue, (papillæ), 175; taste in, 177
 Touch, 170
 Touch-corpuscles (figures), 169
 Trabeculæ (lymphatic gland), 132, 133; (spleen), 134
 Trachea, of dog and rabbit, 13; structure of, 143
 Tractus intermedio-lateralis, 212
 Tricuspid valves, sheep, 93
 Trochlear nerve of dog and rabbit, 10
 Tuber cinereum, 218
 Tubes, Eustachian, 22; looped, of Henle, kidney, 155
 Tubules, 157; straight, collecting or discharging (recti), 153, 156; secreting (contorti), 153, 154, 156; connecting, 155, 156; of parovarium, 235; tubuli seminiferi, 236, 237, 238

- Tunica adventitia** (blood-vessels), 83, 86, 87; Malpighian bodies, 134; tunica adventitia (tubuli uriniferi), 237; intima, 87; albuginea (ovary), 232, 233; (testis), 236, 237; follicularis, 234; vaginalis propria, 236, 237; adnata, 236
- Turpentine**, 257, 258
- Twelfth cranial nerve of dog and rabbit**, 10, 222
- Tympanic, bulla**, 21, 22, 204; cavity, 22; membrane, 22, 224
- U.**
- Urea**, 160; quantitative estimate (Liebig's), 162
- Ureter of dog and rabbit**, 7
- Urethra of dog and rabbit**, 7
- Uric acid**, 160; murexide test, 161
- Urine**, ferment in, 159
- Uterus of dog and rabbit**, 7
- Utriculus**, 201, 202, 204
- Uvea (iris)**, 182, 184
- V.**
- Valsalva, sinuses of**, 94
- Valve, of veins**, 86; semi-lunar, 92, 93, 94; Eustachian, 93; auriculo-ventricular (tricuspid), 93; initial or bicuspid, 94; of lymphatic vessels, 137; of Vieussens, 217, 226
- Varicosities of nerve-fibres**, 73, 168
- Varolii, pons**, 218, 220, 227
- Vasa, recta (testis)**, 236; efferentia, 236, 238; deferentia, 239
- Vas deferens of dog and rabbit**, 7
- Veins, structure of**, 85, 87, 136; valves of, 86; blood-flow (normal) in, 88; in (abnormal), 89; from, 101; interlobular, 139; intralobular, *ib.*; sublobular, 140; epith. of, 256
- Velum interpositum**, 217, 224, 226
- Venous system, of dog and rabbit, v. portæ**, 4, 138; v. cava inf., 4, 11, 12; sheep's, 91, 92; frog's, 95, 97; hepatic v., 4, 139; external jugular, 12; internal jugular, 13; subclavian, 13; vena cava sup., 13, 16; sheep, 91, 92; frog's, 95; pulmonary veins, 15; sheep, 92; innominate veins, 16; v. azygos, sheep, 92, 93; coronary vein, 93; valves of, 86; venous sinus (eye), 182
- Ventricle, (sheep's) heart, right**, 93; left, 94; frog's, 94, 95; cerebral, 4th, 216, 217; 3rd, 218, 224, 225; lateral, 222, 226; 5th, 223; of larynx, 231
- Vesicle, germinal**, 234
- Vieussens, valve of**, 217, 226
- Villi (ileum and jejunum)**, 121, 124, 243; duodenum, 125
- Vision**, 180; region of distinct, 193; of normal colour-, 196
- Vitellus**, 234, 235
- Vocal cords**, 22, 23, 228, 231
- W.**
- Wave, dicrotic**, 102; pulse-, progression of, 103
- Weber's scheme of circulation**, 260
- Weight, estimation of**, 171
- Weights and measures**, 263
- Willis, circle of, in dog**, 10, 221
- X.**
- Xanthoproteic reactions**, 36, 119
- Y.**
- Yellow spot**, 194, 195
- Z.**
- Zinn, zone of**, 180
- Zone, marginal (kidney)**, 154; of Zinn, 180; zona pellucida, 234, 235
- Zymogen**, 129





