



# Bodleian Libraries

UNIVERSITY OF OXFORD

This book is part of the collection held by the Bodleian Libraries and scanned by Google, Inc. for the Google Books Library Project.


For more information see:

<http://www.bodleian.ox.ac.uk/dbooks>



This work is licensed under a Creative Commons Attribution-NonCommercial-ShareAlike 2.0 UK: England & Wales (CC BY-NC-SA 2.0) licence.





**600030058M**







171.

CLINICAL AND CRITICAL CONTRIBUTIONS  
TO  
OBSTETRIC SCIENCE AND PRACTICE.

---

I.  
ON UTERINE POLYPUS:  
ITS NATURE, EARLY DETECTION, AND TREATMENT.

BY  
ROBERT BARNES, M.D. (LOND.)

MEMBER OF THE ROYAL COLLEGE OF PHYSICIANS,  
PHYSICIAN-ACCOUCHEUR TO THE WESTERN GENERAL DISPENSARY,  
PHYSICIAN TO THE METROPOLITAN FREE HOSPITAL,  
LECTURER ON MIDWIFERY, ETC.

LONDON:  
JOHN CHURCHILL, NEW BURLINGTON STREET.

1854.


619 . e . 59.



*This Memoir was read in abstract before the Hunterian Society,*  
*in April, 1854; and has been published in detached parts in*  
**THE LANCET, Vols. I. & II. 1854.**

13, Devonshire-square, August, 1854.





CLINICAL AND CRITICAL CONTRIBUTIONS  
TO  
OBSTETRIC SCIENCE AND PRACTICE.

---

I.

---

ON UTERINE POLYPUS: ITS NATURE; EARLY  
DETECTION; AND TREATMENT.

THE cases I am about to relate, as the foundation for some more general observations upon the nature and treatment of uterine polypus, belong to a class not perhaps rare in their occurrence, but certainly sometimes escaping recognition, if not altogether, at least until long after the most favourable opportunity for treatment has gone by, and when the health of the patient has been deeply injured. When polypus of the uterus has attained a large size, and has descended into the vagina, it commonly produces such symptoms as call imperatively for a local examination. A digital exploration of the vagina, carried up to the os uteri, can scarcely fail in clearing up the nature of the case. But when the polypus is still in the early period of its growth, whilst it is still so small as not to have emerged from the uterus or the cavity of the cervix, although the most severe local disease and the most serious impairment of the constitution may be produced, the cause that entertains this local disease, and continues to exhaust the powers of nature, may escape detection. One of the cases I am about to relate supplies an illustration of this position, and points to the importance of instituting a careful examination


of the uterus in every case of local disease attended by symptoms which cannot be clearly referred to an intelligible cause. The other case not only illustrates the same point in practice as the first, but also throws a clear light upon the nature and origin of one form of uterine polypus. I also propose to offer some observations upon the classification of polypi, founded upon a consideration of their structure; to seek to determine the means of detecting the presence of polypi in the early stage of their formation before they have cleared the os uteri; and to discuss briefly the method of treatment.

CASE 1.—Catharine B——, aged forty-six, a single woman, naturally healthy and robust, applied to me at the Western General Dispensary early in December last. I gathered from her the following history:—She had menstruated easily, and without marked excess or deficiency in quantity, and had suffered no serious illness up to the age of forty-four. For the last two years, however, she has suffered greatly from lumbar, sacral, and uterine pains, a sense of dragging and bearing-down, and pain in the left iliac region, extending down the thighs. All these pains were greatly aggravated at the periods of menstruation; the flow became more abundant in quantity, lasting for ten, twelve, and fourteen days, leaving her very weak. In the intervals between the menstrual periods there has been a leucorrhœal discharge, copious, sometimes gelatinous, sometimes muco-purulent, and sometimes, especially of late, tinged with blood. There has also been pain on passing stools, and such irritation of the bladder as to give rise to a frequent desire to pass urine. During the last year her general health has been suffering greatly; she has complained of loss of appetite, nausea, flatulence, cardialgia, and irregular action of the bowels. She has lost flesh, suffers from headache and giddiness. Her feet swell at times; her complexion has become sallow; she is easily agitated by the slightest cause; any exertion produces palpitation, shortness of breath, and exhaustion. All these symptoms have been increasing in urgency within the last few months. The loss of blood especially has been more

profuse, frequently passing in clots, and she can no longer distinguish the catamenial periods. The pulse is 90, feeble; there is marked anæmia. She has undergone various kinds of general treatment, but without benefit. No local examination has been made.

On Dec. 9th I instituted a careful examination. The toucher caused great pain; the cervix was somewhat enlarged, low down in the pelvis, smooth and round; the os was open so as to admit the tip of the finger; in the centre was felt a soft rolling body, of the size of a large pea; it did not project as far as the os. I at once recognised a small polypus. The speculum was then used, and the cervix was seen to be highly inflamed; the internal surface of the os and the cavity of the cervix, as far as it could be exposed by opening the valves of the speculum, was also intensely inflamed, a copious muco-purulent discharge escaping. The body which had been previously felt rolling under the finger was seen in the middle of the os; it did not project so far as the margin of the os, and might have escaped observation had not a bivalve speculum been employed. The appearance exhibited by the tumour when seen at this time is represented in

FIG. 1.



I applied the solid nitrate of silver freely to the os and cervix, and admitted her into the Metropolitan Free Hospital, in order to remove the polypus.

On the 16th, an examination was made; the inflammation

was diminished, but indications of approaching menstruation obliged me to defer the operation. By rest, astringent injections, and salines, the inflammation subsided still more; but on the occurrence of menstruation the loss of blood was great, and the inflammation returned. When the catamenia ceased, I again applied the nitrate of silver, and prescribed astringent injections.

On the 26th, the inflammation being in my opinion sufficiently subdued, I removed the polypus by torsion, having first drawn it gently out of the cavity of the cervix, so as to enable myself to grasp the pedicle firmly. When thus drawn out of the cervix it was found to consist of three lobes, and was very soft and red. The operation was attended by a trifling loss of blood, but some pain. On the second night after the operation some hysterical excitement appeared; the pulse was 110; she complained of acute spasmodic pain in the region of the womb, with bearing-down; there was a moderate degree of febrile movement, with sickness; a distressing cough came on.

On the following day a small clot came away, and the symptoms were relieved, excepting the pain. Pressure behind the pubis seemed to cause pain, and she complained of great soreness on sitting up. By the use of emollient injections, sedatives, with hydrocyanic acid, she got gradually better.

On the 2nd of January, all febrile excitation having subsided, as well as symptoms of acute inflammation, I ordered her mineral acids and lead injections.

On the 9th, an examination by speculum showed the cervix in a more healthy condition; the vivid injection had faded, and there was but little discharge from the cavity.

On the 26th, I added some tincture of iron to the mineral acids. She had now recovered tolerable health; her appetite was good; she could walk about without pain; the bearing-down had disappeared; the leucorrhœa was almost gone; she felt strong and well. On examination now the os was found perfectly natural, and the womb had risen to its proper place in the pelvis.

CASE 2.—W——, single woman, aged thirty-six. This patient

came under my care at the Western General Dispensary. She had enjoyed good health, and had always menstruated regularly and normally until between two and three years ago. About this time the catamenia began to exhibit a disposition to profuseness not before observed. Soon the flow at the menstrual period passed altogether the bounds of natural menstruation; it lasted for from ten days to a fortnight; blood came away copiously and in clots, and the loss left her so weak that she had barely time to recruit a little strength before she was again exhausted by its recurrence. In the short intervals between the menstrual periods, there has latterly been an increasing leucorrhœal discharge, and this is sometimes tinged with blood. Since January last the hæmorrhage has increased to an alarming extent; there has been scarcely any remission to mark the intervals between the menstrual epochs, so that for the last four weeks she has been obliged to keep her bed. She has never suffered any pain. A fortnight back she came under the care of Mr. Evans, the house-surgeon to the Western General Dispensary. She took quassia and tincture of iron, but this had scarcely any effect in restraining the flooding.

When I saw her on the 21st of March the flooding still continued; the degree of anæmia was extreme; and it was obvious that her life was in imminent danger. No local examination to ascertain the cause of the hæmorrhage had ever been made. On examining by the toucher, I at once detected a tumour the size of a large filbert projecting into the vagina, and partly encircled by the os uteri. With the view of arresting the hæmorrhage until I could make arrangements to remove the polypus, I prescribed two drachms of oil of turpentine with four ounces of mucilage, and eight of water, ordering a wine-glassful to be taken every three hours. She took two doses, and the hæmorrhage almost entirely subsided.

On the 23rd of March I admitted her into the Metropolitan Free Hospital. Finding, on minute examination, that the tumour arose by a large basis from the margin of the os uteri, I determined to apply a ligature by the aid of Gooch's instru-

FIG. 2.

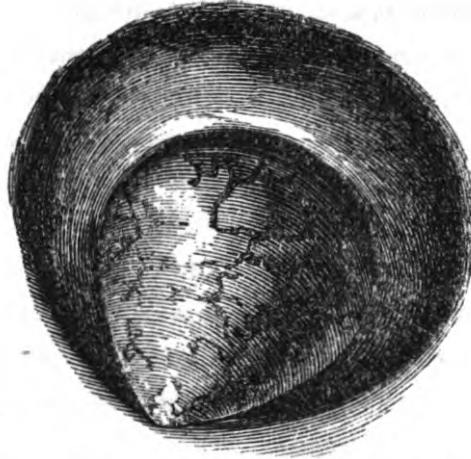


Fig. 2 represents the appearance and attachment of the tumour.

ment. I did this through the speculum, a method I always prefer whenever the polypus is not so large as to render its use inconvenient. I had presently reason to congratulate myself that I had done so in this case. On tightening the ligature, it cut through the neck of the tumour. When this was removed, on opening the os uteri, which was remarkably flaccid, so as to obtain a good view into the cavity of the cervix, I observed another polypus springing from the inside of the posterior lip, so minute in size that it would almost certainly have escaped detection by the finger. Yet, small as it was, it would in all probability have kept up the flooding, and rendered nugatory the removal of the larger polypus. I broke up this polypus with the speculum-forceps. There was no secondary disease of the os or cervix. For three days subsequently to the operation there was no hæmorrhage. On the fourth day the catamenia appeared, and lasted for four days, the quantity lost not being greater than natural. A slight return took place on the 2nd of April, but soon ceased. She was ordered ammonio-citrate of iron and nourishing diet. On the 5th she had gained strength, and, being anxious to go home, was discharged. On examination, the os and cervix presented a natural appearance; the spot from which the polypus had been removed was perfectly healed.

I think it useful to remark upon this case, that, from the seat of the polypus upon the edge of the os uteri, an examination by the finger or speculum at the very earliest period could not have failed to have disclosed the cause of the flooding, and to have saved the patient two years of exhausting illness.

#### NATURE OF POLYPUS, AND CLASSIFICATION.

POLYPUS has come to be admitted as a general term, including every tumour connected with the inner walls of the uterus or the cervix, and projecting into the cavity. That tumours found in this position may be of very different characters is well known. Simple projections of a portion of hypertrophied mucous membrane and cancerous tumours have been alike designated as polypi. It is obvious then that the prognosis and treatment of polypus must be governed by the view taken of the pathological nature of the individual tumour under consideration. The pathology, therefore, of the various growths of the uterus which may project into the cavity and assume a polypoid form, is a subject of great practical importance. The subject in my opinion admits of being usefully simplified by eliminating from the definition of polypus all cancerous tumours, and also the cauliflower excrescence. These tumours seldom assume a true polypoid form; they seldom project into the cavity of the uterus or cervix, preserving only an attachment by means of a pedicle; still less frequently is the diseased structure defined by any accurate limits. It extends for the most part beyond the base or point of attachment, and therefore seldom admits of being entirely removed by a ligature as a polypus does.

Dr. Montgomery has referred to another form of organic disease of the cervix, which sometimes assumes some of the appearances of polypus so as to be mistaken for it. Extensive ulceration of the cervix uteri, with hypertrophy of the anterior lip, the mass projecting so as to form a defined tumour, with a neck at the base, may, to the touch alone, convey the idea of a polypus. An examination by means of the speculum will at once reveal the true nature of the disease, and perhaps obviate



the application of a ligature. I would here remark that it has been strenuously contended that the speculum is of no use whatever in the diagnosis or treatment of polypus. Experience, however, must satisfy every one that the eye is frequently of use in correcting the impressions conveyed by the touch; and it does not seem reasonable to discard a means of information upon which we are accustomed to rely as the foundation of our most certain knowledge. By means of sight the mistake in diagnosis, which may lead to a mistake in treatment which Dr. Montgomery has pointed out, may be avoided; and I may refer to the second case I have narrated as an example of the use of the speculum in treatment. Not only was I enabled to apply the ligature more accurately so as to escape injuring the cervix, but also when the larger tumour was thus removed, I was enabled to observe a second minute polypus, which must almost certainly have escaped detection by the finger.

I propose to exclude this form of disease of the cervix also from the definition of polypus.

The classification of polypi admits of more precision than I think has hitherto been observed. On an analysis of cases occurring in practice it will be found that polypi take their rise from three sources: from the bloodvessels lying under the mucous membrane, or from the mucous membrane, or sub-mucous fibro-cellular tissue. I believe that a division thus founded upon the origin is at once the most scientific and the most practical.

#### I.—ON POLYPI SPRINGING FROM THE MUSCULAR WALL OF THE UTERUS.

The polypi which take their rise in the muscular walls of the uterus have been commonly called "fibrous." Recent investigations have, however, proved that they really consist in an abnormal development of muscular fibre, their structure essentially resembling that of the muscular wall of the uterus itself. This muscular character of the so-called "fibrous tumours" and "fibrous polypi" of the uterus, both in the unimpregnated and

in the gravid womb, was first, I believe, distinctly proved, by Vogel, and figured in his admirable work.\* Cruveilhier had, however, previously observed that there were "hard polypi, which consisted in hypertrophy of the tissue of the uterus—such is the one figured pl. vi. liv. xi<sup>e</sup> — and others consisting of fibrous bodies developed under the uterine mucous membrane." The celebrated French pathologist thus describes the structure of the polypus referred to: "The figure represents an antero-posterior section of the polypus and of the fundus of the uterus. The tissue of the polypus is seen to be continuous, without any line of demarcation, with the proper tissue of the uterus; it is a prolongation of this proper tissue, and not a fibrous body developed in the thickness of the uterus, capable of being separated by enucleation. The identity between the tissue of the uterus and the tissue of the polypus is such that the closest examination does not reveal the slightest difference."

Cruveilhier does not appear to have suspected that the ordinary fibroid tumour, distinctly defined from the proper uterine tissue, and capable of enucleation, might also consist of muscular fibre in every respect resembling the muscular fibre of the uterus.

As this discovery is of especial interest in relation to the pathology of uterine tumours and polypi, I think it of importance to translate Professor Vogel's account at some length. In describing Fig. 5 of Plate IX., he says, "It represents the primigenous cells of a fibrous tumour arising in the uterus. These cells are doubtless the rudiments of organic muscular fibres, which but rarely come under observation. The history of the disease is as follows:—A single woman, aged forty-four, was admitted into the hospital, after having suffered for several years from a fluctuating swelling in the right side of the abdomen, which hitherto had caused no pain, a dragging sensation, as if the patient were about to bring forth, only excepted. Suddenly violent pains came on in the abdomen, increased by

---

\* Erläuterungstafeln zur Pathologischen Histologie. Leipzig, 1843.

pressure. These continued, notwithstanding energetic treatment by bleeding and emollients. The patient died after three days.

“The autopsy gave the following results:—The omentum was considerably thickened on the right side, and adherent both to the abdominal walls and to a hard tumour, which reached below into the pelvis, and was of the size of two fists. The tumour was knobby on the surface, of a white colour, and hard to the feel; it was intimately connected with the fundus of the uterus, from which it seemed to spring. The inner surface of the uterus appeared natural; the mucous membrane unaltered. In its cavity, however, was a round tumour, the size of a billiard-ball, hard, of a bluish-white colour, and covered with a yellowish purulent matter. It lay free in the cavity of the womb, without any attachment to the walls. The substance of the uterus was much thickened; the thickness was not uniform, but in many places it was three inches. In the substance were many round tumours, of the size of a pea, a bean, of a walnut, up to that of a billiard-ball. These tumours were for the most part free, or at least could be easily detached from the surrounding substance of the uterus; they were of a white colour, and very firm texture. They were in general bullet-shaped, but most of them were knobby. On section, they showed interiorly the same hard, glistening tissue as the outside; but a fibrillation or distinct texture could not be distinguished by the naked eye. The large tumour first described, arising from the fundus uteri, was softened in parts; it exhibited irregular, eroded excavations, traversed by bands, which were soft at the surface, but hard in the interior. These cavities were, some empty, some filled with a soft blood-coagulum, or a greasy, purulent gray matter. The softened tumour was broken above, and had emptied a part of its contents into the cavity of the peritoneum, whence secondary peritonitis and death.

“Another tumour, of the size of a pigeon’s egg, was found in the vaginal portion of the uterus; this was softer, and could

not be separated from the uterine substance. It was white, and consisted of a fibrous web with large meshes filled with a thick albuminous fluid.

“A more minute examination of these parts by the microscope gave the following results: The substance of the uterus consisted of the ordinary organic muscular fibres. In some places brownish cells in great numbers were found between these fibres.

“The mass contained in the cavity of the uterus showed quite the same structure, the same fibres, and similar brown cells. The tumours contained in the substance of the uterus, both great and small, were exactly similar. The upper softened part of the large tumour contained, together with blood-clots and isolated blood-corpuscles, many pus-globules, which underwent the ordinary change with acetic acid. The softening of the tumour was plainly occasioned by inflammation. The traversing bands and threads in the cavities of the softened portion, were recognised under the microscope as the *débris* of organic muscular fibres and connecting tissue, which had withstood the destruction of the surrounding tissue. The softer tumour in the vaginal portion appeared to be a fibrous tumour; the fibrous portion consisted of organic muscular fibres and connecting tissue; the albuminous-looking fluid in the meshes showed numerous round or elongated cells, sometimes solitary, sometimes in groups, probably primary which, later, would have been developed into muscular cells, fibres.

“Some of the tumours contained in the substance of the uterus were carefully enucleated, cut into small pieces, repeatedly washed in water, and submitted to chemical investigation. They were gradually dissolved in boiling concentrated muriatic acid; the solution was colourless. In acetic acid they swelled up, became translucent and gelatinous; but a perfect solution was not obtained at the end of a week's treatment.

“Similar pieces, carefully washed with water, then dried be-

tween pieces of blotting-paper, were weighed, and completely dried at a temperature of 100° in a water-bath and again weighed; 1000 parts of the fresh substance gave 220 parts of dried residuum."

The next figure described by Vogel is that of a similar muscular tumour taken from the hypertrophied muscular coat of a man.

Another figure is taken from a fibrous tumour of the uterus of a woman who had died from heart-disease. The tumour was of the size of a walnut. "Its texture had altogether the ordinary character of fibrous tumours. Portions taken from the interior showed very beautifully the development of fibres out of cells; many elongated nucleated cells were bound to a fibre which in every respect resembled the ordinary fibres of organic muscle."

FIG. 7 is another example of the muscular structure of a so-called fibrous tumour of the uterus, taken from a non-puerperal woman.

FIG. 8.—This case is especially interesting, as it offers an example of the examination of a tumour taken from a puerperal patient. It represents the "mature fibres of a fibrous tumour of the uterus found in the body of a woman aged thirty-three, who died of puerperal fever. In the fundus uteri, two tumours of the size of almonds were found externally projecting under the peritoneum. They consisted of parallel fibres forming a thick, very dense, milk-white tissue. The fibres became pale, and gradually dissolved in acetic acid; most of them bore long, spindle-shaped cells, which were not affected by acetic acid. *The normal substance of the uterus consisted of the same fibres, which resembled in every respect those of the two tumours.*"

FIGS. 10 and 11 of Plate XXIII. exhibit the structure of a fibroid tumour of the uterus. "A woman died of strangulated hernia. On dissection, a small fibroid tumour was found, attached by a thick pedicle to the surface of the uterus. The fibres had quite the appearance of the normal fibres of the uterus."

In Plate VII. Professor Vogel represents the muscular character of fibrous tumours taken from different parts of the body, including the uterus.

The next person to recognise the muscular structure of fibrous tumours of the uterus was, I believe, Dr. Oldham. I think it important to cite his description as published in "Guy's Hospital Reports" for 1844, as one of the tumours which formed the subject of his observations has very recently been examined again by another gentleman, who appears to think he was the first to detect in it true muscular fibre.

It is the well-known case of Dr. Crisp:—"The placenta being retained, Mr. Crisp, after waiting three-quarters of an hour, introduced his hand and removed it. In withdrawing his hand, he thought he felt another child enclosed in its membranes, and endeavoured to pull away from the side of the uterus what appeared to be the placenta, but failing in this, he perforated it; being again foiled, he desisted from further interference. Dr. Chowne and Mr. Bristowe being called to the case, discovered that there was a large polypoid growth within the womb, causing violent expulsive pains and greatly exhausting the patient. The energetic action of the womb forced the polypus so low down in the vagina as to interfere with the passage of the catheter. The patient died collapsed, worn out with the constant uterine action, though unattended with hæmorrhage."

Dr. Oldham says, "the prevailing tissue (of this tumour) was a clear, unstriped fibre, which, when examined with a portion of the muscular fibre of the uterus, differed only in the latter being more full of cells and blood-corpuscles, which rendered its definition as fibre less distinct than the former." In "Guy's Hospital Reports," for 1852, Dr. Oldham again refers to the conclusion expressed above as to the muscular character of fibrous polypi.

In February, 1851, an opportunity occurred to myself of verifying this point in the pathology of fibrous tumours.

CASE 3.—On the 6th of February of that year, Mr. Chance

sent me the uterus of a woman who had been brought into the dissecting-room. It had been cut open by a student. A tumour the size of a filbert had been attached to the orifice of each Fallopian tube. When sent to me, one, that from the right side, had been removed. The other had been cut through, but its attachments were preserved. It appeared to be connected with the uterine walls by fibro-cellular adhesions, such as might easily have been lengthened out into a pedicle, permitting the tumour to escape from the uterus in the form of a polypus. The orifices of the Fallopian tubes were completely obstructed. The tumour remaining appeared to be of a fibrous structure. It was submitted to microscopical examination by Dr. Hassall and myself. It was made up of fibres in every respect resembling the organic muscular fibres of the uterus from which it was taken. I exhibited the specimen to the London Medical Society on February 17th following, stating the opinion Dr. Hassall and myself had formed as to the muscular character of the tumour. The report of the proceedings was published in *THE LANCET* at the time.\*

On the 19th of April, 1853, Dr. Bristowe reported to the Pathologica Society the result of his examination of two "fibrous" tumours.† The first tumour was taken from a patient of Dr. Waller's, who had recently died after delivery. He says, "Vogel, in his 'Pathology' states that some at least of these growths are really muscular, and absolutely identical in structure with the walls of the uterus; but so far as I have been able to learn the observations of this pathologist seem to have been confined to the unimpregnated organ." I may be permitted to observe that had Dr. Bristowe read a little further on, he would have been able to learn that Vogel had actually described and figured the muscular character of a fibrous tumour taken from the *puerperal uterus*. The case referred to is quoted above. Dr. Bristowe found the tumours

---

\* *THE LANCET*, vol. i., 1851.

† Transactions of the Pathological Society, 1853.

he examined to consist of "fusiform, pellucid, fasciculated, muscular fibres, identical in size, shape, general appearance and arrangement with those of the uterine parietes."

Dr. Bristowe next, "through the kindness of Dr. Crisp, had another opportunity of examining the structure of fibrous tumours in the gravid uterus. The case is recorded in the *Transactions of the Medical Society of London*, vol. i., new series, p. 122.....In this case the tumour had been for several years in Goadly's solution; still, it was seen clearly to consist of muscular tissue."

But this is the same tumour which had already yielded up its pathological mystery to Dr. Oldham, who had examined it in the recent state ten years before.

CASE 4.—In the month of June, 1853, I was requested by my colleague, Mr. Forbes, to see a woman who had been suddenly seized with alarming flooding. The abdomen was enlarged, and there was reason to conclude she was pregnant. There was extensive anasarca. A tumour connected with the uterus was felt projecting to the right, and upwards to the umbilicus, which she had pointed out to her husband as the child's head. By the aid of galvanism a mass of hydatiginous placenta was expelled. The patient sank of exhaustion and peritonitis on the following day. On examination a "fibrous tumour," the size of a large orange, was found imbedded in the right wall of the uterus near the neck. The left ovary contained a number of small cysts. The kidneys were in a state of granular degeneration.

On microscopical examination of the tumour and the walls of the uterus, both structures were found to be essentially identical. The tumour was composed of nuclei and fibres similar to those of the uterine muscular wall. The mass was, however, very hard, condensed, cartilaginous; it could not be torn apart. I think it a point of interest to remark upon the general tendency to abnormal development exhibited in the organs of generation in this case. Abnormal development of the muscular tissue of the uterus, forming a muscular tumour; ab-



normal cystic development of the ovary; and abnormal cystic development of the chorion.

The foregoing review of the history of this subject will, I think, establish the conclusion that little beyond the confirmation derived from the accumulation of fresh instances has been added to the original and perfect observations of Vogel. Not only was the muscular character of the fibrous tumour of the uterus clearly ascertained by that eminent pathologist from the examination of tumours taken from both unimpregnated and puerperal uteri, but he appears to have arrived at a higher and more general law—namely, that many fibrous tumours developed in the organic muscular structures of other organs, as well as the uterus, are likewise muscular. I think, then, it may be concluded that the so-called fibrous tumour of the uterus is in reality a muscular tumour: and there can be no doubt that the so-called fibrous polypus is nothing more than a fibrous tumour of the uterus, which in the course of development, or in some cases, as the result of an effort of elimination, is made to project into the cavity of the organ, preserving only a pedicular attachment. Dr. Lee\* cites Dr. Sims as describing the progress of these tumours of the uterus in the following manner:—1st, If they happen to be developed in the centre of the muscular wall they grow there; 2nd, If near the outer wall, they expand into the cavity of the abdomen covered by the peritoneum; 3rd, If near the mucous surface, then they project into the uterine cavity, protruding before them a layer of muscular tissue, so that the neck of the tumour would be formed by a portion of the substance of the uterus. Boivin, Dugès, Breschet, and other pathologists, have entertained the same view.

*The frequency of Fibroid Tumours and Polypi.*—The identity of structure of the fibroid tumour and the uterine muscular tissue, offers the readiest explanation of the great frequency of fibroid tumours. Bayle has observed that out of 100 women

---

\* Medico-Chirurgical Transactions, vol. xix.

who had died after the age of thirty-five years, in twenty, tumours of this description were found in the uterus. This frequent occurrence of fibroid tumours gives strength to the presumption that fibroid polypi also are more common than is perhaps suspected.

*The Mode in which Muscular Tumours become converted into Polypi* is a subject of considerable interest. The first appearance of a polypus has frequently been observed immediately after delivery; and the history of many of these cases leaves no room to suspect, or at any rate affords no distinct evidence to justify the conclusion, that a tumour of a polypoid form existed in the cavity of the womb prior to delivery. It appears to me that the process of extrusion of a solid tumour from the walls of the uterus into the cavity, admits of a satisfactory explanation.

The anatomical identity of these tumours with that of the muscular walls of the uterus, renders them susceptible of the same influences that act upon the uterus itself. Under the stimulus of pregnancy, the same developmental activity will be imparted to both. It has accordingly been repeatedly observed that these tumours grow with great rapidity during gestation, and that they become diminished in size after delivery. The latter process, however—that of retrocession—seldom, perhaps never, takes place to an extent proportionate to the diminution of the normal muscular fibre of the uterus. The texture of the tumour is usually more dense and compact than that of the uterine walls, and consequently less capable of contraction. The process of extrusion depends mainly upon two conditions—1st, The difference in the degree of density of the proper muscular tissue of the uterine wall and of the contained tumours; 2nd, The contractile efforts of the uterus. When a tumour of greater solidity than the proper uterine tissue is embedded in the walls of the uterus, it will almost necessarily be thrust outwards or inwards when the uterine walls contract upon it. It cannot follow or partake in the uniform contraction of the organ: as an unyielding body, preserving to a great extent its original dimensions, it must be

driven towards one or other surface of the uterus as this diminishes in size. An attentive consideration of the history of many cases in which polypi have first been observed to come down immediately after delivery, amply confirms this proposition. Not to encumber this essay with unnecessary cases, I refer to the account already quoted of the case of Dr. Crisp.

Previously to parturition there was no suspicion of a polypus in the womb. After the birth of the child, and the removal of the placenta, then some other substance, which Dr. Crisp at first thought might be a second child, was felt. At a later period, violent expulsive pains continuing, Dr. Chowne discovered a mass in the womb, now distinctly polypoid in form. Energetic action of the womb still going on, the polypus was next forced low down in the vagina. The dense structure of this polypus is especially attested both by Dr. Oldham and by Dr. Bristowe.

This process, by which the uterus endeavours to cast off a tumour after delivery, merits the careful attention of the obstetric practitioner. It is not difficult to imagine a case, in which the extrusion of the tumour may be less complete than in the above case of Dr. Crisp. The tumour may be retained in the uterine cavity, where its existence may not be suspected. Its presence there may be the occasion of long-continued and even fatal hæmorrhage.

That the process by which a muscular tumour, in an unimpregnated womb, assumes the polypoid form is sometimes similar to that just described, is exemplified in the first case of Professor Vogel. It can hardly be doubted that the presence of the tumours in the walls of the uterus was the cause of the violent contractions, simulating labour-pains, which in all probability brought about the extrusion of one of these bodies into the cavity of the womb. In this instance the contractions had actually effected the entire detachment of one tumour, which was found lying free in the cavity. Another step, and it might have been expelled from the body altogether.

The process of extrusion is further facilitated by the slight-

ness of the attachments by which these muscular tumours are connected with the uterine walls in which they are imbedded.

It is certain, however, that uterine tumours, when they become polypi, do not do so, in all cases, under the agency of active uterine contraction. Sometimes this takes place as the result of the different ratio of growth of the tumour and of the uterus. A dense, solid substance, isolated from the uterine wall in which it is imbedded, and continuing to grow, whilst the uterus itself partakes but slightly in the process of enlargement, will in time form a projection upon one or other surface of the organ. A further stage of growth will cause it to bulge more and more prominently, until it acquires a distinct polypoid form. In the following case, related by Dr. Montgomery, the gradual conversion of a fibrous tumour of the uterus into a polypus was so clearly traced, that I am induced to transcribe it.

CASE 5.—“I saw this lady in January, 1845; she was fifty years of age, unmarried, and affected with profuse and irregular hæmorrhagic and other discharges. On examination through the parietes of the abdomen, which were very thin, a tumour could be felt in the region of the uterus; and on examination by the vagina, the posterior wall of the uterus was found bulged out by a tumour, having all the characters of a fibrous mass imbedded in its substance; the uterus lay very high, its neck was small, and the os uteri narrow and quite closed. She was treated with preparations of iodine and iron, and got better, and after about a month my attendance was discontinued.

“I heard nothing of this patient for more than a year, when, on the 18th of February, 1846, I was urgently summoned to see her, in consequence of an attack of very profuse uterine hæmorrhage, which had greatly exhausted her. I was now surprised to find the uterus very low in the pelvis; the cervix enlarged and bulging, as we often find it when abortion is impending; and the os uteri with its lips thinned, and so relaxed that I passed my finger with great ease into it; and about half

an inch within it I felt distinctly a smooth, firm, round tumour, all round which I could pass the point of my finger, without difficulty or obstruction in any part. Rest and tonics were ordered, and I saw her again on the 21st, when the extremity of the polypus had descended as low as the margin of the os uteri; and on the 25th it had passed out, so as to project half an inch into the vagina, with the os uteri encircling it so tightly, and its edges lying so close to the tumour, or indeed pressing into it, that the whole appeared one continuous mass. . . . The polypus remained nearly in the same situation for more than five weeks, with profuse serous discharge, which debilitated her very much; but on the 2nd and 3rd of April, she had *slight sensations of pain for the first time*; and when I visited her on the 4th, I found that the polypus had completely cleared the os uteri, and had descended into the vagina, which it filled. It was removed by a ligature."

Even in some cases of this kind, in which active contractions of a violent painful character are not observed, it is probable that continuous or intermitting contractions of a painless and passive character may promote the extrusion of the tumour.

Not unfrequently this process of extrusion does not stop at the conversion of the tumour into a polypus: it goes on to the complete inversion of the womb. Although this complication is more apt to follow the forcible expulsion of a large polypus occurring after parturition, it has occasionally happened under other circumstances, and when the uterine action, by which it was brought about, was of so passive a character as not to have attracted attention.

*The Extrusion of Uterine Polypi.*—Not only may these fibroid tumours be thus converted into polypi, but they may occasionally be cast off from the uterus and altogether expelled. The thin layer of proper uterine tissue which forms the shell of the tumour may become inflamed and give way; the fibroid body itself, softening, may be broken up in such a manner that the fragments, not perfectly separated from each other, but preserving a slight connexion, may be driven down into the

uterine neck. At this conjuncture the practitioner may interfere with the greatest success. The tumour may be seized by forceps or other convenient instruments, and the fragments presenting may be brought away.

Cruveilhier relates the two following cases of spontaneous expulsion:—

CASE 6.—“A young woman was seized, nineteen days after a laborious delivery, with pains exactly simulating those of parturition, so as to raise the belief that there was superfœtation. After three days of sympathetic phenomena, so severe that her life was despaired of, she passed three flattened bodies of firm consistence, which were altered fibroid tumours. The patient perfectly recovered.”

CASE 7.—The next case was independent of pregnancy. “A young woman had suffered during four months from uterine hæmorrhage, followed by a discharge horribly foetid. At the end of this time she expelled some small masses, which I recognised to be fibrous tumours. This patient, whose health was undermined by hectic fever, and who presented all the marks of cancerous cachexia, recovered, contrary to all expectation, after the expulsion.”

Can any means be adopted to bring about an artificial scission of these uterine tumours analogous to that which sometimes takes place spontaneously?

*Law of Growth of Muscular Tumours and Polypi.*—The mode of growth of these tumours, by the development of unstriped muscular fibre from nuclei, is sufficiently shown by the descriptions and figures of Professor Vogel. But, whilst their histological formation seems to be similar with that of the true uterine tissue, they appear to enjoy a certain amount of independent developmental force. This is proved by their greater comparative rapidity of growth, and by the fact, that they sometimes attain a very large size in the unimpregnated uterus—that is, during a time when the uterus itself scarcely enlarges at all, or only so much as may be attributed to the morbid stimulus imparted by the presence of the tumour. At

the same time it is worthy of remark that fibrous tumours are very rarely found before the age of puberty; if they are, they remain passive until the period of activity of the generative system. After the child-bearing period, and the cessation of menstruation, fibrous tumours previously existing exhibit a marked tendency to recede. It is, I believe, a very rare occurrence to observe that any fresh tumours become developed after this period. The period of active growth of fibroid tumours and polypi is the period of functional activity of the generative organs. The periods of greatest activity of growth of these tumours are the periods when the generative organs exhibit the greatest activity. The periodical stimulus the uterus undergoes at the epochs of menstruation is shared by the tumours lodged within its walls. The rapid enlargement of the uterus during pregnancy is attended by an at least commensurate growth of the tumours.

But, although it may be laid down as a general rule, that fibroid tumours do not continue to grow after the termination of the normal period of menstruation, it must be admitted that exceptions occur. I have even observed that the constitutional ferment which frequently attends this critical period of life seems to determine in the temporary exacerbation of any form of uterine disease existing at the time. The organic force which had hitherto been exerted in healthy physiological processes is now suddenly diverted, and expended in a pathological direction. The disposition to floodings under these circumstances is often greatly increased. The greatest care is necessary in order to carry the patient over this stage of peculiar danger, and to gain in safety that point when the commotions of the critical period subside.

*The Degeneration of Polypi.*—These muscular tumours and polypi not unfrequently undergo a process of retrocession, or even of degeneration. In the case of tumours which have enlarged simultaneously with the gravid womb, the retrocession that takes place is probably effected by the same process of fatty degeneration of the newly-developed fibres, which Mr.

Rainey has described as taking place in the proper muscular structure of the uterus. It has been supposed that fibrous polypi are liable to become converted into scirrhus or cancer. It can hardly be admitted that the abnormal muscular growth of which they are composed is more liable to such a change than is the normal muscular structure of the womb. A muscular fibre cannot be changed into cancer. It may, however, give place to it. It is quite possible that the cancer element may be developed in the substance of an uterine tumour, as it may be in the proper substance of the uterus; and that the activity of the new growth may cause the atrophy of the old, and the gradual substitution, not conversion, of a cancerous tumour for a benignant polypus.

In muscular tumours and polypi of long standing, the vessels often become very scanty, or disappear. Their entire structure sometimes undergoes an earthy or bony degeneration. In this condition, the hæmorrhages which had attended the earlier stages of their growth often cease. They seem to be removed by this change from the sphere of organic activity, and excite little or no irritation in the organs with which they are connected.

CASE 8.—In the year 1848 I examined the body of a lady who had died suddenly from heart-disease, at the age of about sixty. Thirty years previously she had suffered from repeated uterine hæmorrhages, when she was thought by her physicians in Holland to be labouring under scirrhus uteri. I found one of the ovaries converted into bone; the other, partly into cartilage and partly bone. In the place of the uterus was an immense firm, fibrous tumour, partly converted into an osseous substance. This tumour had undoubtedly been the cause of the floodings she had experienced in early life.

A point of considerable interest in the pathology of polypus is *the source of the hæmorrhage*. It has been contended that the blood flows principally, if not exclusively, from the surface of the polypus. Lisfranc especially strenuously advocated this view. It has been urged in support, that the hæmorrhage is



observed to be arrested immediately upon the removal of the tumour; and even in many cases upon the application of a ligature to the neck. It has been pointed out that the pedicles of large polypi frequently carry bloodvessels of considerable size; that the investing membrane is highly vascular, and that it has been seen to pour out blood upon being touched. On the other hand, it has been urged that the real source of the blood is the mucous surface of the uterus. Whilst the particular facts urged in support of the view, that the surface of the polypus pours out the blood discharged, admit of a complete solution by the theory that it is poured out by the uterus, there are also special reasons which support this latter opinion. It is observed that profuse hæmorrhage attends very small polypi as well as those of large size; and it is difficult to imagine how the extensive losses of blood which often occur can escape from the surface of a tumour, in many instances not larger than a small nut. Another reason I would advance is, that the hæmorrhage mostly assumes the form of profuse menstruation. Now it will not be contended that the ordinary menstrual flow comes from any other source than the uterus; and we know that, from various causes, the flow is sometimes inordinately increased in quantity, and this when no polypus is present. Hæmorrhagic menstruation is thus a common consequence upon inflammation, hypertrophy, tumours, and other conditions of the womb which set up a preternatural action. The presence of a polypus seems to act in a precisely similar manner. It therefore seems difficult to avoid the conclusion, that the excess of the ordinary menstrual discharge, occurring when a polypus is present, flows, like the normal proportion, from the womb. When the polypus is very large, almost the entire mucous membrane of the uterus may be protruded before it; that is, there is no mucous membrane but that investing the tumour. In such a case it may in one sense be said truly that the hæmorrhage comes from the surface of the tumour. But this situation of the mucous membrane is accidental. It is surely more correct to say, even in such a case, that the true source of the hæmorrhage is the mucous membrane.

The reason why the hæmorrhage ceases when the polypus is removed or strangled by a ligature is this: the source of morbid developmental activity being cut off, the stimulus to the attraction of an excessive proportion of blood to the uterus is removed; the balance of the uterine circulation is restored; accidental floodings cease, and the discharge at the menstrual periods falls to the usual amount corresponding to the physiological ovarian stimulus.

## II.—ON VASCULAR POLYPI.

The tumours which take their rise from the bloodvessels running under the mucous membrane are the true "*vascular polypi*," a term which has not unfrequently been erroneously applied to the fibro-cellular polypus. The vascular polypus is a form of teleangiectasis consisting in a dilatation or aneurismal growth of the vessels, resembling nævus or hæmorrhoids. This form of polypus is rare. Examples have, however, been recorded.

## III.—ON POLYPI SPRINGING FROM THE MUCOUS MEMBRANE.

The tumours which arise from the mucous membrane are of two kinds.

A. The *fibro-cellular polypus*, sometimes called the "gelatinous," the "mucus," or the "vesicular" polypus. These polypi most commonly spring from the cavity of the cervical canal; they are but rarely found in the cavity of the uterus; and perhaps this may be accounted for by the scarcity of cellular tissue in the constitution of the mucous membrane in this latter situation. The microscopical characters of these polypi assimilate to those of the fibro-cellular sub-mucous tissue. Mr. Paget has accurately described them as presenting "delicate fibro-cellular tissue, in fine, undulating, and interlacing bundles of filaments." In the interstitial liquid, or half-liquid substance, nucleated cells appear imbedded in a clear or dimly-granular substance; and these cells may be spherical, or

elongated, or stellate, imitating all the forms of such as occur in the natural embryonic, fibro-cellular tissue; or the mass may be more completely formed of fibro-cellular tissue, in which, on adding acetic acid, abundant nuclei appear. In general, the firmer the polypus is, the more perfect, as well as the more abundant, is the fibro-cellular tissue." To this it may be added, that these polypi are covered by mucous membrane, containing blood-vessels in greater or less abundance. The size of these polypi varies greatly. They seldom, however, attain the magnitude sometimes exhibited by the muscular polypi. The polypus I removed from the first patient answered exactly to this description.

*B. The follicular-epithelial polypus.* I propose to give this name to the tumour which has sometimes been less accurately called the "Nabothian" or the "glandular" polypus. This form is thus described by Dr. Lee:—

"A fourth variety of tumour of the uterus, to which the term polypus has been applied, is produced by a morbid enlargement of the glandulæ or ovulæ Nabothi. One of these bodies is sometimes converted into a cyst as large as a walnut, or even a hen's egg, and hangs by a slender pedicle from the cervix or lips of the os uteri. It is smooth and vascular, and contains, in some instances, a curdly matter, or yellow-coloured, viscid fluid. .... Though unacquainted with the nature of the glandular tumour of the os uteri, Herbiniaux has given a description of the appearances it most frequently presents: 'There is another species of polypus,' he observes, 'extremely soft, of which M. Levret has not made mention: it is a little excrescence, of the same form as the preceding, but which is always very small; it arises from a segment of the orifice of the uterus, and either remains within the orifice or hangs a few lines out of it. Often it is not larger than a pea, sometimes it is the size of a finger, but its stem is usually very large, considering the small size of the tumour.'"

The microscopical examination of the tumour removed from the second patient demonstrates very clearly the true nature of the "glandular" polypus. The polypus referred to was of

the size of a large filbert; the surface very vascular. On cutting through it, a central cavity was exposed, large enough to hold a large pea; from this there flowed a quantity of pus-like fluid. The substance of the tumour was formed of a fibrous basis, containing numerous large mucus follicles, penetrating throughout, and lined with cylinder-epithelium. The openings of the follicles on the outer surface of the tumour were distinctly traced. The constitution of the tumour will account for its consistence; it cut like butter. It also explains the facility with which the ligature severed the tumour from the os uteri.

I think it will be apparent, from this description, that it is not strictly correct to call these tumours "glandular" or "Nabothian." They contain all the elements of a villus, and the present example seems to verify a conjecture of Dr. Hassall's, quoted by Dr. Tyler Smith,\* "that the solid polypi found attached to the cervix take their rise in enlarged villi of the cervix uteri." I conceive that their growth may be accounted for in the following manner: one or more follicles in this situation become obstructed; the accumulation of secretion behind the obstruction causes the enlargement and protrusion of the follicles; an entire portion of the villus is thus carried out or projected beyond the surface, and, continuing to grow, assumes a polypoid form. I imagine that the pus-like fluid contained in the cavity of the polypus was not pus, but the result of the secretion of the follicles contained in the tumour, which opened into the cavity.

It may be observed that Dr. Lee does not advert to the minute structure of the tumours he describes.

Other forms of tumour, projecting more or less distinctly into the cavity of the uterus or cervix, occasionally appear, but they are comparatively rare, and seldom assume the polypoid form.

The foregoing history of the different forms of uterine polypi seems clearly to establish the general law, that these growths are not new formations—heterologous structures—but abnormal developments of the normal constituent tissues of the uterus.

---

\* *Medico-Chirurgical Transactions*, vol. xxxv.

ON THE DIAGNOSIS, ESPECIALLY THE EARLY DETECTION OF  
POLYPUS.

In the remarks I have to offer relating to the diagnosis of polypus, I shall pass over altogether the consideration of the means of distinguishing polypi which have cleared the os uteri from other abnormal conditions. At this stage of growth, the recognition of the true nature of the tumour is seldom attended with any practical difficulty. But the case is far different when the tumour still lies concealed in the cavity of the uterus or of the cervix. It is quite certain that a polypus of inconsiderable size, retained in the womb, and giving no physical sign of its presence, may yet be the cause of the most dangerous, and even fatal, flooding. The indication to remove a polypus, however small, although situated in the cavity of the uterus or of the cervix, if it be the occasion of exhausting hæmorrhages, is as manifest as that for the removal of the largest polypus lying forth in the vagina. The detection and treatment of polypi which have not emerged from the uterus, is a subject that has as yet attracted far too little attention from the profession. With the exception of the masterly and practical essay of Professor Simpson,\* I am not acquainted with any successful attempt to grapple with the difficulties of the subject.

The means of determining whether a polypus exist in the uterus may be divided into two classes :—

I. The general symptoms.

II. Physical exploration.

1. The general symptoms, although seldom, perhaps in no case, so characteristic as to justify an absolute conclusion, positive or negative, are yet deserving of the most careful analysis. The symptoms considered by Dr. Simpson are hæmorrhage, either in the form of flooding, irregular and occasional discharges of blood, or of hæmorrhagic menstruation; in leucorrhœa, mucus, purulent, or serous; in increased size of

---

\* Monthly Journal of Medical Science, January, 1850.

the cervix or body of the uterus; in symptoms of irritation of the bladder and rectum.

It must be obvious that these symptoms possess in themselves no special or pathognomic value. They may all be present in connexion with simple hypertrophy of the uterus, and more frequently with tumours of the body of that organ not of a polypoid form. The womb may be increased in size from hypertrophy, or a tumour in its walls, or from pregnancy, and its increased bulk from either of these causes will be as likely to produce irritation of the bladder and rectum as increased bulk from any other cause. I may, however, observe, that when the uterus is enlarged by the development of a body in its cavity, we may expect, it to be more evenly rounded in shape.

Hæmorrhage and leucorrhœa do not necessarily indicate any local disease at all, but they undoubtedly point to the necessity of instituting a careful examination with a view to discover the cause upon which they depend. The leucorrhœa attendant upon polypus not unfrequently possesses one quality which may have a diagnostic value. Blood may coagulate in the form of rings round the pedicle of the polypus, and then putrefy; the discharge thence acquires an offensive character, which may lead to the suspicion of malignant disease. On pursuing the diagnosis, the existence of malignant disease may be negatived, and then the probability that a polypus is present will acquire greater strength. Hæmorrhage is not even a constant accompaniment of polypus. Dr. Montgomery, Dr. Simpson, and Dr. Locock, all relate cases of polypi, some of large size, in which no hæmorrhage was observed. But although, as a general expression, hæmorrhage cannot be regarded as a diagnostic symptom of polypus, there is, I think, a mode of examining the subject which may give something of certainty and precision to this symptom. I have, in relation to this inquiry, analyzed the histories of 600 cases of disease, more or less connected with uterine derangement, which have come under my observation at the Western General Dispensary.

*Probable Causes of Hæmorrhage in 600 Cases of Disease more or less connected with Uterine Derangement.*

Inflammation, ulceration, and hypertrophy of os and cervix uteri ... ..	} 12
Inflammation and ulceration of os and cervix uteri	32
Inflammation of os and cervix ... ..	16
Hypertrophy of cervix ... ..	16
Total disease of os and cervix uteri ...	— 76
Enlargement of uterus ... ..	8
Tumours of uterus ... ..	14
Procidentia uteri ... ..	2
Total disease of uterus ... ..	— 24
Scirrhus of cervix or body of uterus ... ..	10
Polypus ... ..	8
Abortion ... ..	14
Pregnancy ... ..	6
Ovarian irritation ... ..	2
Over-suckling ... ..	18
At critical period ... ..	10
Other constitutional derangements ... ..	10
Sea-voyage ... ..	2
Emotion ... ..	6
Not ascertained ... ..	4— 90
Total cases of hæmorrhage ... ..	190

It thus appears that, out of 600 cases of disease, more or less connected with uterine derangement, nearly one-third were marked by an excessive loss of blood, either in the form of hæmorrhagic menstruation or of simple flooding.

By means of a careful analysis of the symptoms, or by vaginal examination, the hæmorrhage could be referred to an intelligible cause in 186 cases.

In analyzing these cases of hæmorrhage with the view of determining how far hæmorrhage is an indication of the pre-

sence of polypus in the womb, we must, in the first place, exclude all those cases in which the hæmorrhage was clearly connected with organic disease, with pregnancy, with abortion, mental emotion, and constitutional derangement. We shall thus eliminate 160 cases, leaving eight cases in which polypus was detected, and twenty-two cases in which tumours in the body of the womb or simple enlargement were found. I desire to arrest attention upon these twenty-two cases, because I believe it to be not improbable that in some of them the cause of the enlargement observed in the uterus might have been due to a polypus concealed in the cavity, and that in some of the instances in which tumours were discovered in the walls of the uterus there might have been also muscular tumours projecting inwards in the form of polypi. It is not improbable that a more minute exploration, facilitated by dilatation of the uterine neck, the cautious employment of the uterine sound, and other means, might have discovered a polypus at the beginning of the treatment or at a later period.

Possibly, also, fibro-cellular polypi might have been discovered in some of the cases where the hæmorrhage appeared to depend upon inflammatory and hypertrophied conditions of the cervix, had a more minute exploration been extended into the cavity of the cervix. It might have been ascertained that the polypus was the original disease, and the inflammation or hypertrophy the secondary result. I state this, because I do not feel justified in affirming absolutely that, in none of the cases described as cases of inflammation, ulceration, or hypertrophy, did a polypus exist, and because it is known that they may exist together. In the great majority of instances, however, I had the opportunity of continuing the treatment until the local disease was subdued, and of witnessing the concurrent cessation of the hæmorrhage.

I submit that it is a point worthy of the most earnest consideration, whether in most, if not in all, cases of profuse uterine hæmorrhage, not obviously dependent upon constitutional causes, or not clearly connected with some ascertained



local disease, it be not an indication in practice to explore carefully the cavity of the womb.

The analysis I have submitted appears to me to lead to the legitimate conclusion that, in a given case of persistent or often-recurring uterine hæmorrhage, where no adequate constitutional cause is observed, where no sufficient organic disease of the os and cervix uteri can be detected, in the absence of pregnancy, some local cause exists higher up in the cervix or in the body of the uterus. Having arrived at this conclusion, it is an obvious indication to pursue our investigation, and to endeavour to determine exactly in what that cause consists. Excluding all other causes, we find a residue of thirty cases of uterine hæmorrhage connected with the three following conditions: eight cases of detected polypus, eight cases of enlargement of the womb, and fourteen cases of tumours of that organ. The cause of the hæmorrhage, then, in all these cases lies above or beyond that part of the organ which is more immediately subject to ordinary tactile and visual examination. Is not the indication clear to pursue the search into that region which has alone remained unexplored?

Before considering the physical means of following up this search, I wish to point out one symptom which may furnish an useful indication. When the uterus contains a foreign body, even of small size, it rarely happens that contractions are not excited—that efforts are not made to expel it.

The occurrence, then, of spasmodic intermitting pains, resembling those attendant upon abortion or labour, together with globular enlargement of the womb and hæmorrhage, point, under the exclusive conditions premised, with a high degree of probability, to the presence of a polypus.

It must, however, be admitted, that the general symptoms can furnish at best but presumptive evidence. In the case of pregnancy, which is attended by general signs of a marked character, no practitioner of experience undertakes to base an absolute opinion upon the general signs alone. He looks for the direct physical evidence afforded by *ballotement*, the

placental rush, or the sound of the foetal heart. In the case of polypus, the general symptoms can never rise to that point of distinctness which is usual in pregnancy; the necessity, therefore, of seeking for direct physical evidence is still more imperative.

*The Physical Means of detecting Polypi.*—It may be that the polypus has descended so low down as to be on the point of escaping through the os uteri. In this case it may, under favourable circumstances—that is, during the relaxation and forcing down attendant upon an attack of flooding—be perceived by the finger. Its detection is even more probable by the use of the bivalved speculum, which, by expanding, opens the os, and permits an inspection of a certain portion of the cervical canal. The uterine sound is also available in further opening the os. An observation of Dr. Locock's clearly expresses the importance of making the examination during the existence of the hæmorrhage. He says—"I never discovered the polypus in these cases when I examined the uterus in the intervals between the attacks of hæmorrhage, either by the finger or speculum. The os uteri closes in the intervals of the attacks. The tumour comes down during hæmorrhage." It has occurred to me in several instances to have observed a polypus at one examination, which could not be detected on a subsequent occasion.

Another cause that may help to conceal a polypus in the cervix, is the congestion and swelling of the os, induced by the irritation caused by the polypus, or arising from independent circumstances. This condition may be removed by appropriate treatment, and when the os has been restored to its natural state, the polypus may be brought into view.

*The Uterine Sound.*—As a means of extending tactile perception beyond the point which it is possible to reach by the finger, the uterine sound is in some cases a most valuable instrument. By its means it will generally be possible, in cases where the os and cervix are sufficiently open, to determine whether or not a movable body be present in the uterus.

Should our conviction or our presumption, derived from the evidence of the uterine sound or from other sources, be so strong, that a polypus is present in the cavity of the womb, we possess means of bringing it into view. By causing contractions of the womb the contained body may be expelled. The ergot of rye has been used for this purpose, and no doubt sometimes with success; but I greatly prefer the agency of *galvanism*, as being both more safe and more efficacious. Dr. Tyler Smith has already applied galvanism in one instance for this purpose, with complete success.

Dupuytren recommended the practice of opening the cervix in these cases by *incisions*. Although I can conceive a case in which this operation may be justifiable, I believe that the necessity for resorting to it must very rarely occur, since we possess another means of effecting the object in view, with as much certainty and with less danger.

The plan of *dilating the os and cervix uteri* by means of sponge-tents, proposed by Professor Simpson, finds, in cases of this description, its most valuable application. The use of two or three graduated sponge-tents in succession will mostly succeed in opening up the canal of the cervix to an extent sufficient to admit of a perfect exploration by the eye and the uterine sound of the cavity of the uterus.

I am aware that the proposal to use sponge-tents, for the purpose of dilating the os uteri, has met with considerable objection. It has been urged that such a procedure may cause inflammation and other serious consequences. It does not appear to me that these objections are substantiated by experience, or by sufficient reason. Sponge-tents have been long employed for the purpose of inducing premature labour. Dr. Lee has sanctioned by his example their use for this purpose. The state of the cervix during early pregnancy does not differ widely from that of the cervix when an intra-uterine polypus exists. When a polypus is present, under the influence of the attendant hæmorrhage, leucorrhœa, growth of the tumour, and action of the uterus, the cervix is already dis-

posed to relax and to expand; and it does not seem reasonable to apprehend that the presence of a soft piece of sponge in the os uteri should be more hurtful or dangerous than the oftentimes far greater pressure exerted upon the cervix by a polypus. Under many circumstances, of not greater urgency, that occur in obstetric practice, those physicians who express so much dread of the possible effects of the sponge-tent, do not hesitate to enjoin the violent expansion of the uterine neck by the hand.

To exclude this application of an agent which experience has proved to be both safe and effectual, is, in effect, to pronounce—in the case of an obscure disease, situated higher up than the os uteri, however threatening to life—that the resources of medicine are exhausted, and that the patient must be abandoned. To urge, as it has been urged, that if you wait long enough, the polypus, if present, will not fail to make its way into the vagina, is to advocate a delay that may be fatal. The treatment, by expectancy, is surely inappropriate when an uncontrollable flooding is fast destroying the patient.

M. Jobert de Lamballe has recently contrived an *intra-uterine speculum*, which may possibly be of service in assisting the visual examination of the uterine cavity and the cavity of the cervical canal. This instrument consists in a hollow cylinder, and a long stem to fit; the circumference is so small, that it can be passed into the uterine neck, the os uteri being previously brought into view by the ordinary speculum. By the withdrawal of a slide attached to the stem, the cylinder may be converted into a groove, so as to permit of an inspection of any part of the canal.

I cannot speak of this instrument from experience. Possibly its utility may fall short of the expectations of the inventor. Its employment would be facilitated by the previous expansion of the uterine neck by means of the sponge-tent.

## ON THE TREATMENT OF POLYPUS.

A survey of the opinions emitted by different practitioners will establish the fact, that the treatment of polypus is not yet settled upon any definite principles. Dupuytren invariably practised excision; others advocate the exclusive use of the ligature. In a recent discussion at the Medical and Chirurgical Society, a great diversity of opinions was made manifest. Mr. Canning, the author of the paper under discussion, considered that the case he related "established a proof that Dr. Locock's plan of excision was preferable in all cases of hard and pedunculated polypi." I think no one plan of treatment can properly be advocated as exclusively applicable to all cases. "Ni jamais, ni toujours," is a maxim of moderation that deserves to be respected in this instance as in most others. The choice of the mode of treatment must be determined by the nature of, and the circumstances attending, the particular case in hand. It is in reference to this question of treatment, that an accurate appreciation of the pathology of polypus is so valuable. If it be possible to lay down any rules defining the practice that should be followed in the treatment of these cases, the surest and the most comprehensive will be those based upon the differential characters of polypi.

It is useful to bear in mind that we are by no means restricted to a selection between the ligature or excision. Several other modes of removal may in particular cases be preferable. Torsion, breaking up by the forceps, and cautery, may often be most usefully resorted to.

Perhaps the rule of practice may admit of being thus generally expressed. Polypi of the muscular variety, arising in the cavity of the womb should be removed by the ligature; polypi of the vascular kind should also be removed by the ligature; polypi of the fibro-cellular kind, springing from the cervix uteri may be removed by excision or by torsion; polypi of the follicular kind may be removed by excision.

But the rule of practice admits of no more than a general

expression. It cannot be laid down with absoluteness. Each of the propositions I have submitted must be received with a liberal interpretation. Particular facilities or difficulties may often justify a departure from the more general principle of conduct. And I think it useful to consider some of the more usual circumstances which may influence our decision.

In the case of muscular polypi of large size which have descended into the vagina, when the neck is large, and the presumption that it contains vessels of considerable size exists, the propriety of resorting to the ligature is apparent: but as the process of detachment may occupy a long time, and there is some danger of further injury to the system from the absorption of putrid discharges, it may be advisable to excise the tumour below the ligature.

Many cases of small muscular polypi still enclosed in the uterus may give rise to embarrassment. In these cases it will rarely be possible to pass a bistoury or curved scissors into the cavity of the uterus with safety; but it will often be possible to apply the ligature by means of Gooch's double canula. To facilitate the application of this instrument, it may be desirable to dilate the cervix by means of sponge-tents. When the double canula cannot be applied, it may be still possible to apply a ligature round the neck of the tumour by means of Mr. Brooke's ingenious instrument for tying knots.

In some cases it will be better to remove the tumour at once by cutting through the neck with a silver wire, as practised by Dr. Simpson. This proceeding differs from ablation by the knife or scissors, in bruising or tearing the bloodvessels of the pedicle, and so lessening the risk of hæmorrhage.

In the case of the fibro-cellular polypi of the cervix, we are governed very much in the choice of proceeding by the size and accessibility of the tumour. If of large size, and very vascular, the safest mode is that by torsion. If not readily reached by the forceps, the instrument contrived by Dr. Locock may enable us to divide the neck. This is a kind of scoop, carried up into the cervix by means of a canula.

If of small size, and there be no fear of hæmorrhage, fibro-cellular polypi may be removed by cutting through the neck with a curved bistoury or scissors. If of very small size, they may be crushed or torn off by the forceps, or even by the finger-nail. Dr. Montgomery says he has cured some small polypi by caustic alone.

The follicular polypus, growing by a large basis from the margin of the os uteri, may for the most part be readily removed by excision; and in many cases the best mode of excision will be to cut through the neck with a silver wire, or a slender but strong ligature of silk or whip-cord.

Is it possible to cause the disappearance of fibroid tumours and fibroid polypi without having recourse to ablation? Can we hope by local and constitutional means to arrest the growth, and bring about the degeneration of these bodies? In those cases where these outgrowths have assumed a polypoid form so as to come within the reach of the surgeon, the question of removal by any other than direct surgical operations is one of little importance. But in the case of fibroid tumours still imbedded in the walls of the uterus, placed by this circumstance beyond surgical interference, the question assumes the greatest interest. The simultaneous growth of fibroid tumours with the enlargement of the womb during pregnancy, and their simultaneous retrocession after delivery, prove that the abnormal and the normal muscular tissues may be affected by the same influences. The history of these fibroid tumours also seems to show that they have a period of active growth and vitality, followed by a period of inertness, during which they may pass into various forms of atrophy and degeneration. It is not unreasonable to expect that this period of growth may be shortened, and the advent of degeneration hastened.\* Ordinary

---

\* Since this memoir was written, I have had an opportunity of reading the elaborate "Report on the Surgical Treatment of Certain Fibrous Tumours of the Uterus heretofore considered beyond the Resources of Art," by Dr. Washington Atlee. I have given an analysis of this work in the Quarterly Report on Midwifery in the *British and Foreign Medico-Chirurgical Review* for July. The possibility of bringing about the degeneration of fibroid tumours artificially

hypertrophy of the uterine neck often yields to local and general treatment. Enlargement of the body of the uterus itself is frequently successfully treated. As a general law in pathology, the vitality of morbid growths is less vigorous than that of the healthy structures. Thus morbid growths are commonly less able to resist the operation of remedial agents. During the stage of activity of fibroid tumours, every precaution should be taken to maintain quiescence of the uterus; every stimulus to the afflux of blood, local and constitutional, to this organ should, as far as possible, be rigorously excluded. The periodical excitation attending upon ovulation and menstruation cannot, of course, be escaped from. But this is less conducive to the growth of tumours, and infinitely less dangerous than pregnancy. The latter risk may be avoided. The removal of every cause that can favour vascular activity of the uterus is, in my opinion, the leading indication.

I am not desirous of extending the limits of this treatise by entering upon a discussion of the various modes of treatment which have been employed with a view to the subduing of

---

has been illustrated by Dr. Atlee in a series of cases, of which it is not unjust to say, that they are more remarkable for audacity in treatment than success in result. His principle of proceeding is thus expressed:—"These tumours are very imperfectly organized; consequently their vitality may be very easily destroyed. A section made through their thin investing membrane will sometimes be followed by the death of the whole mass. This may be owing to the admission of atmospheric air causing it to degenerate. Indeed it would appear that the action of the oxygen of the air, like a portion of yeast in a fermentable mass, may originate in any part of a fibrous tumour an action of *eremacausis*, which may extend throughout the whole." Acting upon this view, Dr. Atlee has treated many tumours of enormous size, imbedded in the walls of the uterus, by free incisions carried into their substance, and attempts at enucleation by the aid of instruments, and repeated doses of ergot of rye. Some of the tumours have thus been more or less broken up, and more or less completely removed. In some cases death has followed the operations. I think the change which took place in the tumours operated upon by Dr. Atlee was mortification or gangrene rather than degeneration, properly so called, or *eremacausis*. I doubt very much whether the history of the cases reported by Dr. Atlee afford much encouragement to follow his example. There must be few women whose constitutions, previously shattered by exhausting hæmorrhages, would be able to survive the severe and protracted and repeated operations recommended by that courageous practitioner.—August, 1854.



uterine tumours ; but in postponing the consideration of this subject I would urge the importance of a steady perseverance in the endeavour to arrest the development of tumours which exhibit a disposition to grow. Discouraging as the effort frequently is, it is not always so. Experience has amply shown that the growth of uterine tumours may sometimes be controlled.

There is another point connected with the treatment which requires to be noticed. It is frequently not enough to remove the polypus in order to restore the patient to health. In many cases the polypus has, during its sojourn in the uterus or cervix, produced effects which will not disappear on the simple removal of the cause. This point had never, I believe, been sufficiently insisted upon, until Dr. Henry Bennet and Dr. Montgomery showed that the irritation and pressure caused by the presence of a polypus frequently gave rise to a great amount of congestion, inflammation, hypertrophy, and sometimes ulceration of the cervix. If these conditions be not subjected to special treatment they may still continue to keep up hæmorrhage and leucorrhœa, and to frustrate the success of the operation. It is in all cases necessary to make a careful examination within a short time after the removal of a polypus, in order to ascertain whether the uterus and the cervix have returned to their normal condition.

In addition to these secondary local effects of polypi, which often require after-treatment, the constitutional effects will almost in every case demand the most serious attention.

The law expressed in the maxim, "*Sublata causa, tollitur effectus*," would be more true with this modification : the cause being removed, the effect *admits of being removed* also. In many cases it is necessary to persevere for a long time in the cautious and steady pursuit of a reparative course of treatment. But as the treatment called for presents no feature of a special character, nor differing from that indicated in other states, in which the system has been impaired by loss of blood, and the degradation of its properties, it is not my intention to enter into any details upon this subject.

APPENDIX TO A MEMOIR ON UTERINE POLYPUS: ITS NATURE,  
EARLY DETECTION, AND TREATMENT.A CASE OF INTRA-UTERINE POLYPUS, UNDISCOVERED DURING  
LIFE, CAUSING HÆMORRHAGE AND DEATH.

CASE 9.—Since my memoir “On Uterine Polypus” has been published, a case has occurred, offering a striking demonstration of the value of the rule in practice I ventured to enforce. I think it will be impossible to peruse the following facts without being struck with the conclusion, that a timely diagnosis of the nature of the case, and surgical intervention, might have rescued the patient.

In the night of the 3rd of August, my colleague, Dr. Ramskill, was called to see a young woman who was suffering from uterine hæmorrhage. The history of the case is briefly this: the patient was twenty-six years of age; she began to menstruate at the age of fourteen, and this function was performed very regularly until her marriage, eight months ago. From that time she has suffered almost perpetual hæmorrhage. A month ago, the flooding was so profuse that it was thought she had miscarried. Since then there have been slight occasional intermissions, but her health was deeply impaired. When Dr. Ramskill was called the hæmorrhage had returned. He observed strong bearing-down, expulsive efforts. The patient died the same night in convulsions, evidently from loss of blood.

The body was examined by Dr. Ramskill on the following day. The organs were all healthy. There was no abdominal inflammation. The os uteri was healthy, but flaccid; it was filled with a fresh clot. There was also blood in the cavity of the uterus. The larger portion of the uterus, with a body adhering to the inner wall, was forwarded to me by Dr. Ramskill.

I subjected the parts to a careful examination. The walls of the uterus were dense, pale, somewhat thicker than natural, and the whole size of the organ somewhat larger than the

normal unimpregnated womb. There was no tumour or other abnormal condition of the muscular wall, but attached to the inner surface near the fundus, and altogether enclosed within the cavity of the uterus, was a tumour of the size of a small walnut. The tumour did not reach to the uterine neck. The mucous membrane of the cavity was stretched over it. It was connected by a broad basis to the uterus, but would have admitted of isolation by ligature. The apex, or most projecting part, had undergone partial disintegration; it was a little broken up, softened, and had evidently quite recently been the source of hæmorrhage. Examined by the aid of the microscope, the substance was found to consist of nucleated fibres, the nuclei being large and distinct. Portions, especially those taken from near the apex, exhibited abundance of oily globules and numerous blood-globules. The structure of the tumour differed from that of the uterine wall in this respect only, that the fibres in the latter were longer, narrower, and more densely interwoven, and the nuclei less distinct. There was no evidence of fatty degeneration in the fibres of the uterine wall. There was no doubt greater developmental activity in the tumour than in the uterus.

The practical deductions from this case are of the highest interest and importance :

1. The condition of the uterine muscular walls leads me to conclude that the conjecture that the patient had aborted a month before her death was erroneous.
2. The comparative indolence of the tumour, and the absence of any remarkable amount of hæmorrhage up to the period of marriage, and the constant floodings following immediately upon that event and continuing until the death of the patient eight months afterwards, forcibly illustrate the influence of ovarian and uterine stimulation in developing the growth of uterine polypi.
3. The case is peculiarly one of that class to which I have pointed as strongly indicating the necessity of exploration beyond the os uteri. In this instance the os uteri was found

healthy; there was no obvious sign of local disease to explain the hæmorrhage; the bulk and weight of the uterus were rather above the normal standard; the figure of the organ was regular. Everything pointed to the uterine cavity as the seat of the cause of the hæmorrhage. It is, in short, the type of the class of cases in which the dilatation of the uterine neck is indicated.

4. The operative proceeding which in my opinion would have been the means of rescuing this poor woman from bleeding to death, is the following: repeated doses of ergot of rye, and the application of galvanism to aid the natural efforts of the uterus to effect the scission and expulsion of the tumour; and the dilatation of the uterine neck by sponge tents. By these means combined, no long period would have elapsed before the tumour would have been brought into view. If it had been then found difficult to encircle the neck of the tumour with a ligature, the operation might have been facilitated by bringing the tumour lower down by the aid of a tenaculum. In the present case, I believe the tumour admitted of being so removed. But we may imagine a case where ablation would not have been expedient or possible. In such a case, the local application of the acid nitrate of mercury, potassa fusa, or the actual cautery might have been justifiably resorted to in order to arrest a hæmorrhage that was fast hurrying the patient to the grave. Such an application might also cause the destruction of the tumour by disintegration or degeneration.

5. The softening and partial breaking up of the tumour observed after death suggests to me that the microscopical examination of the discharges might have detected some of the constituent nucleated fibres of the tumour, and have aided the diagnosis.

6. I would finally remark, in answer to those who deprecate any operative interference with polypi that have not yet made themselves visible at or below the os uteri, that the intervention of surgical aid is not indicated by the mere position of the

polypus, which is altogether unimportant, but by the terrible attendant hæmorrhage, no matter where the polypus may be. If this be so, and surely the proposition cannot be disputed, then it follows that the removal of an intra-uterine polypus may be as urgently called for as the removal of one that has descended into the vagina.

In the case of an abortion, or of the retention of a portion of placenta, no obstetric practitioner is ever satisfied as to his patient's safety until the offending substance is removed from the uterus. Why should the patient be abandoned when the offending substance is a polypus?

13, Devonshire-square, August, 1854.



