



Bodleian Libraries

UNIVERSITY OF OXFORD


This book is part of the collection held by the Bodleian Libraries and scanned by Google, Inc. for the Google Books Library Project.


For more information see:

<http://www.bodleian.ox.ac.uk/dbooks>



This work is licensed under a Creative Commons Attribution-NonCommercial-ShareAlike 2.0 UK: England & Wales (CC BY-NC-SA 2.0) licence.










THE STUDENT'S GUIDE
TO
SURGICAL ANATOMY



THE STUDENT'S GUIDE
TO
SURGICAL ANATOMY

A DESCRIPTION OF THE MORE IMPORTANT SURGICAL
REGIONS OF THE HUMAN BODY, AND AN
INTRODUCTION TO

OPERATIVE SURGERY

By EDWARD BELLAMY, F.R.C.S.

HON. FELLOW OF KING'S COLLEGE, LONDON; SURGEON TO, LECTURER ON ANATOMY,
AND FORMERLY TEACHER OF OPERATIVE SURGERY IN CHARING CROSS HOSPITAL;
LECTURER ON ANATOMY, AS APPLIED TO THE FINE ARTS, TO THE SCIENCE
AND ART DEPARTMENT, SOUTH KENSINGTON



SECOND EDITION, ENLARGED AND REVISED

165 . g . 57 .

LONDON

J. & A. CHURCHILL, NEW BURLINGTON STREET
1880

“ LES FORMES EXTÉRIEURES, PAR LEURS RELATIONS AVEC LES FORMES INTÉRIEURES, MONTRENT À L'INTELLIGENCE DU CHIRURGIEN, CE QUI EST CACHÉ DANS LA PROFONDEUR DU CORPS, PAR CE QUI EST VISIBLE À SA SURFACE.” (*Gerdy.*)

TO


JOHN WOOD, F.R.S.,

SURGEON TO, AND PROFESSOR OF SURGERY IN KING'S COLLEGE,

This small volume is Inscribed,

BY HIS FORMER PUPIL,

T H E A U T H O R.



PREFACE TO SECOND EDITION.

A SECOND edition of my manual having been asked for, I trust that in it most of the errors of omission and commission which appeared in the first have been rectified. I have re-written and re-arranged the greater part of it, added more clinical matter, and a larger number of drawings.

The difficulty of condensing such a subject as Applied Anatomy into so limited a compass is immense, and my attempt must merely be considered in the light of a *guide*—I hope a trustworthy one—to the student for his “Pass” examination, offering a series of suggestions to work upon, or an introduction to those more complete works, which I regret to say at present exist only in foreign tongues (Luschka, Hyrtl, Richet, Rüdinger, Tillaux, and others). Should I have the opportunity or leisure, I hope at some future period to elaborate my subject and endeavour to assist in filling up this gap in English literature.

I must acknowledge my indebtedness to these authors, and more especially to Tillaux, whose work I consider the most practical yet produced.

I do not profess to have described all the regions of the body, or to have taken them in strict anatomical sequence, and it will be observed that those portions

of Anatomy, which are more directly associated with "Specialities"—*e.g.*, the eye, the ear, and certain of the viscera—for the present, I consider it advisable either to omit or to touch upon but superficially, referring my readers to works on these particular subjects.

The new wood-cuts are either suggested by or reduced, by permission, from "Braune's Plane Sections of Frozen Bodies," from Henle or Tillaux, to save the great expense of making original preparations, which must of necessity have yielded very like results. I would particularly recommend the careful study of Braune's plane sections to those students who intend presenting themselves for the Fellowship or M.B. examination, and to surgeons and practitioners generally, as being the only work of the kind at present within their reach in English. Braune's work teems with valuable hints, deductions, and applications, of many of which I have availed myself.

The illustrations have been drawn on wood by Mr. Collings and myself.

My best thanks are due to my friend Mr. Johnson Smith, F.R.C.S., Surgeon to the Seamen's Hospital, for his kindness in seeing the volume through the press, and for many valuable hints.

I should be pleased if any physician could be induced to supplement my work by a "Student's Guide to Medical Anatomy," a volume I feel sure is wanted.

EDWARD BELLAMY.

17, WIMPOLE STREET,

December, 1879.

PREFACE TO FIRST EDITION.



A CONSIDERABLE experience as a teacher has convinced me that there is room for a small work on what may be termed Applied Anatomy. With the exception of my friend Mr. Galton's translation of Professor Roser's work, there is no English handbook of the kind within the reach of the generality of students.

Pupils are apt to lay aside their anatomical studies after having passed their "primary" examination, and to be confused at finding a considerable amount of Surgical Anatomy required of them when they present themselves for their final or "pass."

With a view of assisting them, this work has been prepared. A knowledge of Descriptive Anatomy is presupposed, and such regions of the body as do not seem to bear directly upon the operative or more practical parts of Surgery, have been either merely referred to or entirely omitted.

I do not hesitate to state that I have in one or two instances availed myself of methods of arrangement adopted by others; yet all the statements have been confirmed by actual demonstration, and may be regarded as an embodiment of the remarks made to the students attending my course of Operative Surgery at Charing Cross Hospital.

The engravings are, in some instances, borrowed by permission from Mr. Heath's excellent work on Practical Anatomy, or have been drawn upon wood from nature, by Mr. Wesley, Mr. Sherwin, and myself, or have been adapted from such sources as will be found acknowledged in their proper places.

I have to express my obligation to my friend Mr. James Cantlie, M.A., F.R.C.S., Demonstrator of Anatomy and now Assistant-Surgeon at Charing Cross Hospital, for his kindness in revising the proofs, and for other valuable assistance.

EDWARD BELLAMY.

MARGARET STREET, CAVENDISH SQUARE,

October, 1873.

INTRODUCTION.



As the subject of Regional Surgery and Surgical Anatomy bears directly upon Operative Surgery, it may not be considered out of place to remind the student of the necessity of making most careful inspection of the body as a whole before he attempts the more minute and detailed examination of its various parts. For this purpose both the living model and the dead subject should be examined together. For such examination the body should be laid on its back—in fact, in the position a patient would be placed in for a surgical examination or operation. By the side of the body should be placed an entire articulated skeleton. Careful notice is to be taken of all the surface-markings, and of the superficial bearings of all prominent underlying structures, such as the subcutaneous surfaces of the bones, ligaments, tendons, and bursæ; the proper swellings, or *contouring*, of the muscles, both at rest and in action; the course of the superficial and deep vessels; the change of aspect in regions, dependent upon alteration of position; the course and direction of the several natural passages of the body; the ana-

tomical relations of the lines of incision required in the various operations of surgery; and the altered positions of dislocated bones as compared with their normal relations.

In studying Regional Anatomy the parts must be regarded as being wounded, either by the surgeon's knife or by some weapon, or displaced by accident. In the various stages of a dissection made in the prosecution of Descriptive Anatomy, it is often the end and aim of the dissector to make a clean or "pretty" preparation, in following out the different vessels, nerves, &c., and for this purpose it is quite right that all pains be taken, but the student must remember that the more he cleans the more he destroys the actual relation of the parts as they would be met with in an operation; and, moreover, he must remember that the very fasciæ he so studiously removes are of the greatest importance in Surgical Anatomy, and that the removal of these structures destroys surgical continuity.

The want of material in our schools is the great drawback to the study of Topographical Anatomy, as bodies cannot be spared for such sections and special examinations as a proper study of the various operative proceedings of surgery suggests.

C O N T E N T S.



CHAPTER I.

	PAGE
Surgical Anatomy of the Cranial Region : The Cranium ; Occipito-frontal Region ; Structures which would be divided in cutting down upon the Bone in the Occipito-frontal Region ; Temporo-parietal Region : Structures divided in cutting down upon the Bone in the Temporo-parietal Region ; The Bones of the Cranium ; Relations of the Cerebrum to the Cranium ; The Face, Blood-vessels, Nerves, and Lymphatic Glands—The Region of the Orbit ; Palpebral Region ; External Orbital Region, Superciliary and Palpebral ; Palpebral Conjunctiva ; Ocular Conjunctiva ; Lachrymal Apparatus, Canals, and Sac ; How to introduce a Probe into the Nasal Duct by the Punctum Lachrymale ; Internal Orbital Region ; Contents of the Orbital Cavity ; Relations of Parts within the Orbit ; Structures divided in the Operation of Extirpation of the Globe and in the Operation for Strabismus—The Nasal Region—The Nasal Fossæ and Sinuses of the Nose ; Orifices of the Nasal Fossæ : The Anterior and Posterior Nares ; The Sinuses of the Nose : The Frontal, Sphenoidal, and Superior Maxillary—The Superior Maxillary Region : Articulations of the Superior Maxilla ; Structures divided in Excision of the Upper Jawbone—The Region of the Soft Palate and Tonsil—The Parotid Region ; Relations and Connexions of the Parotid Gland—The Pterygo-Maxillary Region ; Temporo-maxillary Articulation ; The Lower Jawbone liable to partial or complete Dislocation—The Lingual Region—The Pharynx.. .. .	1

CHAPTER II.

	PAGE
Surgical Anatomy of the Neck: Surface-markings; Arrangement of the Cervical Fasciæ; Cellular Spaces which may be the seat of Abscess: The Capsule of the Submaxillary Gland; The Pre-visceral Space; The Perivascular Space; The Space beneath the Lower Portion of the Sterno-Mastoid; The Retro-pharyngeal or Retro-visceral Space; Prevertebral Abscesses—The Submaxillary Region: Ligature of Lingual Artery—The Infra-Hyoid or Laryngo-Tracheal Region: Laryngotomy; Tracheotomy—The Œsophagus: The Operation of Œsophagotomy—The Sterno-Mastoid Region: Structures superficial to the Sterno-Cleido Mastoid; Parts beneath—Common Carotid Artery: The External and Internal Carotid Arteries, and their Relations; Ligature of the Common Carotid, above and below the Omo-Hyoid; Collateral Circulation after Ligature of the Common Carotid; Ligature of the External Carotid; Collateral Circulation after Ligature of the External Carotid—The Subclavian Region: its Relations; Collateral Circulation developed after Ligature of the Third Part of the Subclavian Artery—The Innominata: Collateral Circulation developed after Ligature—Region of the Nape of the Neck (Posterior Cervical Region)—Vertebral Column in the Cervical Region	61

CHAPTER III.

Surgical Anatomy of the Thorax: Relation of the Structures passing through the Superior Aperture of the Thorax; Auscultation and Percussion; Position of the Lungs, Heart, and Great Vessels with regard to the Surface; Walls of the Thorax; The Operation of Paracentesis Thoracis; The Mammary Region; Spinal Region of Thorax; Vertebral Column in the Dorsal Region; Injuries to the Cord in the Dorsal Region; Cavity of the Thorax	104
---	-----

CHAPTER IV.

	PAGE
Surgical Anatomy of the Upper Extremity: Region of the Shoulder; Anterior and Lateral Aspects of the Shoulder; Clavicular Region; Posterior Aspect of the Shoulder, or Scapular Region; Articulation of the Shoulder-joint; Contents of Flaps after Disarticulation at Shoulder-joint by Transfixion—The Axilla: Contents of the Axillary Space; The Axillary Fasciæ; Relations of Axillary Artery; Ligature of the Axillary Artery; Collateral Circulation after Ligature—The Brachial Region: Relations of the Brachial Artery; Branches of the Brachial Artery—The Region of the Elbow: Bend of the Elbow; Vertical Section through the Elbow-joint; Fractures of the Humerus—The Forearm: Relations of the Radial and Ulnar Arteries in the Forearm—The Region of the Wrist: Anterior and Posterior Regions; Articulations of the Wrist-joint—The Hand: Palmar Region; Synovial Membranes of the Palm	120

CHAPTER V.

Surgical Anatomy of the Abdomen: Relations of the Viscera to the Abdominal Parietes—The Antero-Lateral Region of the Abdomen—The Inguinal Region: Parts concerned in Inguinal Hernia—The Crural Region: Crural Canal; Artificial Anus—The Iliac Fossa; Posterior Wall of Abdomen; The Common Iliac; Ligature of Common and External Iliac Arteries—The Lumbar Region: Lumbar Colotomy; Structures divided in Amussat's Operation by Transverse Incision; Lumbar Fascia; Sacro-Iliac Disease—The Pelvis—The Pelvi-Perineal Region: Scrotum; Hydrocele; Testis; Structures divided in the Operation of Castration—The Male Perineum—Lithotomy in the Male—The Penis—The Male Urethra—Lithotomy in the Female—The Female Perineum—The Cavity of the Pelvis—The Bladder—Relations and Ligature of the Internal Iliac Artery—The Rectum: Relation to the Peritoneum	176
--	-----

CHAPTER VI.

	PAGE
Surgical Anatomy of the Lower Extremity—The Superior Femoral Region : Scarpa's Triangle ; Ligature of the Femoral Artery in Scarpa's Space—The Gluteal Region : Obturator or Ischio-Pubic Region—The Hip-Joint : Dislocation of the Head of the Femur ; Structures divided in Amputation, through the Hip-Joint by the antero-posterior Flaps ; Excision of the Hip-Joint—The Middle Femoral Region ; The Femoral Artery in the Middle of the Thigh—The Region of the Knee—The Popliteal Space and Artery ; Relations of the Popliteal Artery—The Knee-Joint : Dislocations of the Patella ; The Articulation between the Femur and the Tibia : Movements of the Knee-Joint ; Excision of the Knee-Joint—The Leg : The Anterior, Exterior, and Posterior Regions ; Ligature of the Anterior and Posterior Tibial Arteries ; Fractures of the Tibia and Lower End of the Fibula—The Tibio-Tarsal Region : Ligature of the Posterior Tibial Artery at the Inner Malleolus ; The Tibio-Tarsal Articulation ; Excision of the Ankle-Joint ; Amputation at the Ankle-Joint—The Foot : Tarso-Metatarsal Region ; Ligature of Dorsalis Pedis Artery ; Plantar Region ; Club Foot (Talipes) : The Tarso-Metatarsal Articulation : Structures divided in Hey's Amputation ; Synovial Membranes of the Tarsus and Metatarsus—Toes	241

LIST OF ILLUSTRATIONS.



FIGURE	PAGE
1. Diagram of Structures to be avoided in using the Trepine	8
2. Relation of the Cerebral Convolution to the Skull. After Broca	10
3. Horizontal Section of the External Auditory Meatus. After Tillaux	14
4. Lachrymal Apparatus and Nasal Duct	23
5. Diagram of the Relations of the Lachrymal Sac. After Tillaux	25
6. Aponeuroses of Orbit	27
7. Aponeuroses of Orbit. After Tillaux	29
8. Section of Nasal Fossæ (Sagittal). After Henle..	34
9. Section of Nasal Fossæ (Frontal). After Henle ..	35
10. Section of Pharynx	38
11. Diagram of the Relations of the Tonsil	48
12. Sketch of Deep Connexions of the Parotid ..	51
13. Roof and Posterior Wall of Pharynx. After Luschka	59
14. Diagram of the Fasciæ of the Neck in the Mesial Plane. After Tillaux	65
15. Diagram of the Fasciæ of the Neck through the Middle of the Clavicle. After Tillaux	66
16. Section of Neck through the Sixth Cervical Verte- bra. After Braune	83
17. Common Carotid Artery and its Branches	87
18. Diagrammatic Section through Clavicle and Thorax	94
19. Region of third part of Subclavian Artery.. .. .	96
20. Relations of Thoracic Viscera to Walls of Chest ..	106
21. Vertical Section of Sixth Intercostal Space. After Tillaux	109

FIGURE	PAGE
22. Antero-lateral Region of Shoulder	123
23. Vertical Section through Right Shoulder-joint ..	126
24. Transverse Section through Shoulder-joint, and passing through the Trunk at the level of the Third Dorsal Vertebra. After Braune	129
25. Section through Shoulder-joint to show condition of Capsule in extreme rotation outwards. After Henle	130
26. Frontal Section of Shoulder-joint, showing Dis- tension of Capsular Ligament. After Braune..	131
27. Axilla. After Pirogoff	132
28. Ligature of Axillary Artery	139
29. Transverse Section of Right Upper Arm. Heath	143
30. Bend of Elbow. After Blandin	148
31. Structures in Relation with the anterior aspect of the Elbow-joint	151
32. Longitudinal Section of Elbow-joint. After Braune	152
33. Vertical Section of Elbow-joint. After Braune ..	153
34. Transverse Section through middle of Right Fore- arm. Heath.. .. .	156
35. Transverse Section of Carpus through the middle of the Pisiform Bone. After Henle	161
36. Transverse Section of Carpus through the first row of Carpal Bones. After Henle	162
37. Transverse Section of Carpus through the Unciform Bone. After Henle	164
38. Longitudinal Section of the Wrist-joint through the Radius and Middle Finger. After Braune..	165
39. Relation of the Palmar Arches to the Skin-folds. After Tillaux	167
40. Transverse Section of the Hand through the Carpo- metacarpal Joints. After Henle.. .. .	170
41. Anterior Aspect of Fingers. After Blandin ..	172
42. Dorsal Aspect of Fingers. After Blandin.. ..	174
43. Superficial Dissection of the Inguinal and Femoral Regions. Wood	182
44. Dissection of Lower Part of Abdominal Wall from within, after Removal of Peritoneum. Wood ..	185
45. Dissection of Inguinal Canal. Wood	187

FIGURE	PAGE
46. Diagram of Congenital Hernia. Heath	189
47. Diagram of Infantile Hernia. Heath	189
48. Crural Sheath laid open. Wood.	192
49. Irregular Course of Obturator Artery	194
50. Sketch of Artificial Anus	194
51. Section of Abdomen between the Third and Fourth Lumbar Vertebræ. Braune	202
52. Arrangement of Lumbar Aponeurosis at level of Third Lumbar Vertebra	204
53. Section of Spermatic Cord	210
54. Hydroceles	212
55. Perineum	224
56. Sagittal Section of Male Pelvis in the Mesial Plane. After Braune	228
57. Sagittal Section of Female Pelvis in the Mesial Plane. After Legendre	237
58. Superficial Dissection of Front of Thigh. Heath	244
59. Transverse Section of Hip-joint. Braune.. ..	253
60. Sagittal Section of Hip-joint and Gluteal Region. Beraud	257
61. Horizontal Section through Hip-joint. Braune ..	258
62. Section of Thigh at the Apex of Scarpa's Space. Heath	263
63. Popliteal Space. Heath	270
64. Knee-joint Opened Vertically. After Beraud ..	274
65. Horizontal Section of Knee-joint	275
66. Vertical Section of Knee-joint. After Braune ..	276
67. Section of Calf of Leg. Heath	279
68. Relations of Parts at Inner Malleolus. Heath ..	284
69. Horizontal Section of Ankle. Heath	286
70. Vertical Section of Ankle-joint. After Henle ..	287
71. Vertical Section through the Anterior Astragalo- calcanean Articulation. After Henle	288
72. Vertical Section through the Cuneiform and Cuboid Bones	292
73. Longitudinal Section of Foot. After Braune ..	293
74. Diagram of the Lines of Incisions in the several Ex-articulations of the Foot	295
75. Vertical Section through the Posterior Astragalo- calcanean Articulation. After Henle	296
76. Sketch of the Articulations of the Foot	298

ERRATA.

Page 10, line 1, for "pro" read "pre."

Page 22, line 11, for "recto" read "recti," and delete hyphen.

Page 34, Description of Fig. 8, for "maxillaries" read "maxillaris,"
in two cases.

Page 59, bottom line, for "axis" read "atlas," and for "artery" read
"axis."

Page 60, line 1, for "borders" read "border."

Page 60, line 2, for "vertebræ" read "vertebra."

Page 110, line 33, for "emphysema" read "empyema."

Page 120, line 20, for "corresponds" read "correspond."

Page 125, line 6 from bottom, delete "back of."

Page 253, Fig. 59, scale should be "one-third," not "one-fifth."

SURGICAL ANATOMY.



CHAPTER I.

SURGICAL ANATOMY OF THE CRANIAL REGION.

THE head is composed of two portions, which may be examined surgically, the Cranium and the Face.

THE CRANIUM.

For surgical purposes the structure of the vault of the skull will suffice for description, since the base is, so far as any operative proceedings are concerned, out of reach, and those contents of the cranial cavity which have any direct relation to practical surgery will receive brief notice in their proper place.

The regions into which the vault of the cranium is divided for the sake of surgical reference, differ in number and extent in the various works upon the subject—thus some authors make four:—the occipito-frontal, the temporal, the auricular, and the mastoid; but for simplicity and more ready reference the following would seem to suffice—viz., the *occipito-frontal* and the *temporo-parietal*.

OCCIPITO-FRONTAL REGION.

The occipito-frontal region is oblong in shape. Its limits are—anteriorly, the superior margins of the orbital cavities, and the articulations of the frontal with the

superior maxillary and nasal bones; posteriorly, the superior curved line of the occipital bone, and on each side the temporal ridge.

Surface markings.—Anteriorly, are the frontal eminences, corresponding with the development of the frontal sinuses; laterally, are the parietal eminences; and posteriorly the external occipital tuberosity, which corresponds with the confluence of the sinuses.

Topography.—The integument is tolerably thick, smooth, and somewhat uneven in surface. It is very rich in sebaceous follicles, and these, by the inspissation of their contents and closure of their excretory ducts, constitute the encysted tumours or *wens*, so often met with in this region.

The *superficial fascia* does not exist, the skin being firmly united to the subjacent tissues by numerous trabeculæ, which enclose irregularly shaped nodules of fat, forming a densely lamellated layer. The scalp is highly vascular, and is frequently the seat of aneurisms by anastomosis, erectile tumours, etc.

The musculo-aponeurotic lamina beneath this, is the occipito-frontalis muscle, which consists of two muscular bellies, which are situated in the anterior and posterior portions of this region, the anterior occupying the entire forehead, being attached to the superciliary ridge and nasal bones, and sending a slip downwards to the pyramidal muscle. The posterior is rather larger, and is attached to the superior-curved line, together with the tendinous expansion which is intermediate between these muscular masses. This expansion is called the *epicranial aponeurosis*. This aponeurosis is extremely thin over the vertex of the cranium, but very thick in the temporal region, and is attached to the superciliary ridge, the zygomatic arch, and to the superior curved line.

A layer of loose *areolar tissue* separates the epicranial aponeurosis from the periosteum, into which effusions of blood may take place, and is the seat of purulent collections in erysipelas, or after wounds, a condition

demanding free incision down to the bone. In these cases the effusion can be clearly seen to be limited by the attachments above mentioned of the occipito-frontalis muscle and its aponeurosis. Thus a "black eye" can be produced by a blow on the back of the head, by the gravitation of the blood downwards and forwards into the loose subcutaneous tissue of the forehead and eyelids. This aponeurosis is also more adherent to the bones in old persons, and is always more intimately attached along the sutures. In phlegmonous erysipelas of the scalp the pus burrows under this aponeurosis, so that free incisions down to the bone and counter-openings are necessary.

Beneath this cellular layer is the *pericranium* or *external periosteum*, which is much stronger in the child than in the adult: it is frequently the seat of periostitis and nodes. The pericranium seldom reproduces bone after trephining. In scalp wounds the greatest care must be taken to replace the tissues torn off, although it may be mentioned that denudation of the bone is not necessarily followed by necrosis.

Cephalæatomata are met with in this region; these are tumours caused by the rupture of some vessel or vessels beneath the pericranium during parturition. This condition must not be confounded with a blood tumour, the result of injury, and which is formed beneath the tendon of the occipito-frontalis muscle, at a lower level in the cranium.

A thin lamina of lax *connective tissue* is met with between the pericranium and the bone. The structure next in order is the bone itself, which will be found described, together with those of the cranium in general.

The arteries supplying this region lie in the subcutaneous tissue, they run towards the centre of the region, and are very tortuous. They are—in front, the supra-orbital, the frontal, and the superficial temporal, thus forming a free inosculation between the internal and external carotid arteries. Behind, the occipital and the

posterior auricular branches of the external carotid artery freely anastomose with each other, and with the above-mentioned vessels.

The *superficial temporal artery*, which is easily seen beneath the skin in its tortuous course, is liable to injury, which, in the event of the main trunk being divided, either entirely or partially, may be serious by the formation of a false aneurism from the escape of blood beneath the tissues. In such a case the tumour must be opened and the clot turned out, and *both* ends of the bleeding vessel tied. If the operation of arteriotomy be required, the anterior branch of this vessel is to be the one selected, just at the spot where it begins to be covered by the hairy scalp. In performing this operation a small puncture only is necessary, and when complete, the vessel should be *entirely* divided, so that by the retraction of the cut ends the formation of a false aneurism may be prevented. In such plastic operations as the restoration of the upper eyelid, or in rhinoplasty, the preservation of the supra-orbital arteries is of great importance for the proper nourishment of the flap.

Veins.—The arteries are generally accompanied by small veins; one vessel in particular, the *vena præparata*, which is situated in the middle of the forehead, and is plainly visible during bodily exertion or under excitement, is worthy of note. This vein has been proposed as suitable for venesection.

The nerves supplying the muscles and integument, and which follow the course taken by the arteries are, in front, the supra-orbital and supra-trochlear branches of the frontal, and some few inosculating branches of the facial. These nerves are frequently the seat of neuralgia, and for its relief division of the frontal nerve has been proposed at its point of exit from the supra-orbital notch. It is worth remembering that this notch is generally in a line with the fang of the canine tooth.

Lymphatics.—These vessels correspond with the

arrangement of the veins. The superficial lymph-glands of the scalp are plentiful in the occipital region and along the posterior margin of the sterno-mastoid muscle, and become engorged in cases of injury to the scalp, or in constitutional syphilis.

Structures which would be divided in cutting down upon the bone in the occipito-frontal region.—Skin, subcutaneous cellular tissue, occipito-frontalis muscle, and epicranial aponeurosis, a thin layer of lax cellular tissue, and the pericranium; anteriorly the vessels divided are the temporal, the frontal, and the supra-orbital, with the supra-orbital, supra-trochlear, and branches of the auriculo-temporal nerves, and posteriorly the occipital vessels and greater and lesser occipital nerves.

THE TEMPORO-PARIETAL REGION.

This region may be considered as corresponding with the temporal fossa of osteology. The superior limit of this region is the lateral boundary of the occipito-frontal, and its inferior limit is a line drawn from the external angle of the frontal bone to the mastoid process of the temporal.

Topography.—*The integument and subcutaneous cellular tissue* are pretty much the same as in the preceding region. The *superficial fascia* is here developed, but is very thin and cellular, and the mobility of the skin in this region is due to this fact. The *superficial aponeurosis*, very tough, upon which is the temporal artery, beneath it is an aponeurotic lamina having below it some fat and cellular tissue, and containing the small auricular muscles. The foregoing structures are, it will be observed, either entirely or partially common to this and the preceding region.

The temporal fascia is attached above to the curved line limiting the temporal fossa, by a single lamina, and below to the zygoma. This it does by two distinct processes, the superior of which is attached to the external lip of the zygomatic arch, and a deeper,

which is attached along the inner lip. A little fat and cellular tissue lie between them.

Beneath this layer of the aponeurosis is a quantity of *fat*, which, however, is confined to the lower third of the region, separating it from the *temporal muscle*. This muscle corresponds in shape exactly with the fossa, and contains the deep temporal vessels and nerves which enter its deep surface. Below the muscle is the epicranium. The osseous structure of the region will be described in the remarks on the cranium in general.

The *shape* of the zygomatic arch varies in individuals and races; it may be the seat of fracture.

The arrangement of the several aponeuroses in this region determines the course taken by purulent collections, blood, or rapidly growing neoplasia. If deep seated, they may make their way into the zygomatic fossæ, and so into the orbit, pterygoid region, or pharynx, and if superficial they would be limited by the more superficial aponeuroses.

Arteries.—The arteries of this region may be conveniently regarded as divisible into three groups—superficial, intermediate, and deep; the former, the superficial temporal, have been already alluded to. The intermediate are the deep temporal, which, derived from the internal maxillary, enter the under surface of the temporal muscle, are distributed to it, and inosculate with the superficial. The *deep* vessel of the region, separated from the foregoing by the skull itself, the middle meningeal necessarily belongs to this region, as any wound, fracture, or surgical operation, such as trephining, would perhaps involve it. This vessel has the following relations with regard to the surface of the cranium: if an imaginary line be drawn horizontally backwards from the external orbital process, the course of the middle meningeal artery would be found in this line about four-fifths of an inch behind it.

The posterior part of this region, which contains the

mastoid process of the temporal bone, is by some authors described as a distinct one. The external aspect of this process is almost entirely subcutaneous, and is a sort of *point de repère* of the tissues belonging to the occipito-frontal region. The periosteum is very thick, giving attachment to the sterno-mastoid, occipito-frontalis, splenius, and trachelo-mastoid. Surgically it is the seat of an operation proposed for the opening of the mastoid cells, with the object of giving vent to matter pent up in them, should it not find its way either by the Eustachian tube or through the external auditory meatus. The deeper portions of this region will be discussed further on. It must be borne in mind, with regard to the surface, that beneath this process we come upon the dura mater and lateral sinus.

The structures divided in cutting down upon the bone in the temporo-parietal region are—the skin, subcutaneous fascia, epicranial aponeurosis, superficial temporal aponeurosis, deep temporal aponeurosis, temporalis muscle and tendon, with the superficial and deep temporal vessels, nerves, and lymphatics, and periosteum.

SURGICAL ANATOMY OF THE BONES OF THE CRANIUM.

The structure of the cranial bones forming the vault of the skull in the adult consists of three layers: an outer, formed of tough compact tissue; an intermediate, the diploë, soft and spongy, having the diploic veins ramifying in its substance; and an inner, hard and brittle. These diploic veins communicate by a number of apertures, both with the sinuses of the dura mater and the tegumentary veins; these are called the *emissary* veins. Hence a direct communication is kept up between the venous system without and within the cranium. This direct anastomosis explains the mutual relations of inflammation of the integuments and the meninges, the existence of embolism

or thrombosis of the sinuses after anthrax of the neck or face. Again, after injury followed by suppuration, they are liable to inflammation; which explains the formation of secondary deposits of pus in various parts of the body, most frequently in the lungs and liver. The brittleness of the internal layer is of surgical importance, from the fact that, in blows on the head, it is more liable to be fractured than the outer; and cases have occurred where it has been

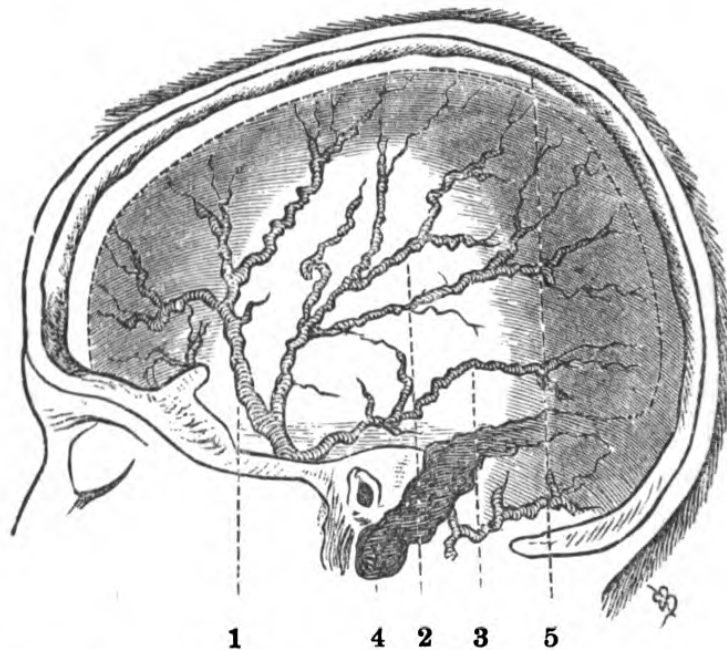


Fig. 1.—Diagram of Structures to be avoided in use of Trepine.

1, 2, 3, branches of middle meningeal artery; 4, lateral sinus; 5, superior longitudinal sinus.

broken without any apparent depression whatever of the external, giving rise to symptoms of compression, which would otherwise have been difficult of explanation. The diploë is not easily distinguished in young persons. In the application of the trephine, the varying densities of the layers of the skull must be borne in mind, as the pressure upon the instrument on its first application should be firm and steady, until the external table is perforated, when there is less resistance. When this is quite perforated the blood of

the diploë will be seen in its teeth. This, however, is not always the case, as the bone dust is stained with blood from the outset of the operation. The pin of the trephine is now to be withdrawn, to avoid its being pushed through the inner table into the dura mater and encephalon; the inner table, though thinner, will be found to offer more resistance to the saw edge. There are certain localities in the skull where the application of the trephine should be avoided. These are—over the longitudinal sinus, the anterior inferior angle of the parietal bone, because of the middle meningeal artery, over the occipital tuberosity, and over the sutures. It is advisable to avoid trephining over the sutures, on account of the passage of the emissary veins and entrance of arteries.

Relations of the cerebrum to the cranium.—The topographical relations of certain portions of the cerebrum with the cranium are of great importance in the diagnosis of the exact position of abscess, or of the nature of the depression of the bone in injury, and the subsequent application of the trephine. It has been thought advisable to give certain measurements, which have been determined by Broca, Turner, and others, as guides for this operation.

The fissure of Sylvius divides into two branches, corresponding with the summit of union of the greater wing of the sphenoid with the temporo-parietal suture, and is normally situate about half-an-inch behind the fronto-parietal suture. The anterior branch is parallel to the fronto-parietal suture, or may be rather higher and parallel, and then passes upwards and backwards, terminating in the semi-circular cranial line.

The fissure of Rolando, as regards its superior portion, is situated about 2 inches behind the fronto-parietal suture, and is directed downwards and forwards, and its inferior portion lies about 1·2 inches behind the fronto-parietal suture, and from about $\frac{1}{2}$ to $\frac{1}{5}$ of an inch higher than the commencement of the temporo-parietal suture.

The pro-central sulcus which skirts the anterior border of the ascending frontal convolution is situated

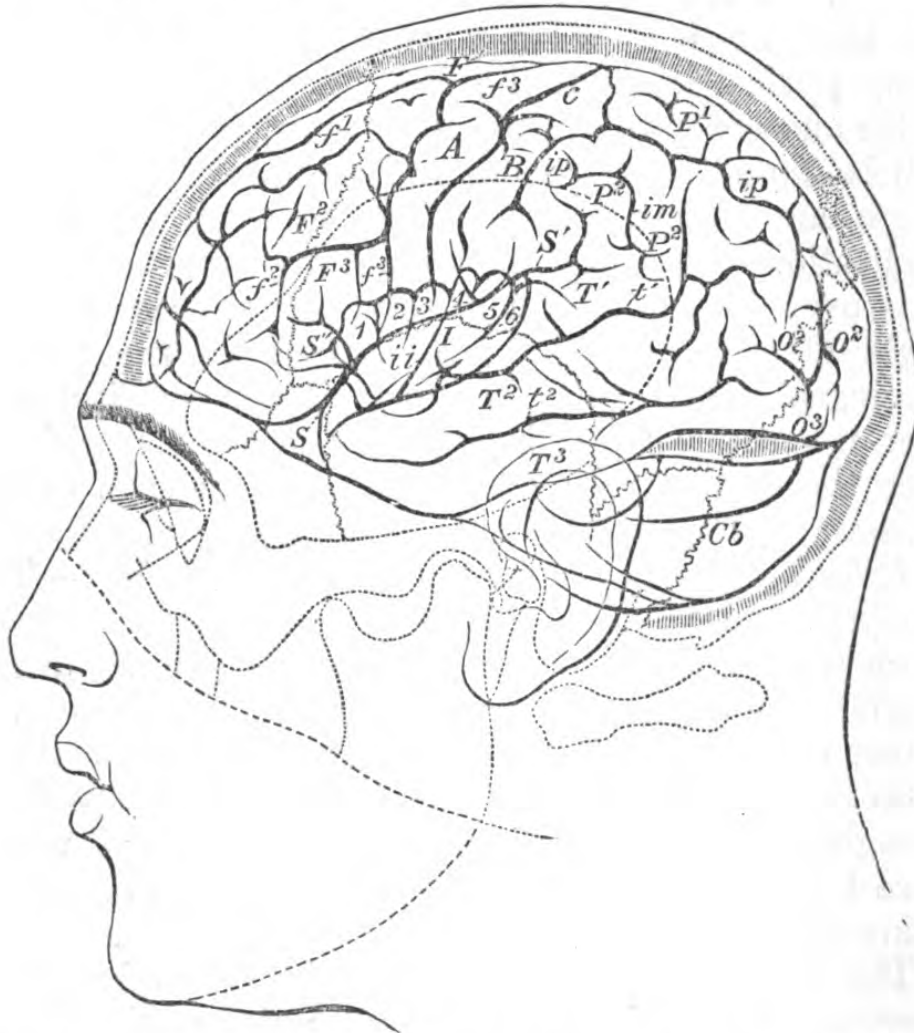

Fig. 2.—Relations of the Fissures and Convolution of the Left Hemisphere of the Brain with the Skull. (One-third.)

The fine line indicates the contour of the skin, the pointed lines the contour of the bone, the sutures, and semi-circular line, the thick lines the contours of the brain and fissures. *S*, the fissure of Sylvius; *S'*, its horizontal portion; *S''*, its ascending portion; *F*¹, *F*², *F*³, the superior, middle, and inferior frontal convolutions; *f*¹, *f*², *f*³, superior, inferior, vertical frontal sulci; *A-B*, ascending frontal, ascending parietal convolutions; *c*, fissure of Rolando; *P*¹, superior parietal convolution; *P*², marginal convolution; *P*^{2'}, curved convolution; *ip*, interparietal fissure; *O*², *O*³, second and third occipital convolutions; *o*², inferior occipital convolution; *T*¹, *T*², *T*³, inferior middle and inferior temporal convolutions; *t*¹, *t*², superior and middle temporal sulci; *I*, Island of Reil; *Cb*, cerebellum.

below at about $\frac{2}{3}$ of an inch behind the coronal

suture, and above at a distance varying between $\frac{4}{5}$ and $1\frac{3}{5}$ inches. The inter-parietal commences above the transverse branch of the fissure of Sylvius $\frac{3}{5}$ or $\frac{4}{5}$ of an inch behind the inferior extremity of the fissure of Rolando.

The point where the internal perpendicular fissure unites with the external perpendicular fissure generally corresponds with the union of the sagittal and lambdoidal sutures. The external perpendicular fissure corresponds with the lambdoidal suture, or crosses it.

The anterior, inferior, and median summit of cerebral hemisphere corresponds with the middle of the mesial line between the naso-frontal suture, and the line which joins the upper border of the orbits. The inferior border of each hemisphere is directed outwards, almost parallel with the superior border of the orbit, and separated from it about $\frac{1}{5}$ of an inch.

The vertical distance between the inferior border of the frontal lobe, and the angle formed by the superior border of the zygoma, is generally about $1\frac{2}{5}$ of an inch.

The inferior external limit of the parietal lobe corresponds very nearly to the line which unites the superior part of the parieto-temporal suture with the summit of the lambdoidal. The inferior border of the occipital lobe corresponds to the line uniting the external angle of the occipital with the occipital protuberance.

Below this line is the cerebellum. The anterior border of the temporal lobe is situated about $\frac{4}{5}$ of an inch external to the outer margin of the orbit. The inferior border of the temporal lobe at the spot where it is continuous with its anterior is distant from the zygomatic arch about half-an-inch, nearer the articulation of the lower jaw it is about $\frac{1}{5}$ of an inch distant from it.*

The arrangement of the various *sutures* of the bones forming the vault of the cranium has greater interest for

* Broca: "Sur la Topographie Cranio-Cérébrale," etc.

the obstetrician than for the surgeon, as any peculiarities connected therewith exist normally only in foetal life or in early childhood. The bones of the skull in the foetus or newly-born child are flexible, and between their undeveloped sutures are the *fontanelles*, the positions of which are of importance. At birth only the large quadrilateral frontal fontanelle exists. It is rhomboidal in shape, with irregular sides, of unequal length, and bent inwards. The two anterior borders are the longer, and the angle between them is more acute than between the posterior; consequently the position of the child's head (the *presentation*) can be readily made out during parturition. The triangular fontanelle is not open in the child at full term, nor the lateral fontanelle, which is of no practical importance. They are generally completely ossified at the fourth year.

Fracture by *contre-coup* is denied by some, on the ground that the shock is resisted by the cranium, and that the results of such shocks, as in the case of architectural arches, are lost upon its supporting pillars, which, in the frontal region, are represented by the malar and sphenoid bones, in the parietal by the temporal bones, and in the occipital region by the ribs of the occipital bone itself. Rupture of the brain substance, however, is common by *contre-coup*.

In almost all cases, when the parietal region is the seat of the injury, the bone is fractured at the spot, and the line of fracture runs through the temporal bone, which, from the fact of its containing so many cavities and foramina, its texture, and the inclination of the axis of the petrous portion, readily gives way.

A fracture of the base may also occur from a fall on the feet or on the buttock, the force being transmitted along the spinal column, and meeting the skull at the condyles. The course of such fractures of the base may be anatomically determined by the effects produced upon the nerves issuing from the skull, the

most frequent being facial paralysis from lesion of the portio dura whilst in the aqueductus Fallopii.

Fractures of the base of the cranium are generally associated with ecchymosis of the eyelids and effusion of blood and cerebro-spinal fluid from the external auditory meatus. Although ecchymosis of the eyelids has been described as of great symptomatic value in such cases, it has also been shown that the orbital effusion is preceded by ecchymosis of the ocular conjunctiva. When in fact in a fracture of the cranium the effusion of blood produced by the rupture of the blood-vessels of the diploë reaches the roof of the orbit, it rapidly infiltrates the cellular tissue of this cavity, and passing through the perforations in the capsule of Tenon, invades the sub-conjunctival cellular tissue. Orbital ecchymosis by infiltration of blood after contusion of the eyelids is not produced in the same manner (*vide* "Orbit").

The surgical anatomy of the *temporal* bone presents considerable additional points of practical importance, as it contains the organ of hearing and the parts accessory to it.

The *external auditory canal* has a direction inwards and forwards, describing a slight general curve, the concavity of which is downwards. The outer third of the passage is formed by a tubular prolongation inwards of the cartilage of the external ear, which, however, is not complete at the upper part; and its inner two-thirds by the canal in the temporal bone. There are several small fissures in the cartilaginous part, which are sometimes very wide — a circumstance explaining the passage of pus *into* the meatus, from abscesses which have formed *without* to it. In length the meatus is about an inch and two or three lines; but owing to the obliquity of the attachment of the membrana tympani, its anterior wall is about one-quarter of an inch longer than the posterior. Its narrowest diameter is about the middle, and in making an examination with the speculum auris the instrument should not

be introduced further than this point. It must be borne in mind that in young children the meatus is very shallow, the bony part consisting only of a small ring of bone, deficient at the upper part, to which the *membrana tympani* is attached.

To facilitate the introduction of the speculum, the

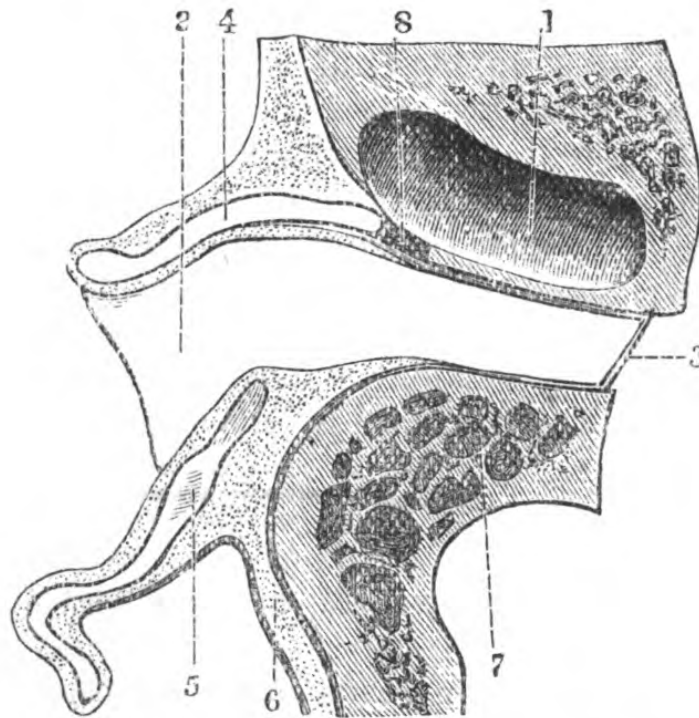


Fig. 3.—Horizontal Section of the left External Auditory Canal.
(Actual size.)

1, glenoid cavity of temporal bone; 2, external auditory meatus; 3, *membrana tympani*; 4, 5, cartilaginous portion of external auditory meatus; 6, periosteum of mastoid bone continuous with that of the auditory canal; 7, mastoid cells; 8, fibrous tissue, which unites the cartilaginous with the osseous tissue of the canal.

auricle should be drawn upwards, backwards, and a little outwards; this renders the canal tolerably straight.

The *membrana tympani* is, on examination, greyish in colour, its fibrous structure looking radiated, slightly conical, with the apex directed inwards, and placed very obliquely at the bottom of the meatus. The handle of the malleus is seen through the membrane, not quite

vertical, but inclining a little backwards. The points of practical importance connected with the *tympanum* are these—that its upper aspect and floor are formed by thin lamellæ of bone separating it from the cranium and from the canal for the internal carotid artery, so that disease of the bone may cause death, either by involving the dura mater and brain, or from ulceration into the vessel. The close vicinity of the carotid artery and lateral sinus readily accounts for the escape of blood from the ear in fracture of the base of the cranium.

The *Eustachian tube* is the means of communication between the internal ear and the pharynx, and serves to maintain the balance of air on either side of the *membrana tympani*.

Its internal orifice is at the anterior internal aspect of the tympanum. The tube is directed downwards and forwards, and terminates in a flattened valve-like opening in the pharynx, just behind and a little above and external to the inferior meatus of the nose. Its mucous membrane is continuous with that of the pharynx. The pharyngeal extremity of the tube is in close relation with the tonsil—a fact which explains its temporary occlusion in enlargement or inflammation of that gland (*vide* “Pharynx”).

(The operation of introducing the Eustachian catheter is explained at p. 41).

SURGICAL ANATOMY OF THE FACE.

The region of the face is naturally very complicated, but it will be found that its subdivisions may be conveniently referred to its skeleton; and after describing the surgical anatomy of the integuments of the face, it will be advisable to examine its several subdivisions, as follows:—The region of the orbit, the nose, the mouth, the pterygo-maxillary, and the parotid regions.

Topography.—The skin of the face is remarkably thin, freely supplied with vessels, nerves, and lymphatics.

The subcutaneous cellular tissue is dense, and contains (except on the eyelids) a good deal of fat.

Blood-vessels.—The arteries of the face may be regarded as forming two overlying networks, one a superficial and distributed essentially to the integument, and the other a deep. The several vessels entering into its formation will be considered with the special regions to which they respectively belong.

The superficial supply of the face is derived from the external carotid, by the facial, and from the ophthalmic branches of the internal carotid. The deep is formed by the lingual, pharyngeal, internal maxillary, and ophthalmic. Their inosculation with the superficial set is remarkably free, and forms an intermediate means of communication with the intra-cranial arteries, through the middle and lesser meningeal and the ophthalmic.

The normal course of the facial artery, when it appears on the face, is just anterior to the masseter muscle, where it is subcutaneous, and here only is it in actual relation with the accompanying facial vein, which is almost straight, and lies to its outer side. The vessel ascends from this point tortuously, particularly so in old persons, towards the corner of the mouth, side of the nose, and inner angle of orbit, where it inosculates with the ophthalmic. The artery lies at first under the platysma, and further on in its course is covered by some thin fibres of the zygomaticus major. The chief named branches are the inferior labial, running between the lower lip and the chin, and distributed to its integument; the coronary, superior and inferior, distributed to each lip and to the septum of the nose; the lateral nasal, to the side of the nose; and the angular, a large branch going to the inner angle of the orbit, generally seen pulsating under the skin. The transverse facial artery is a branch generally of the temporal, lying by the side of the duct of the parotid gland (Steno's), accompanied by branches of the facial nerve.

Those branches which the internal carotid supplies to the face are the terminal ones of the ophthalmic—namely, the supra-orbital and supra-trochlear which escape by the supra-orbital and supra-trochlear notches. The inosculating vessels escape through several foramina in the bones of the face, from deep branches of the external carotid—viz., the infra-orbital, passing out of the infra-orbital foramen; from the mental foramen, and a large branch from the same source is found on the substance of the buccinator. The free inosculation of the arteries of the face renders ligature of both ends of a divided facial artery necessary, as the return circulation is quickly established; and, in wounds, whether the results of accident or surgical interference, very accurate approximation of the edges must be obtained, for union takes place very rapidly, and distortion is not so easily remedied. The *veins* of the face are arranged like the arteries, in two networks, and freely anastomose with each other and the opposite side, and with the intra-cranial system. The angular veins freely inosculate with the ophthalmic. The veins which accompany the internal maxillary (*vide* “Internal Maxillary Region”), form a remarkable plexus, and being intimately associated with the aponeuroses of the region, remain open when cut. The blood-vessels of the face are frequently subject to a nævoid condition.

The *nerves* of the face are derived from the three divisions of the 5th, and from the portio dura or facial part of the 7th cerebral nerve. The branches from the 1st division of the 5th are—the supra-orbital, supra-trochlear, infra-trochlear, lachrymal, and nasal. From the 2nd—the infra-orbital, passing out of the infra-orbital foramen, and the subcutaneous malæ. The buccal from the same source emerges just in front of the anterior border of the masseter. From the 3rd division—the masseteric, and the inferior dental from the foramen mentale. Physiological experiments have determined that the 5th, by its ophthalmic and superior maxillary branches, is exclusively sensory, whilst by

its inferior maxillary branch it is both sensory and motor, and that the sensory fibres of the nerve preside over the secretion and nutrition. It is, moreover, associated with the pharyngeal plexus in the sense of taste, and all its branches are endued with acute sensitiveness.

The facial forms a plexus in the parotid gland, after which it passes into a great many branches, and is supplied to the muscles of the face, having free inosculations with the branches of the 5th nerve. The facial nerve is itself insensitive, and does not convey any sensitive impression to the cerebrum; it is a motor nerve, and by virtue of its motor function it exercises a certain influence upon the organs of sense, and accessorially on the secretions, on the temperature, circulation, and nutrition of the face.

The *lymphatic glands* of the face are most thickly situated along the base of the jaw, upon it and the buccinator muscle, others under the zygoma, and beneath, in, or upon the parotid gland; those around the mouth are sometimes affected with syphilitic induration after the application of the specific virus to the lips.

The cellular tissue being very lax, and loosely attached to the subjacent structures, it is liable to infiltration by fluids, or air, as in wounds of the frontal sinuses or larynx. As the fasciæ of the face are very thin and ill defined, abscesses in this region point early.

The congenital malformations consist of closure of its apertures, arrests of development, such as single and double hare-lip, frequently associated with cleft-palate.

Some portions of the parotid gland (anterior portion and socia parotidis) are of importance in the consideration of the integuments of the face, inasmuch as they are subcutaneous, and would be implicated in the removal of growths, abscesses, and in operations for salivary fistulæ. The facial portion of the gland is situated just in front of and below the ear, the deeper

portion lying behind the angle of the jaw, limited above by the zygoma (*vide* "Parotid Region"). It overlaps the masseter to a variable extent. Its *duct* runs forward to the anterior edge of the masseter, and dips inward to open obliquely through the cheek, opposite the second molar tooth of the upper jaw. The *course of Steno's duct* is defined by a line extending from the upper border of the lobule of the ear to midway between the nostril and the angle of the mouth; and great care must be taken in operations on the face to avoid its division, as a salivary fistula would be the result.

SURGICAL ANATOMY OF THE REGION OF THE ORBIT.*

The region of the orbit may be conveniently described as consisting of an external and an internal. The external comprises the superciliary, palpebral, and lachrymal apparatus; and the internal the muscles, vessels, and nerves of the orbit, and the globe of the eye.

Topography.—The superciliary region, consisting exclusively of the eyebrow, and presenting for examination the skin, which is covered with hair, its deep surface being attached to the corrugator supercillii. The incision for an operation, such as removal of a cyst, should be made parallel to its general direction, after shaving the eyebrow. The subcutaneous cellulo-fatty layer is dense and adherent. The muscular layer consists of the orbicularis frontalis and corrugator supercillii, very thick, the submuscular cellular tissue, which is continuous with that of the occipito-frontalis, and the periosteum, which is continuous with that of the orbit. The bony plan is the frontal bone.

* The minute anatomy of the eye has been omitted, and such portions only described as are associated with the more ordinary operations.

The small dermoid cysts met with at the external angle of the brow are the results of the imperfect closure of the first branchial arch; they are always congenital and always adherent to the bone.

The palpebral region.—This region is formed exclusively by the eyelids.

In the following description of the orbital region, those parts only which are the seat of the ordinary surgical operations are treated of. An account of those parts which are contained within the globe, and of the operative proceedings connected with them is necessarily very short, and the student is referred to works on descriptive anatomy or ophthalmic surgery, as the limits of the present volume scarcely admit of so special a subject.

THE EXTERNAL ORBITAL REGION, SUPERCILIARY AND PALPEBRAL.

The eyelids consist of the following layers:—The skin, which is remarkably thin, and presents transverse folds which are formed by the movements of the lids. Incisions into the lids should always be made parallel to these folds. Next in order is the subcutaneous cellular tissue, very loose, and destitute of fat, continuous with that of the forehead, and very liable to infiltration of blood if the effusion takes place beneath the tendon of the occipito-frontalis muscle, the insertion of the tendon of which (*tendo oculi*), is of some surgical importance. It passes in front of the middle lachrymal sac, tying it down in its place, whilst a second lamina passes behind it. Its position is readily shown by placing the fingers on the upper and lower lids and gently drawing them outwards; it thus forms a guide to the lachrymal sac.

Beneath the muscular layer is some very lax cellular tissue, which is readily infiltrated by serum, blood, or air, producing ecchymosis or emphysema. Next

in order is a fibro-cartilaginous layer, formed by the tarsal cartilage and tarsal ligament, which attaches the cartilage to the margin of the orbit. The Meibomian follicles lie in the posterior aspect of these cartilages. The tarsal ligament generally prevents ecchymosis, dependent on fracture at the base, becoming subcutaneous. The tarsal cartilage of the upper lid is strengthened by the insertion into it of the levator palpebræ.

The next layer is formed of cellular tissue and fat, particularly developed at the orbital border of the lids, where it is continuous with that of the orbit. The most internal layer is the conjunctiva.

The *palpebral conjunctiva*.—The conjunctiva is the mucous layer of the eyelids; it is intimately adherent with the posterior aspect of the tarsal cartilages. It is continuous with the skin at the free border of the lids, and at about the junction of the inferior three-fourths of the tarsal cartilage with the upper. It is deflected on the sclerotic, forming above the superior oculo-palpebral cul-de-sac and below the inferior, which is shallower than the superior. The spaces above and below the cul-de-sac are filled with lax cellular tissue, into which the blood finds its way after flowing into the orbit. Should this effusion appear some while after an injury to the head, it indicates the existence of a lesion more or less distant from the point of its appearance, and which is generally a fracture of the base of the skull passing through the body of the sphenoid bone. This is a point of the greatest importance in diagnosis after injury to the head.

The arteries consist of the palpebral branches of the ophthalmic which anastomose with the facial, temporal, infra-orbital, supra-orbital, and lachrymal. The veins, as a rule, accompany the arteries. The nerves are derived from the facial, the superior maxillary of the fifth and the third, which supplies also the levator palpebræ.

The *ocular conjunctiva* after its reflection over the

eyeball, becomes transparent, and its blood-vessels are invisible, unless conjunctivitis is present. These vessels are arranged as a network over the entire surface of the globe, and can be caused to slide over the subjacent cornea or sclerotic, owing to the cellular membrane existing between them. It will be observed, in the inflammatory condition, that the direction of the blood-vessels of the sclerotic is arranged radially, and they are pinkish in colour, owing to their lying in its dense substance, whereas the conjunctival vessels are scarlet. The recto-tendons are separated from the ocular conjunctiva by a layer of connective tissue, and the ocular prolongation of the capsule of Tenon.

The free border of the lids presents the orifices of the Meibomian and ciliary follicles, and their outer margin the cilia. The Meibomian glands are about thirty or forty in number, having corresponding ducts, on either side of which open a number of small cul-de-sacs. The office of their secretion is to prevent adhesion of the eyelids; the ciliary follicles are subject to dilatation and suppuration, forming *stye*. The commissures of the eyelids differ in form, the conjunctiva forming a small cul-de-sac externally, whilst internally is found the caruncula, having to its outer side the plica semilunaris.

LACHRYMAL APPARATUS.

The lachrymal apparatus—including the lachrymal gland, the lachrymal ducts, the conjunctival surface of the eyeball, the puncta lachrymalia, the canaliculi, the lachrymal sac and its duct (nasal duct)—is situated partially within the orbital cavity, partially in the eyelids, the inner canthus, and partially in the nose.

The lachrymal gland lies in a depression situated at the external and superior aspect of the orbital fossa. It is enclosed in a fibrous capsule, which is derived from the periosteum of the orbit, and generally consists of two portions—an orbital, the larger, and an anterior or palpebral; the outer margin of the aponeurosis of

the levator palpebræ muscle forming a partial separation of these two portions. *Its relations* are as follows:—*Superiorly*, the periosteum of the orbit; *inferiorly*, the eyeball, and superior and external recti muscles; *anteriorly*, it is closely adherent to the posterior

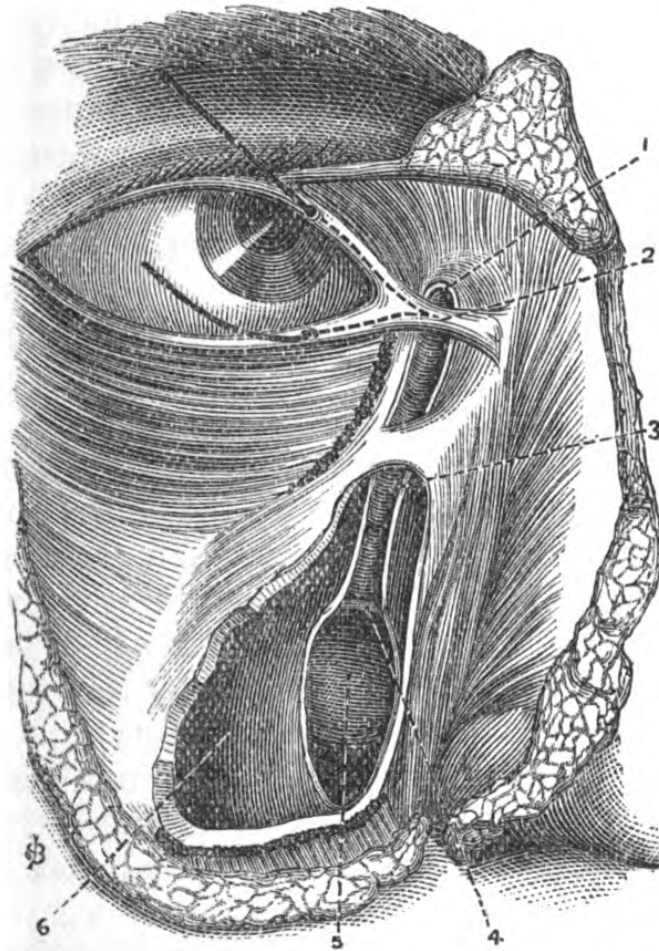


Fig. 4.—Lachrymal Apparatus and Nasal Duct.

1, lachrymal sac; 2, tendo-oculi; 3, valvular folds in nasal duct; 4, orifice of nasal duct; 5, lower turbinated bone; 6, inner wall of antrum. (Bristles are introduced into the puncta lachrymalia.)

aspect of the upper lid and conjunctiva. *Within* it, is the lachrymal branch of the ophthalmic artery, inosculating with the orbital branch of the internal maxillary, with their accompanying veins; the lachrymal branch of the ophthalmic division of the fifth nerve, which inosculates with the orbital branch of the supe-

rior maxillary division of the fifth. These structures enter at its posterior and external margin. The *ducts* of the lachrymal gland, which are about ten in number, are so arranged that they open in a row in the superior external conjunctival cul-de-sac.

The lachrymal canals commence at the *puncta lachrymalia*, which are seen, on everting the lids, as the centres of small eminences, situated about a quarter of an inch from the inner angle, on the inner aspect of the margin of the lid. These minute openings are kept in contact with the conjunctival surface of the globe by the action of the tensor tarsi, so that they always lie in the current of the tears. In each canaliculus, immediately below the punctum, is a small cul-de-sac, beyond which, after enclosing the caruncula, the canals join previous to entering the lachrymal sac. Their posterior portion is subconjunctival, a circumstance of considerable practical value in the operation of reinstating the course of the tears when from any cause the orifices of the puncta do not perform their function of receiving the tears. That portion which is common to both canaliculi is bound down by the tendo-oculi. The process by which the continuous flow of tears between the lachrymal gland and the nose is kept up, is not entirely clear; it is very probably in a great measure owing to suction caused by exhaustion in the nasal duct.

The lachrymal sac is the superior dilated extremity of the nasal duct (*vide* "Nasal Region"), and consists of fibro-elastic tissue, lined with epithelium, continuous through the puncta with the conjunctiva, and by means of the nasal duct, with the mucous membrane of the nose. It is situated at the internal angle of the eye, and is lodged in a hollow formed by the os unguis and the nasal process of the superior maxillary. It is *covered* in by the skin, subcutaneous cellular tissue, tendon of orbicularis muscle, and the internal portion of the palpebral aponeurosis. The exact situation of the sac can be felt with the finger, and the best land-

mark is the anterior lip of the lachrymal groove, surmounted by a small tubercle of bone, formed by the external border of the nasal process of the superior maxilla, or if both the lids be abducted from the mesial line, tension is made on the tendo-oculi, which

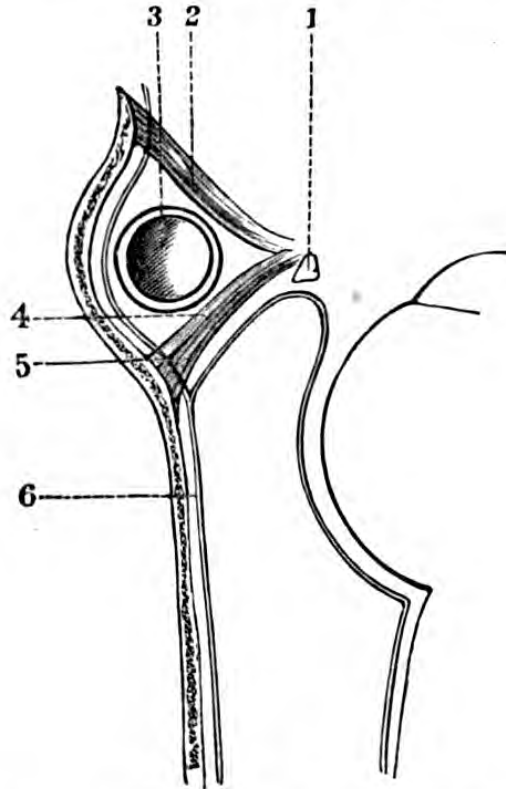


Fig. 5.—Diagram of the Relations of the Lachrymal Sac, by a horizontal section taken at the level of the inner angle of the eye.

1, caruncle; 2, direct tendon of orbicularis muscle; 3, lachrymal sac; 4, reflected tendon of orbicularis muscle; 5, Horner's muscle; 6, periosteum lining the wall of the orbit and the lachrymal canal.

will show itself as a flat cord immediately over the sac bisecting it.

To introduce a probe into the nasal duct by the punctum lachrymale.—It is frequently necessary to pass a probe into the nasal canal through the punctum; the lower lid is to be everted, when the punctum will be seen about two lines from the inner angle on a small papilla. The probe is first to be introduced vertically, and pushed downwards for a short distance, when the

hand is to be depressed, and the probe pushed inwards until arrested by the os unguis, then raised again vertically; when the slightest pressure will cause it to traverse the lachrymal sac and enter the nasal canal, pushing it downwards, backwards, and inwards.

When suppuration takes place in the lachrymal sac, and ulceration through the integument follows, *lachrymal fistula* is the result.

The tears may be prevented passing into the puncta, owing to these being obstructed, or to eversion of the lid from some cause, such as ectropion, as a result of a burn or other injury, or cicatrization after syphilitic ulceration, or paralysis of Horner's muscle.

INTERNAL ORBITAL REGION.

Boundaries.—The bony walls of the orbit are formed as follows:—

The roof, very thin except at the base, concave, directed downwards and forwards, by the orbital plate of the frontal bone in front, and by the lesser wing of the sphenoid behind; externally is the depression for the lachrymal gland. *The floor*, very thin, nearly flat, by the malar, superior maxillary, and orbital plate of palate. *Outer wall*, concave by the greater wing of sphenoid and malar bone. *Inner wall*, flat, by the lachrymal, os planum of ethmoid, and sphenoid. Regarding the shape of the orbit as nearly conical, its base is nearly quadrilateral, and at its several angles are found the sutures of its component bones. At its external, that of the external orbital process of the frontal with the malar; at its internal, that of the frontal with the lachrymal and nasal process of superior maxilla; below, that of the malar with the superior maxilla.

Its apex corresponds to the optic foramen and sphenoidal fissure.

The speno-maxillary fissure is found on the floor of the orbit. The continuity of this fissure with the

spheno-maxillary fossa explains the protrusion of the eyeball from processes of tumours passing through it from the spheno-maxillary region.

CONTENTS OF THE ORBITAL CAVITY.

The soft parts of the orbit are contained within two distinct compartments, separated from one another by

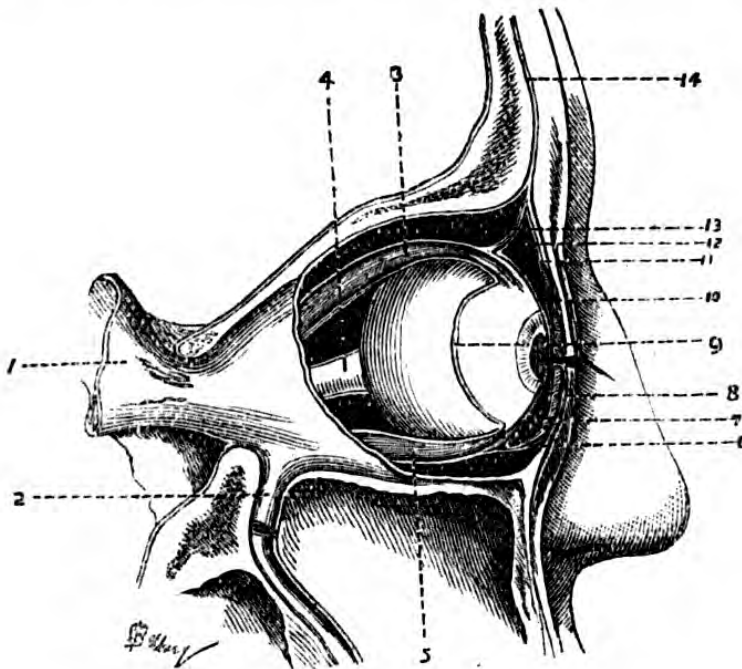


Fig. 6.—Aponeuroses of Orbit.

1, dura mater; 2, prolongation of dura mater into the posterior palatine canal; 3, superior rectus enclosed in its sheath; 4, optic nerve; 5, inferior rectus in its sheath; 6, process of aponeurosis of inferior oblique attached to the palpebral aponeurosis; 7, inferior oculo-palpebral cul-de-sac; 8, inferior tarsal cartilage; 9, ocular portion of orbito-ocular aponeurosis; 10, superior tarsal cartilage; 11, palpebral aponeurosis; 12, superior oculo-palpebral cul-de-sac; 13, process of aponeurosis of superior oblique attached to the palpebral aponeurosis; 14, periosteum of frontal bone continuous with that of the orbit.

the *orbital aponeurosis*, or capsule of Tenon. The anterior of these compartments contains the eyeball, and the insertions of the muscles of the globe, the posterior the muscles themselves, the vessels and nerves, and the fat and cellular tissue of the orbit.

The dura mater enters the cavity by the optic foramen and anterior lacerated fissure forming the periosteum. At the margin of the orbit it splits into two layers, one continuous with the pericranium at the upper margin of the circumference, or with the periosteum of the face at the lower, and the other which forms the capsule of Tenon. The vertical portions of this orbital aponeurosis form the superior and inferior oculo-palpebral cul-de-sac, and the lateral strengthen the palpebral ligaments. It is then reflected over the posterior portion of the globe, enclosing the optic nerve, and furnishes sheaths for the muscles. This aponeurosis is pierced by the vessels and nerves which pass from the posterior to the anterior compartment. A knowledge of the arrangement of these aponeurotic expansions and of their situations is of some considerable importance in the diagnosis of intra-orbital injury or disease, as by their attachment and situation they facilitate or impede the course taken by blood or pus. Ecchymosis beneath the conjunctiva is an important symptom of fracture of the roof of the orbit after injury of the head. *The muscles* which act upon the globe are six in number—namely, the four recti and two obliqui, and one muscle acting upon the upper lid, the levator palpebræ. At their insertion their tendons become expanded upon and continuous with the sclerotic. The complete division of the aponeurotic sheaths as well as of the tendons is necessary in the operation for strabismus, as these investments, if left undivided, still exert considerable power over the globe, owing to their completely enclosing both muscle and tendon. The recti tendons are inserted into the sclerotic about a quarter of an inch behind the cornea.

The eyeball and its vessels and nerves lie in a mass of fat and cellular tissue, which serves as a cushion for the optic nerve and for the globe in its various movements, and as a support for its accessory structures. This cellulo-fatty mass is continuous with the

cranial cellular tissue, and with that of the zygomatic and speno-maxillary fossæ.

The arteries are derived from the ophthalmic branch of the internal carotid, which enters the optic foramen below the nerve, and forms free anastomoses with the temporal, facial, and internal maxillary.

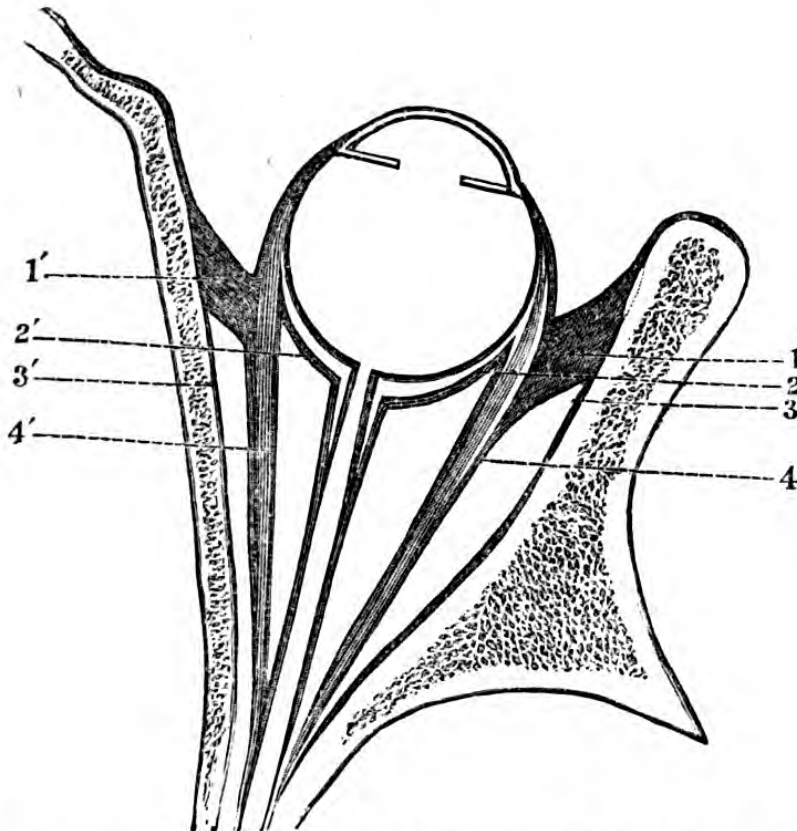


Fig. 7.—Diagram of a horizontal section of the Orbit, showing the lateral prolongations of the Orbital Aponeurosis.

1, internal prolongation; 2', external prolongation; 2-2', ocular lamina of the orbital aponeurosis; 3-3', orbital periosteum; 4-4', lateral recti-muscles.

The veins generally accompany the arteries, and terminate in a large vein, the ophthalmic, unprovided with valves, which, after being formed both without and within the orbit, passes as a trunk between the two heads of the external rectus muscle, and enlarges into the cavernous sinus.

The nerves are—the optic, the third, the fourth, the ophthalmic division of the fifth and the sixth, with

their branches, and from the lenticular ganglion are given off the ciliary (short).

Paralysis of the third nerve or motor-oculi causes *ptosis*, or a dropping of the upper lid, external strabismus, dilatation, and immobility of the pupil. Paralysis of the fourth nerve, or patheticus, causes impossibility of rotation of the eyeball, and diplopia; paralysis of the ophthalmic branch of the fifth nerve produces alternately sloughing of the cornea; in paralysis of the sixth, or abducens, the eyeball is turned inwards, and in paralysis of the seventh, or facial nerve, there is impossibility of closure of the eyelid and epiphora.

Relations of parts within the orbit.—A good idea of the actual relations of the contents of the orbital cavity looked upon as a cone may be obtained by regarding the eyeball and optic nerve as occupying very nearly its axis, and the muscles, vessels, and nerves as placed superiorly, inferiorly, externally, and internally to them.

The *relations* of the globe and optic nerve to the orbital cavity, and considered as occupying its axis, are as follows:—

Superiorly, from above downwards (omitting the dura mater):—(1) The frontal vessels and nerves, and behind in the same plane the fourth nerve; (2) the levator palpebræ muscle; (3) the rectus superior; (4) the superior set of the muscular branches of the ophthalmic artery, and the superior division of the third nerve; (5) the nasal nerve and ophthalmic artery, and the ciliary vessels and nerves.

Inferiorly, from below upwards:—(1) The inferior rectus and the inferior oblique muscles; (2) the inferior division of the third nerve, and its branch to the lenticular ganglion; (3) the inferior set of muscular vessels.

Internally, from within outwards. (1) The superior oblique and internal rectus muscles. (2) The termination of the fourth nerve, the nasal nerve, the

ophthalmic artery and vein, and the anterior ethmoidal artery.

Externally, from without inwards:—(1) The lachrymal vessels and nerve, and the lachrymal gland. (2) The external rectus muscle, between the two heads of which pass, both divisions of the third nerve, the nasal of the fifth, the sixth nerve, and the ophthalmic vein. (3) The nasal nerve, lenticular ganglion, and ophthalmic artery.

A needle passing through the axis of the eyeball from its anterior surface backwards would traverse successively—(1) the ocular conjunctiva; (2) the four layers of the cornea—viz., anterior elastic lamina, the cornea proper, the posterior elastic lamina, the posterior epithelium; (3) the anterior chamber; (4) the pupil; (5) the anterior layer of the capsule of the lens; (6) the lens; (7) the posterior layer of the capsule of the lens; (8) the anterior portion of the hyaline membrane; (9) the vitreous humour; (10) the posterior portion of the hyaline membrane; (11) the three layers of the retina—viz. (α), Jacob's membrane (rods and cones); (β) the granular layer; (γ) the fibrous layer; (12) the choroid; (13) the sclerotic.

The structures divided in the operation of extirpation of the globe are—the conjunctiva, the sub-conjunctival tissue, the tendons of the recti and obliqui with their aponeurotic sheaths, the optic nerve, and the long and short ciliary vessels and nerves.

The structures divided in the operation for strabismus are the conjunctiva, sub-conjunctival tissue, and rectus tendon with its aponeurotic sheath.

SURGICAL ANATOMY OF THE NASAL REGION.

The structure of the skin of the nose is similar to that in other parts of the body, except that it is very thin and loosely connected with the subjacent parts. The hairs are but rudimentary, and the sebaceous glands very numerous and largely developed. These

orifices show themselves as points more or less deep, most abundant on the alæ. Underneath is a layer of cellular tissue very adherent to the skin and subjacent musculo-fibrous tissues which contain a little fat.

The *muscles* of the nose belong to those of expression, and are as follows:—pyramidalis nasi, levator labii superioris et alæ nasi, dilator naris, compressor nasi, compressor narium minor, depressor alæ nasi.

The *arteries* of the nose are derived from the ophthalmic and the facial, the sides and dorsum being supplied by the nasal branch of the ophthalmic and the infra-orbital, the alæ and septum by the superior coronary, and by the lateralis nasi.

The *veins* terminate in the facial and ophthalmic.

The *nerves* are derived from the facial, infra-orbital, infra-trochlear, and a twig from the nasal branch of the ophthalmic of the fifth.

There are numerous *lymphatics*, which empty themselves into the submaxillary glands (lymphatic), and follow the course of the facial vein.

The mucous membrane lining the nostrils is continuous with the skin and that of the nasal fossæ (*vide* "Nasal Fossæ").

The nasal cartilages, forming the softer portion of its framework, are five in number—viz., two upper lateral, two lower lateral, and the cartilage of the septum.

Each upper lateral cartilage [is flattened and triangular in shape. Its anterior margin articulates with the cartilage of the septum. The posterior edge articulates with the nasal process of the superior maxillary and nasal bones. The lower edge is connected by fibrous tissue with the lower lateral cartilage.

The alar or lower lateral cartilages are two in number, and completely separate. They are of the form of a horseshoe, with the concavity posterior, and with the external limb longer than the internal. The convexity of these two cartilages is situated in the thickness of the lobe, on each side of the anterior inferior angle of

the cartilage of the septum. The inner limb of this cartilage has its back against that of the opposite side and to the cartilage of the septum in the median line.

There are three or four small cartilaginous plates, situated in the tough membrane connecting the lower lateral (alar) cartilage with the nasal process of the superior maxilla—the *sesamoid*.

The ala of each side is further composed of masses of cellular tissue placed below and behind the alar cartilages.

The bony framework is formed by the nasal bones, to which the external nose owes its form in a great measure; their method of articulation with the frontal and superior maxillary greatly determining its shape and dimensions.

These two oblong bones form, by their junction along the middle line in front, the "bridge" of the nose; they articulate with the *frontal* and *ethmoid*, with the *superior maxilla* and with *each other*.

The great vascularity of the nose and of the adjacent parts renders union after wounds very rapid; indeed, there are cases where the entire organ has been cut off, and been for some little while removed from the body, reuniting entirely after careful adjustment. Plastic operations for the restoration of the nose depend greatly for their success on the surgeon's ingenuity, and also on so fashioning the flaps that they retain the vessels in their continuity, thus providing for their thorough nourishment.

SURGICAL ANATOMY OF THE NASAL FOSSÆ AND SINUSES OF THE NOSE.

The *nasal fossæ* consist of two irregular cavities, for the sense of smell, and also to allow of the passage of air to or from the lung. They communicate with the exterior by means of the nostrils, and with the breathing apparatus by means of the pharynx.

The *nostrils* open at right angles to the anterior apertures or nares, and as will be seen from this sketch, the inferior margin of the anterior nares is situated in a lower plane than that of the nostril. The nostril is included in the alar cartilages, having a slight dilatation

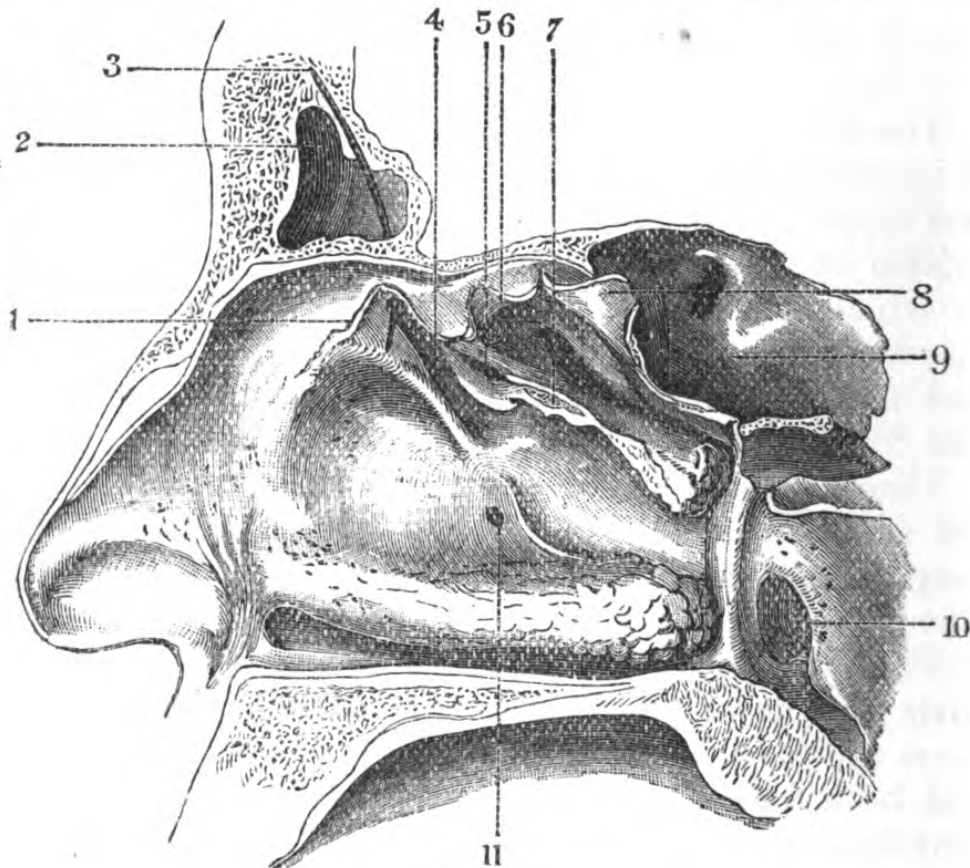


Fig. 8.

1, edge of middle turbinate bone; 2, frontal sinus; 3, sound passed into middle meatus; 4, sinus maxillaries; 5, opening of lower ethmoidal cells; 6 and 8, superior turbinate bone, split and separated; 7, cut edge of middle ditto; 9, sphenoidal sinus; 10, Eustachian tube; 11, occasional opening of sinus maxillaries.

externally and superiorly. The skin is very sensitive, and furnished with strong coarse hairs called *vibrissæ*.

In order to obtain a good idea of the form of the nasal fossæ, vertical and transverse sections should be made, which will not only show the form of these cavities themselves, but also their relations with neighbouring ones.

Each nasal fossa presents for examination a *roof*, *floor*, *internal wall*, *external wall*, *anterior* and *posterior nares* and *mucous membrane*. The vertical diameter of each nasal fossa is greater at the middle of the cavity than at the anterior or posterior parts, and the transverse diameter greater below than above.

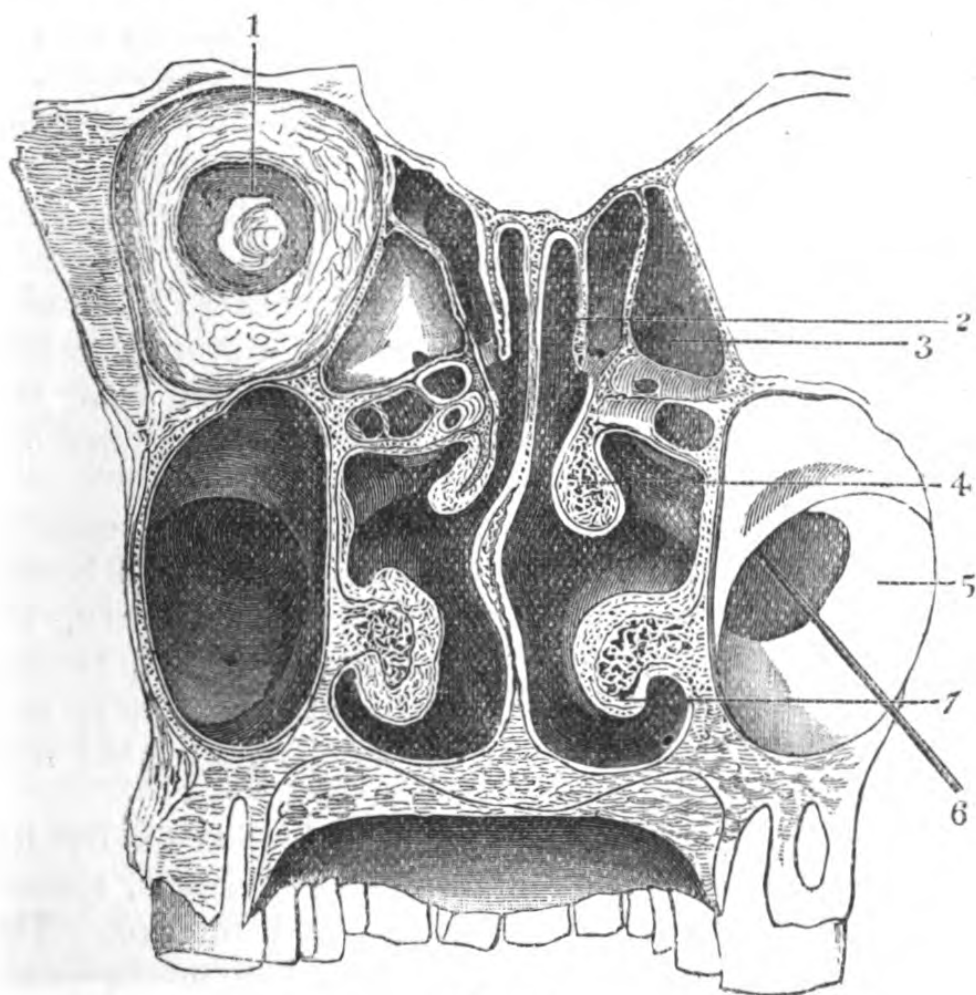


Fig. 9.

1, section of orbit ; 2, superior turbinate bone ; 3, ethmoidal cells ; 4, middle turbinate bone ; 5, antrum ; 6, sound passing into middle meatus ; 7, inferior turbinate bone.

The roof is formed by the nasal bones, the nasal spine of the frontal, the cribriform plate of the ethmoid, and the body of the sphenoid. It is to be noted that the entire roof is *not* horizontal, the cribriform plate only being so, and that it slopes downwards and

forwards, whilst the sphenoidal portion is in front of the body vertical, and below it horizontal.

The floor is formed by the palate plates of the superior maxillary and palate bones. It is not so long as the superior, it is the widest portion of the fossa, and is concave transversely, and is inclined slightly downwards.

The internal wall or septum is formed chiefly by the perpendicular plate of the ethmoid and by the vomer; the septal plane is further assisted by the nasal spine of the frontal, the crests of the nasal, superior maxillary, and palate bones. (The septum is rendered complete by the triangular cartilage, which projects forwards, assisting in giving shape and prominence to the nose) It must be borne in mind that this septum is rarely vertical, occasionally it deviates so much from the middle line that inflammation or abscess of its mucous membrane may be mistaken for polypus.

The outer wall is divided into the three meatuses by the projection from it of the three turbinated bones. It is formed by the nasal, the superior maxillary, the lateral mass of the ethmoid, and the lachrymal bones; posteriorly by the ascending plate of the palate, and the internal pterygoid plate of the sphenoid; the wall is completed by the lateral cartilages.

Meatuses.—The outer wall of each fossa is subdivided into three (sometimes four) irregular channels, termed meatuses—viz., superior, middle, and inferior. The bones entering into the formation of these meatuses are all those of the face, excepting the malar and inferior maxilla.

They are divided by the three turbinated bones.

The superior meatus lies beneath the superior spongy bone, and is the smallest, and has opening into it the posterior, ethmoidal, and sphenoidal cells. At the back is the speno-palatine foramen, communicating with the speno-maxillary fossa.

The middle meatus lies beneath the middle spongy bone, and has opening into it in front, the frontal sinus

(infundibulum), the anterior ethmoidal cells, and the opening of the antrum, which is almost impossible to find on the living body (*vide* "Superior Maxillary Region").

The inferior meatus, the largest and most important, lies beneath the inferior spongy bone; which extends almost the whole length of the fossa; its lower border, thick and rounded, descends almost to the floor, sometimes converting the meatus into a canal; anteriorly, where it joins the nasal process of the superior maxilla is the orifice of the nasal duct.

The opening into it is the *nasal duct*. This canal extends from the orifice in the meatus to the lachrymal sac, and its orifice is situated about half-an-inch behind the ascending plate of the superior maxilla, and nearly opposite the centre of the under surface of the lower turbinated bone. It is somewhat valvular, owing to the folds of mucous membrane which pass into the aperture, and which are continued up the tube. It takes a direction from *below, outwards, forwards, and upwards* (*vide* p. 23.)

To pass a probe into the nasal duct, the instrument should be first bent into the shape of an italic *f*, which should be passed first along the floor of the fossa, with its concavity towards the entrance; the point is next to be pushed gently beyond the ascending plate of the superior maxilla, and kept in close contact with the outer wall; then it is to be slightly rotated between the fingers, until the point presents upwards and outwards towards the eye; if the handle be now depressed, it should enter the canal.

ORIFICES OF THE NASAL FOSSÆ.

The anterior nares.—The nasal fossæ present for examination four apertures—two anterior and two posterior. The form of the *anterior nares* is somewhat like the heart of a playing card, inverted, separated by a septum,

and, as before noticed, the base is at a lower level than the plane of the nostril; hence, for making an examination, the lobe of the nose must be raised as much as possible. To obtain a complete view of the nasal cavities, it is necessary to detach the integuments from the margins of the anterior nares from within upper

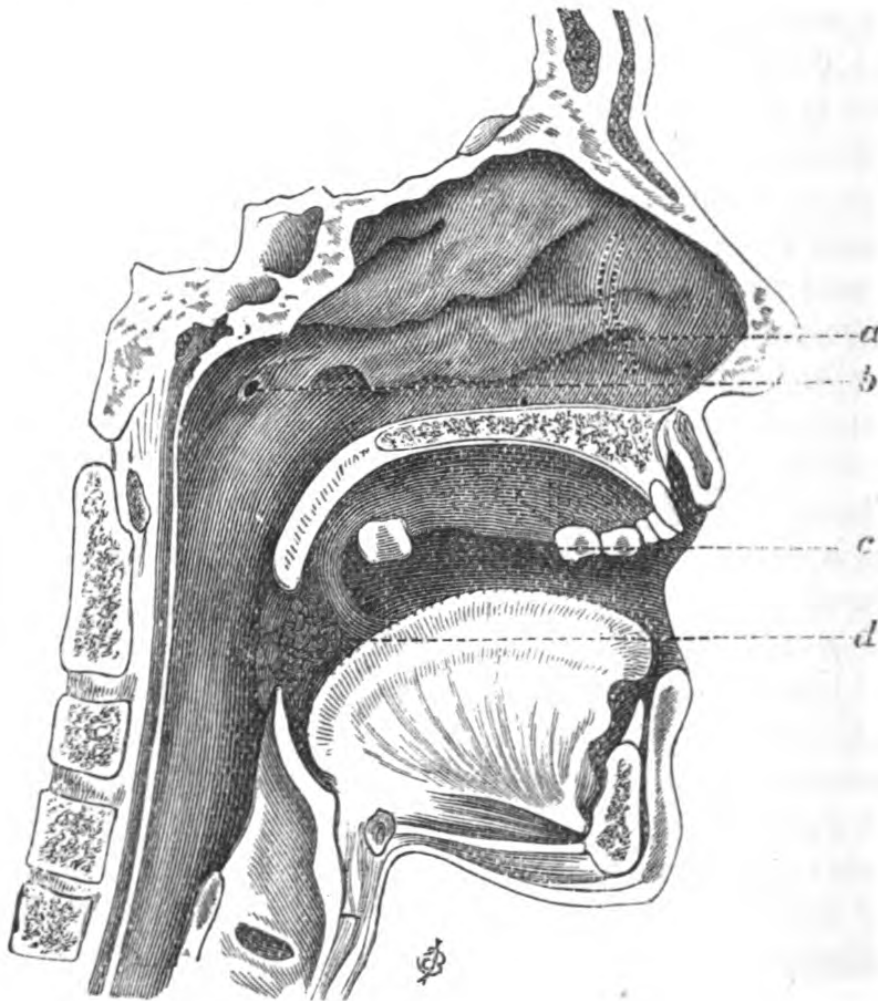


Fig. 10.

a, position of nasal duct; *b*, orifice of Eustachian tube;
c, orifice of Steno's duct; *d*, tonsil between pillars of fauces.

lip (Rouge's operation), when, by lifting up the lip, the floor of the nasal fossæ is readily seen and reached.

The *posterior nares* are oval in form, and almost vertical, and are about $\frac{4}{5}$ of an inch, or one inch deep, by about $\frac{2}{5}$ or $\frac{3}{5}$ wide, separated by the vomer, and

bounded laterally by the internal pterygoid processes. It is important to recollect the form of these apertures, as in cases of plugging the posterior nares, the pledget of lint should correspond in shape, otherwise there is a chance of its being dragged through the meatus, instead of compressing the bleeding vessels against the bone.

The mucous membrane lining the nares completely covers the surfaces of the above-mentioned bony parts, terminating in front at its juncture with the skin. In colour it is red, and its superior surface is studded with orifices of glands which secrete mucus. It is of variable thickness, and is very thin where it is prolonged into the several sinuses. It is thickest on the septum, especially so at its anterior half. It is moderately thick on the roof of the fossa, where it invests the proper bones of the nose and the cribriform plate of the ethmoid; it enters the sphenoidal sinus, and becomes very thin. It lines the anterior ethmoidal cells and the superior spongy bones; it sinks into the groove separating this bone from the sphenoidal sinus, and closes the sphenopalatine canal; and so it may be traced over each portion of the bony and cartilaginous structure to be continuous behind with the pharyngeal membrane and with the skin of the face in front.

Arteries.—This membrane is supplied by the sphenopalatine branch of the internal maxillary, which divides into two branches; the more internal being distributed to the septum, divides and passes towards the anterior palatine foramen; the external is distributed to the external parietes, and subdividing supplies the meatuses and spongy bones.

There are also branches from the superior dental (internal maxillary) to the antrum, from the infra-orbital, and from the pterygo-palatine, and from the ethmoidal (ophthalmic) and facial.

Veins.—The veins form a peculiarly complicated plexus (*rete nasi*), which collect and pass forwards,

terminating in the facial vein; others pass into the frontal vein, and another set pass through the sphenopalatine foramen into the plexus in the zygomatic fossa.

Nerves.—There are two sets of nerves distributed to the mucous membrane of the nose—viz., (*a*) those of special sense; (*β*) those of common sensation.

(*a*) The olfactory, derived from the olfactory lobe, penetrates in three layers the cribriform plate of the ethmoid bone, and is distributed to the ethmoidal and sphenoidal spongy bones, and to the upper part of the septum. (*β*) Those derived from the fifth are the nasal from the ophthalmic division, which passes to the anterior part of the mucous membrane, and leaves the cavity of the nose by passing between the lateral cartilage and the nasal bone (entering by the nasal slit). From Meckel's ganglion are given off the sphenopalatine branch for the septum and the external parietes; the posterior and inferior nasal from the anterior palatine, which is distributed to the posterior inferior portion of the external wall.

There is a point of considerable practical importance with regard to the relation borne by the velum pendulum palati to the posterior nasal apertures. If the mouth be opened there is an involuntary disposition to breathe through it, and thus the palate applies itself closely to the walls of the pharynx, cutting off the communication between the nose and mouth. In syringing out the nostrils, it will be found that if the mouth be open and the nozzle of the instrument be introduced into one of the anterior openings, the current of fluid will wash out the entire nasal cavity and pass out through the other again. In the case of the introduction of the mirror in posterior rhinoscopy, the palate must be forced forward by the emission of nasal sounds, or drawn forwards by hooks or forceps constructed for the purpose.

Nasal polypi of the fibro-cellular variety developed in the submucous tissue of this region are covered with ciliated epithelium, and are usually attached to the

superior or middle turbinated bones. The more formidable forms of growths generally project into the fossæ from the antrum or base of skull. The posterior nares, oval in form and of the same shape as their bony boundaries, enter into the formation of a region termed the *naso-pharyngeal*, situated midway between the nasal fossæ and the pharynx (*vide* "Pharynx.") It is formed also by the body of the sphenoid, the basilar process, and the pterygoid plates.

The basilar process is the usual locale of nasopharyngeal polypi, and its situation is readily recognized by passing the finger behind the velum pendulum palati, which frequently has to be divided in order to remove such growths.

The orifice of the *Eustachian* tube is a valvular aperture, situated on the inner surface of the internal pterygoid plate, and just above the posterior extremity of the inferior turbinated bone.

To introduce a sound or probe into it the extremity of the instrument should be bent at an angle of about 60°, and passed along the floor of the nostril with the concavity downwards, then pushed backwards by the side of the septum until the mucous membrane of the back of the pharynx is reached; next it is to be slightly withdrawn, and rotated between the fingers, so as to bring its point upwards and outwards, which may be known to be in the orifice of the tube when it cannot be made to rotate easily.

THE SINUSES OF THE NOSE.

The sinuses associated with the nasal cavities are six in number: Two frontal, two sphenoidal, and two superior maxillary or antra. The latter, from their position, it has been thought advisable to describe with the superior maxillary region.

The frontal sinuses.—These sinuses are not fully developed before puberty; they communicate with the nasal fossæ by the infundibula, and the mucous mem-

branes are continuous. They are occasionally the seat of growths.

The sphenoidal present no surgical interest.

The antrum, unlike the frontal sinuses, exists at birth, becomes developed at puberty, and its greatest expansion is in old age. It is in form like an inverted pyramid, the base corresponding with the floor of the orbit, and the apex with the alveolar ridge. It has four walls—an anterior, an internal, and a postero-external, which converge to alveolar ridge, and a superior.

The superior, forming the floor of the orbit, is very thin, and it readily permits of the invasion of growths from one cavity to the other. The anterior wall corresponds with the canine fossa and the cavity of the bone; readily reached from below the upper lip by perforating in the cul-de-sac, formed by the reflexion of the mucous membrane, opposite the first molar tooth.

The postero-external wall corresponds with the maxillary tuberosity. The inner wall corresponds with the nasal fossa, and presents two orifices, one constant, the other variable.

Growths within the antrum frequently protrude through one or other of these openings into the meatus, and may be mistaken for nasal polypi (*vide* "Superior Maxillary Region").

SURGICAL ANATOMY OF THE SUPERIOR MAXILLARY REGION.

This region may be regarded as that occupied by the superior maxilla and the tissues covering it. The superior maxilla is a bone of great surgical interest, on account of the many diseases to which it is liable; hence its position, relations, and connexions are of the highest practical importance.

Topography.—The skin and superficial fascia; the lower fibres of the orbicularis palpebrarum; the facial

and infra-orbital vessels and nerves; the zygomatici and the levator labii superioris; muscles; Steno's duct; the transverse facial artery; the buccal vessels and nerves; lymphatics, and the buccinator muscle. In the hollow between the anterior border of the masseter and the buccinator muscle is a large quantity of fat and cellular tissue, which contributes, either by its excess or deficiency, to the general contour of the face.

Articulations of the superior maxilla.—Articulating with its fellow, it forms the whole of the upper jaw; besides this, it articulates with the frontal, ethmoid, nasal, inferior turbinated, palate, vomer, malar, and lachrymal. The sutures it forms with those bones which enter into the formation of the face are very strong and difficult to separate, so much so, that in excision it will generally be found more satisfactory to divide it or its associate near to the articulation than to attempt to wrench them apart at the sutures. The processes requiring division in its extirpation are the palatine, nasal, and malar. Each bone assists in the formation of three cavities—the mouth, nose, and orbit; of two fossæ, the zygomatic and sphenomaxillary; and of two fissures, the sphenomaxillary and pterygo-maxillary. The relation of these fissures and cavities to the body of the bone is of great importance in the process of its removal. The apex of the antrum corresponds on the face to its malar process, the base of which looks inwards to the outer wall of the nose; and its roof is formed by the orbital plate, and its floor by the alveolar process. The walls of the antrum are very thin, so that growths or collections of fluid readily cause a bulging of its parietes and protrusions into neighbouring cavities or fissures. The fangs of the first and second molar teeth project into its floor, hence the importance of extracting one of these teeth, and perforating its socket before interfering with any doubtful tumour connected with the cavity (*vide* “Sinuses of Nose”).

Besides the growths which are developed in the antrum, the bone is surgically interesting as being subject to an arrest in its development, known as *fissured or cleft palate*, frequently associated with a similar one in its appendage, the upper lip, termed *hare-lip*. During its development that portion which carries the incisor teeth is a separate segment, and if this segment be disunited the result is a deep fissure, extending backwards into the palate; occasionally these segments in both bones are thus disconnected, in which case they both hang from the end of the vomer, leaving a chasm in the roof of the mouth, a condition usually associated with a double hare-lip.

Structures divided in excision of the upper jawbone.—Supposing the incision through the upper lip, along the ala of the nose, towards the inner angle of the orbit, and along its lower margin, to be adopted; first are the tissues composing the upper lip—viz., the integument, the orbicularis oris muscle, the cellular tissue containing the labial glands, the coronary vessels, facial, and branches of the second division of fifth nerves, and the mucous membrane. Next carrying the incision along the ala and side of the nose, the integument, fascia, levator labii superioris, alæque nasi, with its aponeurosis, the angular vessels and branches of the infra-orbital and facial nerves. The incision along the lower border of the orbit divides the integument, aponeurosis, orbicularis palpebrarum muscle, the vessels of the lower eyelid, and the orbital fascia; and if a portion of the floor of the orbit be removed, the tendon of the inferior oblique, and by turning back the flap enclosed by these incisions, the attachments to the bone of the following muscles—orbicularis, levator labii superioris et alæ nasi, levator labii superioris, compressor naris, depressor labii superioris, levator anguli oris, buccinator, infra-orbital vessels and nerve, and facial vessels and nerves. The advantage of this method of external incision is that the vessels are divided near their termination, and

not through their larger branches, the duct of the parotid is left entire, without the risk of salivary fistula, and an almost unnoticeable cicatrix is left, by following the natural furrows of the face.

In the second stage of the operation, an incisor tooth being extracted, the gum, alveolar process and structures forming the hard palate—malar and nasal processes, with a portion of the floor of the orbit. In the subsequent dislocation of the bone, the internal maxillary artery, with its vein and the branches after they have gained the pterygo-maxillary fossa; and the posterior palatine nerves are divided.

SURGICAL ANATOMY OF THE REGION OF THE SOFT PALATE AND TONSIL.

The soft palate, which is suspended obliquely from before backwards from the posterior border of the palatine arch, or hard palate, is a curtain consisting of mucous membrane, muscular and fibrous tissue, vessels and nerves, forming an incomplete septum between the nasal and buccal cavities, serving to prevent the food from passing upwards into the nasal fossæ, helping to push it downwards into the pharynx during deglutition, and also influencing the quality of the voice. Its movements are elevation, depression, and transverse tension. It is concave anteriorly, and its inferior anterior border presents two semilunar margins, the edges of which pass downwards to the sides of the tongue, united in a central raphé, from which depends a prolongation, the uvula.

In structure the soft palate consists anteriorly and inferiorly of a mucous membrane, thickly studded with muciparous glands, continuous with that of the posterior region of the mouth; and posteriorly and superiorly of a second membrane, continuous with that of the nasopharyngeal region. Between these mucous layers is a musculo-tendinous one, consisting of portions of the following pairs of *intrinsic* muscles—the levatores

palati and the *tensores* or *circumflexi palati*; and of *extrinsic* muscles, the *palato-glossi* and the *palato-pharyngei*. Some delicate muscular fibres are to be found in the uvula. The order in which the structures enter into the formation of the velum is as follows:—From before backwards (1) the anterior layer of mucous membrane; (2) the aponeurosis of the *tensores palati*, with which are blended the attachments of the *palato-glossi* and *palato-pharyngei*; (3) the *levatores palati*, uniting in the median raphé; (4) the posterior layer of mucous membrane.

The pillars of the fauces are formed by the divergence of the *palato-glossus* and *palato-pharyngeus*, and include a triangular interval, the base being downwards, in which is situated the tonsil. The posterior pillars formed by the *palato-pharyngei* are nearer each other than the anterior, formed by the *palato-glossi*.

The space between the palatine arches of both sides is called the *isthmus of the fauces*, and is bounded above by the free margin of the palate, below by the dorsum of the tongue, and laterally by the pillars of the fauces and tonsils.

A correct knowledge of the attachments and actions of the muscles of the soft palate is of great importance, with a view to the successful performance of operations for the relief of fissures or clefts in it.

The fibres of the *levator palati* pass downward and inward, spreading out on the velum as a layer, which is embraced by the two planes of fibres of the *palato-pharyngeus* and unites with its fellow of the opposite side. The *tensor palati* ends in a tendon, which is reflected horizontally round the hamular process of the sphenoid, and after spreading out is inserted into the aponeurosis of the velum, below the *levator palati*, and into the palate bone. *The position of the hamular process*, an important guide in the performance of operations, can be felt distinctly in the substance of the soft palate, internal to and slightly posterior to the last molar tooth.

The action of the palatine muscles upon a fissure existing in the velum would obviously produce a separation of its margins, and it has been shown that the muscular action by which these margins are brought together is caused by the upper semicircular border of the superior constrictor of the pharynx, and that the muscles to be divided in the operation of *staphylo-raphy* or stitching up the fissure, are the levatores palati and the palato-pharyngei, the upper expanded fasciculi of which are divided into two parts by the levatores palati, and if necessary the palato-glossi. (Fergusson.)

The levator palati is to be divided on both sides by putting the undeveloped velum upon the stretch, when a double-edged knife is passed through the soft palate, just on the inner side of the hamular process, and above the line of the levator palati.

Another method of dividing the levator palati is by passing a knife curved on the flat through the fissure and behind the flap, its edge making an incision half an inch long, half way between the hamular process and the orifice of the Eustachian tube, and perpendicular to a line drawn between them.

The *thickness* of the velum pendulum palati must be taken into consideration in this operation; it is often underrated, and hence difficulty may be experienced in freshening the edges of the cleft.

The palato-pharyngeus is to be divided by cutting through the posterior pillars just below the tonsil. Occasionally the palato-glossus requires division.

The *tonsils* or *amygdalæ* are two small glandular bodies, varying in size in different individuals, situated between the anterior and posterior pillars of the fauces, and covered in by the bucco-pharyngeal fascia. They are in relation, *externally* with the superior constrictor, and by it separated from the internal carotid and ascending pharyngeal vessels; *below* they rest on the side of the base of the tongue. The position of the tonsil corresponds with the angle of the inferior

maxilla. Under *certain* circumstances the carotid artery is in danger of being wounded, such as in excision of the gland or the evacuation of pus, when by its enlargement it is brought still more closely into connexion with the vessels; but if the precaution be taken of lifting it well from its bed forwards and inwards before the knife is applied for

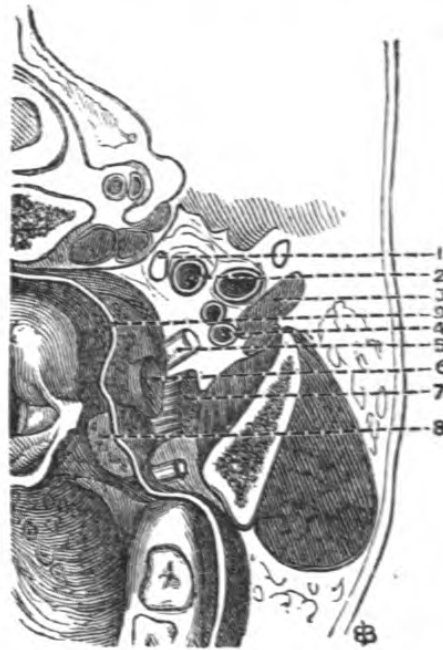


Fig. 11.—Diagram of the relations of the Left Tonsil viewed from above.

1, superior cervical ganglion; 2, internal carotid artery and jugular vein; 3, digastric muscle; 4, external carotid artery; 5, glosso-pharyngeal nerve (drawn too thick); 6, stylo-pharyngeus muscle; 7, stylo-glossus muscle; 8, the tonsil; 9, section of the pharynx and its mucous membrane.

its removal, the risk in this instance is avoided; and in the latter, care must be taken not to push the knife outwards in the line of the angle of the jaw, but backwards into the tumour towards the spine, and so allow it to cut its way out, towards the median line of the body.

There seems to be a great fear of wounding the internal carotid in excision of this gland, but a glance at its relations by a section shows that the vessel lies

at least an inch behind it, and about four lines in front of the internal carotid is the external carotid, diverging outwards into the parotid gland. It is, therefore, impossible that in dragging out the tonsil, either of these vessels should also be dragged out or wounded, and only by using pointed instruments, or unpardonable roughness, could it happen.

The *vessels* of this region are derived from the ascending pharyngeal of the external carotid, the ascending palatine and tonsillitic of the facial, the dorsalis linguæ of the lingual, and the descending palatine of the internal maxillary; and the *nerves*, from the glosso-pharyngeal and Meckel's ganglion.

SURGICAL ANATOMY OF THE PAROTID REGION.

The boundaries of the parotid region are somewhat difficult of definition, partly on account of the irregularity of the gland, and partly on account of its belonging both to the cranium and to the neck. The following appear to be the simplest:—*In front*, the posterior border of the ramus of the jaw; *behind*, the mastoid process of the temporal bone, the cartilage of the ear, and the edges of the sterno-mastoid and digastric muscles; *above*, the zygomatic arch; and *below*, an imaginary line drawn horizontally backwards and inwards from the angle of the jaw to the styloid process, by the stylo-hyoid and stylo-maxillary ligaments, and the process of cervical fascia passing from the sterno-mastoid to the jaw. The dimensions of this region obviously vary with the several movements of the lower jaw; moreover, there are certain differences in its size with respect to the age of the individual: thus, in the infant, the region is broader in proportion below, on account of the obliquity of the jaw and the non-development of its angle, and bulges externally, on account of the quantity of fat and lymphatics contained within it; again, in old age, in the edentulous

state, the base of the region becomes broader, owing to the falling forward of the jaw.

Beneath the integument covering the parotid gland, it will be seen to be enveloped in an incomplete capsule derived from the cervical fascia, which separates it from neighbouring structures.

The relations and connections of the parotid gland are, *externally and superficially*, the lymphatics, the platysma myoides, some few branches of the superficial cervical plexus, and the integument; *anteriorly*, the posterior border of the ramus of the jaw, the external and internal pterygoid muscles, between which lies a process of the gland; *inferiorly and posteriorly*, the mastoid process, the sterno-mastoid, posterior belly of digastric, styloid muscles, transverse process of atlas, internal jugular vein, internal carotid artery, eighth pair of nerves, hypoglossal nerve, and the superior cervical ganglion of the sympathetic.

The substance of the gland contains so many important structures that operative proceedings connected with it are rendered excessively difficult and hazardous. The external carotid artery traverses its posterior part, giving off its anterior and posterior auricular and superficial temporal branches. Behind the external carotid is the external jugular vein, which receives numerous branches in its substance. A quantity of lymphatics are also found in relation with the gland. The superficial lymphatic ganglia receive the vessels of the scalp; those within the gland, the vessels from the eyebrows, lids, and cheeks; and the deepest, which accompany the internal carotid, are the vessels of the temporal and maxillary regions. The facial nerve, after it has passed through the stylo-mastoid foramen, enters the posterior and inferior portion of the parotid, and thence spreads out into several large plexiform branches (*pes anserinus*), after which it ramifies amongst the muscles of the face. The auriculo-temporal branch of the inferior maxillary nerve also enters the gland after having passed behind the neck of the jaw, and forms

inosculations with the facial. The auriculo-parotidean branch of the cervical plexus enters the gland anteriorly and inferiorly, inosculating with the preceding.

The existence of the tough fibrous investment which encloses the gland almost entirely and binds it so tightly in its place, accounts for the intense pain in

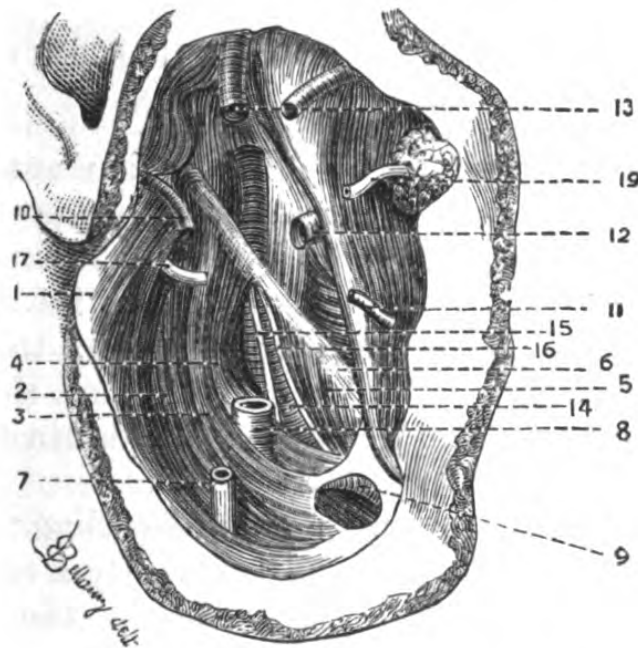


Fig. 12.—Sketch of the deep relations of the right Parotid Gland (the gland itself has been removed and the ramus of the lower jaw drawn forward).

- 1, remains of aponeurosis of gland; 2, digastric muscle; 3, stylo-hyoid muscle; 4, stylo-pharyngeus (drawn aside); 5, stylo glossus muscle; 6, stylo-maxillary ligament; 7, external jugular vein; 8, external carotid; 9, lingual artery seen through an opening in the aponeurosis; 10, posterior auricular artery; 11, transverse facial artery; 12, internal maxillary artery; 13, anterior and middle temporal arteries; 14, internal carotid; 15, hypoglossal nerve; 16, glosso-pharyngeal nerve; 17, trunk of facial nerve; 19, Steno's duct.

inflammation, as in *parotitis*, or abscess. Wounds, or the results of abscess in the substance of the gland, may give rise to *salivary fistulae*, which are frequently very troublesome to close; and in the removal of tumours connected with it, or in its neighbourhood, there is, of course, great danger of severe hæmorrhage, and of wounding the facial nerve, thus causing

paralysis of the facial muscles. The surgical relations of the duct of the parotid have been already considered (*vide* "Face"). The external carotid may be compressed against the styloid process in the adult, but it is impossible in the child, owing to the undeveloped state of that portion of the bone.

SURGICAL ANATOMY OF THE PTERYGO-MAXILLARY REGION.

The surface markings of this region are the bony prominences of the zygoma and lower jaw, and the contour of the masseter muscle, the tendinous intersections of which are very evident during its action. If the finger be passed into the mouth, the internal aspect of its ramus can be felt; and if the jaws are apart, its coronoid process; the mutual relations of which should be carefully noticed.

Topography.—The integument covering this region is very thick and mobile, and frequently a considerable quantity of fat is developed beneath it, the superficial fascia is very thin and continuous with that in neighbouring regions. The aponeurosis is attached above to the zygoma, below to the edge of the lower jaw, and in front it passes over the buccinator covering in the interspace between it and the masseter; and behind, it passes into the parotid region. Next are met with some branches of the facial nerve and transverse facial artery, the duct of the parotid, and that portion of the parotid which lies upon the masseter. Beneath the masseteric fascia is the masseter itself, which consists of two sets of fibres; the anterior forming the greater bulk of the muscle, and behind and below these some oblique fibres, which are inserted beneath the anterior. The origin of these fibres is on the under and inner surface of the zygomatic arch. It is to be noticed that the anterior surface of the zygoma is entirely subcutaneous. Beneath the zygoma the masseteric nerve and vessels enter the under aspect of the masseter through the

sigmoid notch. The skeleton of the region is the ramus, coronoid process, neck and condyle of the inferior maxilla.

Immediately behind the bone is a portion of the internal maxillary artery, the external pterygoid muscle, and emerging from its lower border the gustatory branch of the third division of the fifth, the mylo-hyoidean branch of the inferior dental nerve, part of the internal pterygoid muscle, the trunk of the inferior dental and deep temporal nerves, the internal lateral ligament of the temporo-maxillary articulation, and in front of the internal pterygoid the posterior portion of the buccinator.

The vessels of this region are, in the *superficial* to the bone—the transverse facial or external maxillary, which arises from the external carotid in the parotid gland, just above the angle of the jaw, and in relation with the portio dura and Steno's duct, crosses the masseter a little below the zygoma.

Beneath the bone the internal maxillary artery commences at the outer border of the neck of the jawbone, lying in the first part of its course behind it, and in front of the internal lateral ligament; it then curves forwards to the lower border of the external pterygoid muscle, lying on it, and, generally disappearing between its two heads, passes into the pterygo-maxillary fossa. The trunk of this vessel or its descending branch, the inferior dental, are usually divided in resection of the bone. Its tortuous course and variable position render it the more liable to be wounded.

The nerves are derived from the inferior maxillary division of the fifth, which passes into the region through the foramen ovale of the sphenoid. The nerve consists of two portions—a muscular, distributed to all the muscles of mastication—viz., masseteric, deep temporal, pterygoid, buccal; and a sensory—the inferior dental, auriculo-temporal, and gustatory. The relations of the salivary glands to the body of the inferior maxilla are of considerable importance with

regard to operations on it. The parotid envelopes the posterior border of its ramus, and passes behind its neck as far as the styloid process of the temporal bone; the submaxillary gland is partially lodged in a fossa, below the attachment of the mylo-hyoid, which during flexion of the head is concealed beneath, and in extension is considerably disengaged from the bone—facts to be considered in operations in the region of the upper part of the neck.

The temporo-maxillary articulation is formed between the glenoid cavity of the temporal bone and the condyle of the lower jaw. Interposed between the bones is a biconcave interarticular fibro-cartilage, above and below which is a synovial sac. The external portion of the circumference of this cartilage is connected with the external lateral ligament, whilst a portion of the tendon of the external pterygoid muscle is inserted into it in front controlling its movements. *The ligaments* are the external lateral, attached to the tubercle on the zygoma and to the external surface of its neck, which is covered over by the parotid gland; and the internal lateral, attached to the spine of the sphenoid and to the inner margin of the dental foramen. The external pterygoid muscle is in relation with this ligament above, the internal maxillary artery lies between it and the neck of the jawbone, and between its insertion and the ramus of the jaw are the inferior dental vessels and nerve; and on its inner side is the internal pterygoid muscle. The stylo-maxillary ligament, really a slip of the deep cervical fascia, is attached to the styloid process of the temporal bone and to the inferior angle of the lower jaw; it separates the parotid from the submaxillary gland, and gives origin to some fibres of the styloglossus muscle.

Owing to the numerous movements which the muscles of mastication are capable of causing, and to the comparative laxity of the ligaments of the articulation, the lower jawbone is liable to partial or complete *disloca-*

tion. The condyles glide forward, carrying the inter-articular fibro-cartilages with them, upon the eminentiæ articulares, in such conditions as yawning or laughing, or masticating large morsels; the combined action of the masseter and internal pterygoid muscles drags them under the zygomatic arches, whilst the temporal muscles drag the displaced bone upwards. The obstacle to reduction appears to be, that in most cases the coronoid process is, as it were, locked in front of the malar tubercle. Partial luxation of one condyle is of common occurrence, and occasionally a portion of that process of the parotid which wraps round the neck of the jaw is included between the opposing surfaces, causing severe pain and inconvenience. The principle upon which reduction is effected is by introducing some solid body between the molar teeth so as to form a fulcrum, whilst the power is applied at the symphysis, at the same time that the angles are depressed.

SURGICAL ANATOMY OF THE LINGUAL REGION.

By the lingual region is meant all the inferior wall of the buccal cavity.

The tongue completely occupies the cavity of this when the mouth is shut, and is attached for the posterior two-thirds of its volume to the hyoid bone and inferior maxillary bone, by its extrinsic muscles and membranes; by means of the stylo-glossus it is attached to the styloid process, and by the palato-glossus to the palatine arch. It is at this portion of the organ that the nerves and arteries enter and its veins leave it. Beneath it, in the middle line, is a fold of mucous membrane, the frænum, on either side of which are the orifices of Wharton's ducts; and those of the sub-lingual glands, or ducts of Riviniani, lie in the fossa between the tongue and maxillary bone.

Structure.—The *mucous membrane* is very adherent to the underlying structure, particularly on the dorsum

and sides ; on the under surface, however, it is less so, there being a cellular layer between it and the sublingual muscles. The mucous membrane is freely supplied with papillæ ; the sides and tip with fungiform, almost its entire surface with filiform, and the posterior part of its dorsum with the V-shaped series of the circumvallate. There are a considerable number of glands lying in this tissue, which give rise to the development of that encysted tumour known as *ranula*. An enlargement of the bursa existing between the hyoid attachment of the genio-hyo-glossi, by its enlargement and protrusion beneath the tongue, may be mistaken for ranula.

The *muscles* are both intrinsic and extrinsic. The intrinsic or linguales are two symmetrical bundles of muscular fibre, separated from each other by a fibrous septum, occasionally cartilaginous, and these muscular fibres are arranged into—(1) the lingualis superior, the fibres of which are disposed obliquely and longitudinally on the surface of the organ ; (2) an inferior longitudinal set, passing from the hyoid bone to the apex, and in relation on its under surface with the ranine artery ; its fibres are blended with those of the stylo-glossus ; (3) a transverse set, forming the bulk of the tongue, placed between the superficial and longitudinal, are attached to the fibrous septum, and curving outwards are inserted into the dorsum linguæ and its margin. The fibres interlace with the before-named sets. The existence of the fibrous septum explains how it is that in acute inflammation of the tongue, or when abscess has formed, the tumour is frequently unilateral.

The extrinsic muscles are—the hyo-glossus, genio-hyo-glossus, stylo-glossus, palato-glossus, and some few fibres of the superior constrictor.

Arteries.—The lingual artery at the anterior edge of the hyo-glossi muscles divides into the sublingual and ranine ; of these the ranine is the most important : it lies on the under surface of the tongue, external to the

genio-hyo-glossi, and on the inner side of the hyo-glossi, stylo-glossi, and sublingual gland. It enters the organ at its base, and runs forwards towards the tip, and in the mouth it lies to the side of the frænum, and is here covered only by mucous membrane; thus, in dividing this membrane for *tongue-tie*, the scissors should be directed *downwards* and *backwards*.

The ranine artery is generally accompanied by *two* ranine veins, which terminate in the internal and external jugular and the facial veins (*vide* "Lingual Artery").

The nerves are very numerous, and are derived from—(1) the hypo-glossal or ninth, which is supplied to the extrinsic muscles only—it is the *motor* nerve of the tongue; (2) the gustatory branch of the inferior maxillary division of the fifth, supplies the sides and tip—a nerve of *special sense*: these two nerves freely inosculate; (3) the glosso-pharyngeal, which supplies the circumvallate papillæ at its base—also a nerve of *special* sensation; (4) the facial, supplying the linguales, by means of the chorda tympani; (5) the vagus, sending a few filaments to its base; and (6) the sympathetic—the *vaso-motor* nerve, accompanying the lingual artery.

The base of the tongue is in relation with the epiglottis, which curves forwards towards it during respiration; but during deglutition it is drawn backwards and downwards, thus covering the aperture of the larynx and preventing food from passing into it (*vide* "Larynx").

SURGICAL ANATOMY OF THE PHARYNX.

The pharynx is a musculo-membranous tube, lying deeply behind the mouth and nasal fossæ, communicating superiorly with these two cavities, and the internal carotid, whilst below it is continuous with the larynx and œsophagus. The length of the pharynx varies from about $5\frac{1}{2}$ inches to $6\frac{1}{2}$ inches. It extends

from the basilar process to the space between the 5th and 6th cervical vertebræ, when the pharynx is at rest, but the contraction of its muscular structure gives rise to considerable variations in this respect. It is somewhat distended at its centre, and tightly contracted at the point where the œsophagus commences.

The breadth of the pharynx, at level of the isthmus of the fauces, is about from $1\frac{1}{2}$ inches to 2 inches, whereas at the level of the cricoid cartilage it is rather less than $\frac{1}{2}$ -inch; hence foreign bodies are liable to be arrested at this point, and may by pressure on the superior orifice of larynx cause instant death.

The pharynx presents for examination four walls—an anterior, which is only partial, since it corresponds with the openings into neighbouring regions, a posterior, and two lateral.

The *anterior* contains from above downwards the posterior nares, the velum pendulum palati, the posterior pillars of the fauces, base of tongue, epiglottis, the glosso-epiglottic folds, and larynx.

The *posterior* wall is in relation with the cervical vertebræ, being separated from them by the recti antici and longi colli muscles.

The *lateral* walls, also formed by the constrictors, are in relation with the sympathetic, glosso-pharyngeal, spinal accessory, vagus, and hypo-glossal nerves, internal carotid artery, and internal jugular vein. In front of the vessels and nerves, the pterygo-maxillary region, pterygoid plates of the sphenoid, deep portion of the parotid, and the lateral portion of the submaxillary region are in immediate relation with them. This close relation to the parotid and internal maxillary regions, explains the pointing of abscesses forming in these spaces at the sides of the pharynx.

For surgical examination the pharynx naturally divides itself into a nasal, a buccal, and a laryngeal portion.

The *nasal* is limited above by the basilar process,

which is very much inclined in a direction oblique from before backwards, below by a plane passing through the palate, and which would impinge on the ring of the atlas, and laterally by the pterygoid plates. The inferior aspect of the basilar process is covered

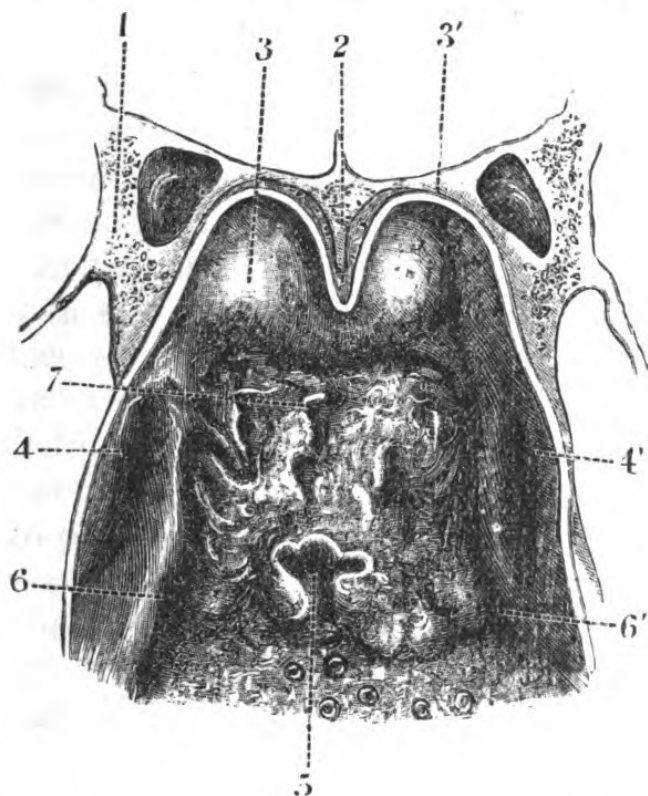


Fig. 13.—Roof and Posterior Wall of Pharynx.

1, sphenoid; 2, vomer; 3, posterior end of nasal fossa; 3, cut edge of mucous membrane; 4, 4', opening of Eustachian tube; 5, opening of bursa pharyngea; 6, 6', recessus pharyngeus; 7, adenoid tissue of pharynx.

with a dense fibrous membrane, which is a frequent seat of origin of naso-pharyngeal polypi. Its dimensions are about 1 inch to $1\frac{1}{2}$ inches deep, by $1\frac{1}{2}$ inches wide.

The *buccal* portion lies between the above-mentioned plane and the base of tongue and epiglottis below and on either side the lateral walls of the pharynx. This portion corresponds to the vertebral column, and by introducing the finger through the mouth the body of the axis and anterior tubercle of the artery can be

felt superiorly, and the upper borders of the 4th cervical vertebræ below. Its dimensions are from $1\frac{1}{2}$ inches to 2 inches in breadth to about $2\frac{1}{2}$ inches in depth.

The *laryngeal* portion extends from the base of the tongue to the lower border of the cricoid cartilage, and is about $2\frac{1}{2}$ inches to 3 inches long and about $\frac{1}{2}$ -inch wide.

Structure of pharynx.—By making a plane section through the tube, the following tissues would be included, from before backwards:—A mucous layer, a glandular layer, a fibrous layer (pharyngeal aponeurosis), a muscular layer, and a fibro-cellular layer. Between the fibro-cellular coat of the pharynx is a quantity of loose cellular tissue, in which *retro-pharyngeal* abscesses form, frequently from disease of the cervical vertebræ. These abscesses push the pharynx forward against the posterior nares if high up, and if lower down, by pressing upon the larynx interfere with respiration and speech. They can be readily detected by examining the posterior wall or by palpation. Occasionally these abscesses point at the side of the neck in front of the sterno-cleido-mastoid (*vide* “Fasciæ of Neck”).

CHAPTER II.

SURGICAL ANATOMY OF THE NECK.

THE region of the neck may be described as that portion of the body which is contained between the occipital bone, mastoid processes, and lower jaw above, and the superior aperture of the thorax below—namely, the first two ribs, laterally; the manubrium sterni, anteriorly; and the first dorsal vertebra, posteriorly; and for the sake of simplicity will be divided as follows:

An *anterior*, including the submaxillary or supra-hyoid region, and the infra-hyoid, or tracheal region; a *lateral*, the sterno-mastoid or carotid, the supra-clavicular, the occipital; and a *posterior*, including the nape of the neck—a method which seems advisable as being a natural one, and agreeable to its external conformation.

Surface markings.—The development of the neck varies in individuals, both with regard to age and to sex: round and smooth in females and children; muscular, and with all its prominences well marked, in adult males.

As far as its normal length is concerned, in adults it is tolerably constant, the difference in certain persons being rather apparent than real, resulting from some peculiarity in the conformation of the shoulders, etc. Its breadth is variable.

The points of chief interest to the surgeon are those concerning the hyoid and laryngeal apparatus and the sterno-cleido mastoids, and the hollows between and behind these muscles. The first prominence below the chin is the pomum Adami, which is far

more marked in males than in females, and becomes developed at puberty ; nearly a finger's breadth above this can be felt the hyoid bone, with the anterior belly of the digastric muscle sweeping upwards towards the chin. Immediately below the thyroid cartilages, in the median line, is a depression, indicating the position of the crico-thyroid membrane ; next, the body of the cricoid cartilage itself ; below this, the upper rings of the trachea may be distinguished, and at about the third ring the isthmus of the thyroid body can generally be made out, more particularly in women. The position of the laryngeal apparatus during swallowing should be noticed, as it is drawn upwards at the commencement of the act, returning to its normal position on its completion, the thyroid body being carried with it. This fact is of great value in the diagnosis of tumours in the region of the trachea or carotid vessels. In children the trachea is more deeply placed, very small and moveable (*vide* "Trachea").

The anterior and posterior borders of the *sternocleido-mastoidei* are very evident, even when these muscles are at rest, from the prominent mastoid processes to their inferior attachments—the sternal of which is fusiform and cordlike, and the clavicular, flat and ribbon-shaped, lying posterior to the former, and variable in its extent along the clavicle. The point of divergence of these two sets of fibres is generally well seen, more especially, however, when the muscle is in action, as in rotation of the head from side to side. These points will be hereafter seen to be important landmarks to the surgeon in the operative surgery of the neck. Between the angle of the jaw and the mesial line is the protrusion of the submaxillary gland, the difference in the position of which during flexion or extension of the neck should be carefully noted. Above the clavicle, and between the prominences of the sternocleido-mastoid and trapezius, is a hollow, the *supra-clavicular fossa*, at the lower and internal part of which the posterior belly of the

omo-hyoid crops up from behind the clavicle. This muscle lies much more hidden by the sterno-cleido-mastoid and clavicle than is usually represented in plates of the posterior triangle. It is seen in action after swallowing, during the depression of the hyoid bone, and during deep inspiration. The subclavian artery beats at the bottom of this hollow, and is here readily compressed against the first rib (*vide* "Surgical Anatomy of Subclavian Triangle"). The lateral contour of the neck is completed, behind, by the sweep of the trapezius from the occiput to the tip of the shoulder. Posteriorly the neck presents a median depression, on either side of which is seen the mass of the extensor muscles of the head, and lower down the spinous processes of the sixth, seventh, and eighth (*Vertebra prominens*) cervical and first dorsal vertebræ. The external jugular veins are seen on the lateral aspect of the neck, crossing the sterno-mastoid obliquely, from before backwards, at about its middle, and passing into the hollow behind it. The more detailed account of these superficial markings will be found in the description of the several regions of the neck.

*Arrangement of the cervical fascia.**—The attachments and connexion of the fasciæ of the neck are of great surgical importance, inasmuch as these aponeurotic sheaths in a great measure control the course taken by diffuse inflammation, collections of pus, blood, and growths; the latter frequently not appearing externally in the neck until some while after they have extended or sent processes along or amongst them.

For convenience of examination and simplicity of description it may be divided into two layers—a superficial and a deep, and these laminæ and the spaces they enclose may be studied by horizontal and vertical

* It has been thought advisable to introduce the description of the cervical fascia here, as a correct idea of it will facilitate that of the several regions of the neck.

sections. First, by horizontal section. The *superficial* layer is usually traced from behind, where it commences as a very thin lamina attached to the spinous processes of the cervical vertebræ, superior curved line of the occipital bone, and ligamentum nuchæ; and passing forwards, getting denser as it proceeds, it encloses the trapezius, and, forming sheaths for the posterior muscles of the neck, extends over the posterior triangular space, and arriving at the posterior border of the sterno-cleido-mastoid, forms a sheath for it; and part of it, which constitutes the anterior portion of this sheath, is attached to the lower border of the body and angle of the lower jaw and zygoma, after having covered in anteriorly the parotid gland and masseter muscle; below it is attached to the anterior part of the clavicle and manubrium sterni, and is perforated by the external jugular vein and cutaneous nerves. The *deeper layer* has an attachment to the tubercles of the transverse processes of the cervical vertebræ, and encloses the scaleni muscles, forming the prevertebral aponeurosis, which sends processes over the cords of the cervical and brachial plexuses and subclavian vessels. The lax cellular tissue lying between the prevertebral aponeurosis and the pharyngeal muscles is the seat of retro-pharyngeal abscesses, which point either into the pharynx or, guided by fascia, behind the carotid vessels (*vide* "Pharynx"). Passing from the under surface of the sterno-mastoid towards the middle line, it is attached to the hyoid bone, forming an aponeurotic loop on its upper surface, through which runs the tendon of the digastric; and extending downwards it forms the sheaths of the sterno-hyoid and sterno-thyroid muscles. The lamina forming the posterior portion of the sheath of the sterno-mastoid is attached above to the angle of the jaw and to the base of the styloid process behind, and to the inner side of the parotid gland, forming a septum between it and the submaxillary gland, the *stylo-maxillary ligament*.

The lower portion of this lamina forms the sheath of the carotid vessels, which sheath is divided by septa enclosing internally the carotid artery, externally the internal jugular vein, and posteriorly the vagus nerve; traced downwards and outwards it is found to enclose the omo-hyoid muscle, binding it down to the clavicle, and enclosing the subclavius muscle, passes beneath it

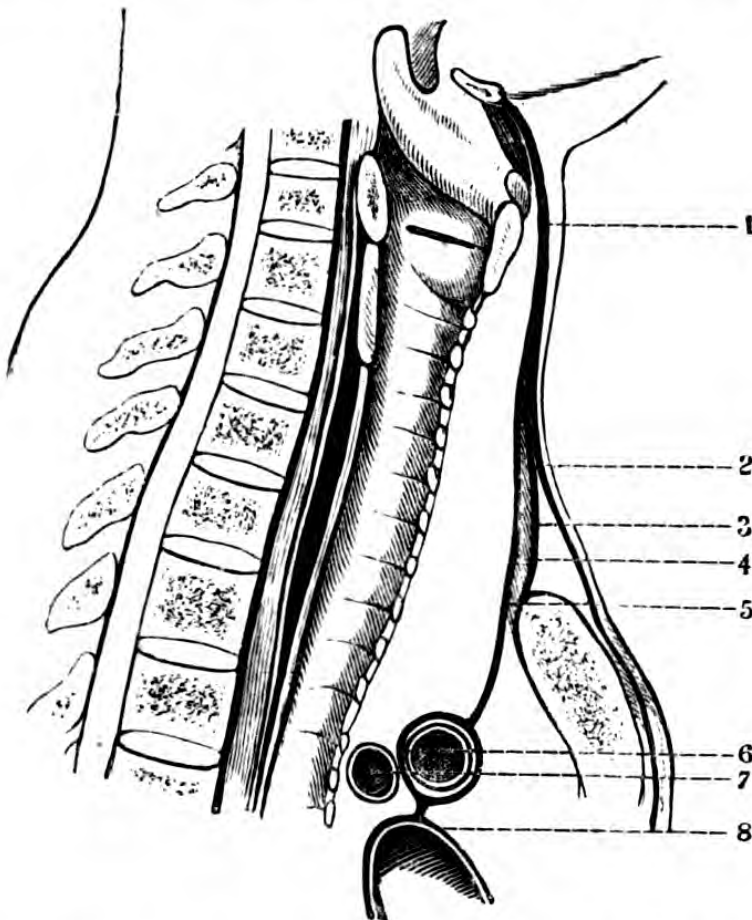


Fig. 14.—Diagram of an Antero-posterior Section of the Infra-hyoid Region in the median plane.

1, 2, superficial lamina of superficial fascia; 3, middle lamina; 4, reduplication of this lamina passing behind the sternothyroid, and enclosing the left innominate vein, and becoming continuous with the pericardium; 5, space occupied by sterno-hyoid; 6, left innominate vein; 7, innominata; 8, pericardium.

into the axilla, to be continuous with its fasciæ (*vide* "Axilla"). At the root of the neck this fascia is easily demonstrated to be continuous with the pericardium.

If the arrangement of the cervical fasciæ be studied in a vertical section, it may be seen that the three laminae differ in their arrangement according as this section falls on the sternum or on the clavicle, if in the mesial line (Fig. 14) the anterior passes in front of the hyoid bone, and terminates in the anterior aspect of the sternum. The middle lamina, after ensheathing the sterno-hyoid and thyroid, at their sternal attach-

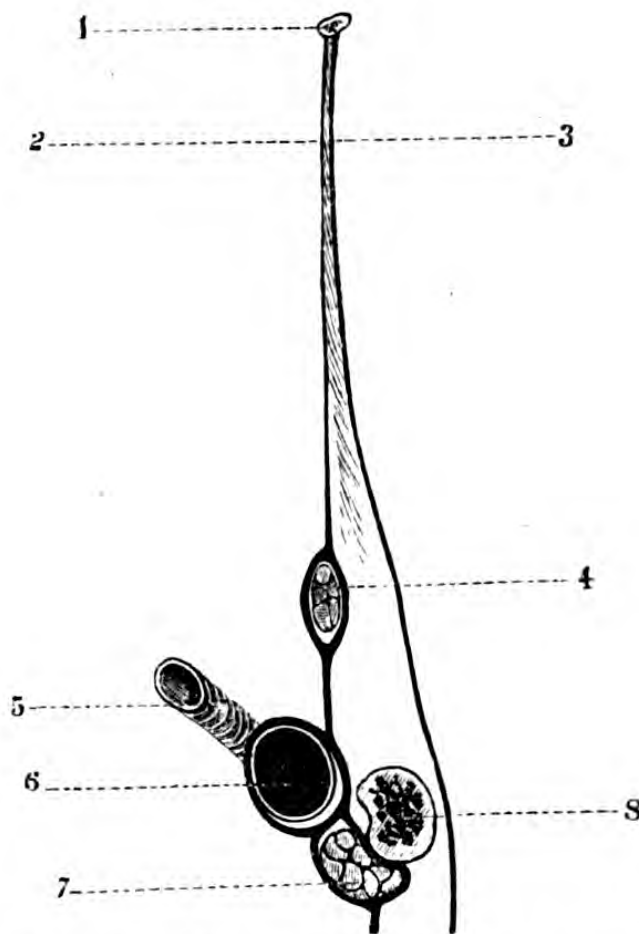


Fig. 15.—Diagram of a Section of the Infra-hyoid Region passing through the middle of the Clavicle.

1, hyoid bone; 2, middle lamina of cervical fascia; 3, superficial lamina of cervical fascia; 4, omohyoid; 5, subclavian artery; 6, subclavian vein; 7, subclavius muscle; 8, clavicle.

ments, divides into two layers, an anterior in front of the sterno-hyoid, and firmly attached to the sternum; and the posterior, which lies behind the sterno-thyroid,

and, after enclosing the left brachio-cephalic vein, is continuous with the pericardium. If the section passes on one side of the mesial line (Fig. 15), so as to fall on the clavicle, the anterior lamina is the same as before, the middle one furnishes a sheath to the omo-hyoid, and becomes attached to the posterior border of this bone, and, after enclosing the subclavius muscle, passes on to form the suspensory ligament of the axilla, the middle lamina of the subdivision encloses the subclavian vein; whilst the posterior covers over the subclavian artery, the nerves of the brachial plexus, and the transverse processes.

That portion of the fascia which is attached to the hyoid bone above and to the clavicle and sternum below, has been supposed to have some influence on respiration, enclosing in its reflexions the depressors of the hyoid bone, and sending processes around the great venous trunks. The omo-hyoidei, in particular, by their contraction tighten it, and when tense, the calibre of the veins is increased, and as these muscles only contract during *inspiration*, the dilatation of the veins coincides with the dilatation of the thorax, thereby urging the blood towards the heart. This, moreover, explains how readily air may pass into the right side of the heart should any one of the larger veins or some branch close to the trunk be divided.

These several layers of fascia are attached both to the margins of the superior aperture of the thorax and to those structures which pass upwards or downwards through it; and as they are connected together by transverse septa, they constitute a species of diaphragm between the cervical and thoracic regions.

Cervical abscess.—An examination of the cervical fascia shows that there are distinct cellular spaces confined by them, which may be the seat of abscess.

1. *The capsule of the submaxillary gland.*

2. *The prævisceral space.*—This lies in front of the larynx, thyroid gland, and trachea, and behind the tongue muscles, passing upwards from the sternum.

By far the greater number of abscesses in this space commence in the gland or in the cellular tissue surrounding it. They press on the trachea, and may pass into the anterior mediastinum.

3.—*The perivascular space.*—The cellular space in which lie the great vessels, and which is in direct communication with the thorax. Abscesses are very liable to form here, on account of the great number of lymphatic glands. They follow the course of the vessels, or they may point at the side of the trachea, at the lower third of the sterno-mastoid, rarely at the posterior border, or they may pass into the anterior mediastinum.

4. *The space beneath the lower portion of the sterno-mastoid.*—The omo-hyoid, with its investing fascia, bounds the upper border of this space, and posteriorly are the scalmi and the great nerves; and hence below is a free communication by means of the subclavian vessels and nerves with the apex of the axilla.

5. *The retropharyngeal or retrovisceral space.*—This lies behind the pharynx and œsophagus, and abscesses developed therein may point laterally in the region of the vessels, anteriorly into the pharynx, or they may extend downwards into the posterior mediastinum.

6. *Prævertebral abscesses.*—Those associated with disease of the cervical vertebræ are bound down by the lamina of fascia covering in the prævertebral muscles, and may either burst through it, or, guided by the nerves of the cervical and brachial plexus, pass downwards into the axilla.

SURGICAL ANATOMY OF THE SUBMAXILLARY REGION.

This region is bounded *above* by the body of the lower jaw, and the floor of the mouth; *below*, by the hyoid bone; *externally*, by the anterior margin of the

sterno-cleido mastoid muscle. Its surface markings have been already described.

Topography.—Immediately beneath the integument is the subcutaneous cellular tissue, and the fibres of the platysma myoides muscle passing obliquely from the jaw towards the chest and shoulder. The anterior border of this muscle is free, and separated from its fellow by a cellular interval. Beneath this muscle is a very lax cellular tissue, in which ramify the nerves supplying it, derived from the facial and upper cervical. A portion of the superior layer of the deep cervical fascia is next met with, attached along the jaw covering in the submaxillary gland, and forming the anterior portion of its capsule; it is continuous externally with the sheath of the sterno-cleido-mastoid, and with the fascia covering the parotid anteriorly. A great many lymphatic glands lie either upon or beneath the capsule of this gland, and when enlarged can be readily felt beneath the integument. Beneath this aponeurosis, and enclosed by that portion of it which is attached to the cornu of the hyoid bone, are the submaxillary gland, the stylo-hyoid and digastric muscles. The fibres of the stylo-hyoid enclose the tendon of the digastric before they are inserted into the hyoid bone, just before that muscle passes through the loop derived from the deep cervical fascia. The muscular fibres of the posterior belly of the digastric are superior to those of the stylo-hyoid, and after being reflected from the hyoid bone, spread out into a large muscular mass, having many tendinous intersections (frequently interlacing with those of the opposite muscle), to be inserted into the digastric fossa of the inferior maxilla. Lying in the interval between the two bellies of the digastric, and overlapped by its posterior belly and by the body of the jaw, is the *submaxillary gland*, enclosed in its capsule, the posterior portion of which is continuous with the stylo-maxillary ligament, which separates it from the parotid gland, and superior to it is the facial artery and vein; the submental branches of these vessels, with the nerve to the anterior belly of

the digastric, pass forwards towards the symphysis under cover of the body of the jaw. The bulk of the gland being pulled upwards from the fossa in which it is lodged, it will be observed that a portion of it passes beneath the mylo-hyoid muscle, upon which the greater part of it rests.

The structures which lie beneath the mylo-hyoid muscle are, from before backwards, the genio-hyoid; and deeper down the genio-hyo-glossus, along the outer side of which lie the ranine vessels, and external to it the deep portion of the submaxillary and the sublingual glands, and the mucous lining of the floor of the mouth; the hyo-glossus muscle, extending from the cornu of the hyoid bone to the side of the tongue, and upon this muscle from below upwards the ninth or hypo-glossal nerve, Wharton's duct, the gustatory nerve with the submaxillary ganglion and chorda tympani, and the inosculating branches of these two nerves. Upon the cornu of the hyoid bone is seen the trunk of the lingual artery just before it disappears behind the hyo-glossus muscle.

Arteries.—The *facial* artery in this region passes beneath the posterior belly of the digastric and stylo-hyoid muscles and the submaxillary gland, and after giving off branches to the gland, and the submental, it becomes subcutaneous, about an inch in front of the angle of the jaw.

The *lingual* artery is deeper in its course and distribution, and is directed towards the hyo-glossus, and is at first covered by the skin, platysma, and fascia, and rests on the middle constrictor; after passing over the cornu of the hyoid bone, it is crossed by the ninth nerve, the digastric and stylo-hyoid muscles forming an arch over it. It is next covered by the hyo-glossus, and lies on the superior constrictor and genio-hyo-glossus muscles.

The *branches* given off from it are—the hyoid, which runs along the upper border of the hyoid bone; the dorsalis linguæ, supplying the dorsum of the tongue,

the tonsil, and soft palate ; the sublingual, supplying its substance, and the ranine.

Ligature of lingual artery.—To place a ligature upon the lingual artery, that portion of its course where it lies upon the great cornu of the hyoid bone is selected, immediately before it passes behind the outer border of the hyo-glossus muscle, as it is there most accessible ; and to reach it, a slightly curved incision is to be made about a finger's breadth below the body of the jaw through the integument and aponeurosis, and the submaxillary gland is to be lifted upwards. After the posterior portion of the capsule of this gland has been divided, the combined lingual and facial veins may be seen passing obliquely forwards, and deeper, the hypo-glossal nerve ; at the angle where this nerve meets the tendon of the digastric, lies the artery, taking a curve downwards towards the hyoid bone. Occasionally the vessel pierces the hyo-glossus muscle, this muscle may extend farther back than usual, in which case its fibres must be divided transversely. On the dead body the vessel appears to be tolerably near the surface, but during life the fascia and integuments are so on the stretch and so attached to the salient parts of the region, that when the vessel is exposed, it is actually very deep. The operation is a difficult one, the vessel being only supported by the loose wall of the pharynx, which runs considerable danger of being wounded, so that the only sure firm guide to it is the posterior cornu of the hyoid bone. The hyoid bone may be with advantage drawn forwards into the wound and steadied with a hook.

Veins.—There is often a considerable plexus of veins in this region, the most important being the facial and the lingual ; the facial leaves its artery and passes upon the fascia in front of the submaxillary gland, whilst the lingual vein is separated from its artery by the hyo-glossus muscle. Very often these veins form a common trunk, lying superficial to the hypo-glossal nerve, before entering the jugular vein.

Nerves.—The superficial nerves have been already referred to ; the hypo-glossal enters the region superficial to the external carotid and below the stylo-hyoid and digastric muscles, and passes upwards over the cornu of the hyoid bone between the gland and the hyo-glossus muscles, covered in by the mylo-hyoid ; it loops with the gustatory and is seen distributed to the extrinsic muscles of the tongue. The gustatory nerve, with the chorda tympani, lies beneath the gland and passes to the mucous membrane of the sides and tip of the tongue, upon its deeper portion.

The above relations are those borne by the different structures in this region when the head is in its natural position, but when the parts are the seat of operation, and the head thrown back, the contents of the space are put on the stretch ; by so doing the position of the submaxillary gland and the facial vessels are considerably altered, as the cavity which naturally exists between the lower jaw and the mylo-hyoid muscle becomes flattened, causing a protrusion of the structures between them. As there are no vessels or nerves of importance in the mesial line of this region, advantage is taken of this to attack cancerous tumours of the tongue from below the jaw, in the operations of Regnoli, etc.

SURGICAL ANATOMY OF THE INFRA-HYOID OR LARYNGO-TRACHEAL REGION.

The *boundaries* of this region are—*above*, the hyoid bone and the base of the tongue ; *laterally*, the sternomastoid muscles ; *below*, the upper border of the manubrium sterni, or inter-clavicular notch ; *posteriorly*, the cervical vertebræ, covered by the longi colli muscles and deep fascia.

This region is surgically important as containing the larynx and trachea, the cervical portion of œsophagus, and the thyroid body, with their respective vessels and nerves.

Topography.—Beneath the integument is the subcutaneous cellular tissue, and the anterior portion of the platysma, which is usually unconnected with its fellow of the opposite side, there being a cellular interval between them formed by the fascia superficialis, which joins its fellow lamina of the opposite side in the mesial line, well marked in the necks of old people when the fat is absorbed, causing the “dew-lap” appearance characteristic of age. In this superficial fascia is the anterior jugular vein, or *mediana colli*, and which is subject to considerable variation. Beneath the platysma and its envelope is a thin layer of cellular tissue, which allows of the free movements of the integument and platysma over the underlying aponeurosis. This layer of the cervical fascia from the edge of one sterno-cleido mastoid to the other consists of but one lamina, including the sterno-hyoid muscle and a portion of the omo-hyoid. In the supra-sternal fossette, there is a lamina extending between the sternomastoid and the manubrium sterni, and which, about an inch and a half above the bone, blends with the sheath of the sterno-hyoid, enclosing some lax cellular tissue, in which is a plexus of veins associated with the anterior jugulars. The sterno-hyoid and omo-hyoid muscles themselves form the next layer, in their aponeurotic sheaths, and immediately below them lie the sterno-thyroid and thyro-hyoid muscles. The sterno-hyoid muscles pass somewhat obliquely, so that the interspace between their internal free borders is rather wider towards the sternum than at the hyoid bone; whilst the inner margins of the sterno-thyroids are slightly oblique in the opposite direction. The nerves supplying these muscles are seen generally on their posterior borders, or ramifying upon them.

Below the sterno-hyoid and thyro-hyoid lie the cricothyroid muscles between the thyroid and cricoid cartilages. This completes the muscular layer. Superiorly between the thyroid cartilage and the hyoid bone is the thyro-hyoid membrane, and behind this

structure is the mucous membrane, extending from the root of the tongue to the pharynx, and thus common to the bucco-laryngeal cavity. The lobes of the thyroid body are connected by means of the isthmus, which lies usually over the second or third rings of the trachea, and occasionally a so-called suspensory ligament passes from it to the hyoid bone. Below the isthmus is a plexus of veins; the interior and middle thyroid passing downwards within the thyroid body, and the thyroidea ima artery, when it is present. Surrounding the trachea itself is a zone of lax cellular tissue, allowing of its free movement. Laterally the tracheal apparatus is in relation with the sterno-hyoid and sterno-thyroid muscles, and the lobes of the thyroid body, which separate it from the great vessels and vagi nerves, and with the superior and inferior thyroid arteries, a plexus of veins, and the recurrent laryngeal nerves. On the right side of the neck, the common carotid artery crosses the lower portion of the trachea obliquely, but subsequently lies parallel to it; on the left side the common carotid is deeper than on the right and lies along the trachea. It must be borne in mind that neither of these vessels is in *actual* contact with the trachea. Behind the trachea is the œsophagus, which commences opposite the fifth cervical vertebra and cricoid cartilage, and passes to its left side—a circumstance which is taken advantage of in the performance of the operation of œsophagotomy. The recurrent laryngeal nerve lies in the interspace between the borders of the trachea and œsophagus, and passes below the inferior constrictor and into the larynx through the crico-thyroid membrane.

For convenience of reference, in this region two triangular spaces, termed by Velpeau the *omo-hyoid* and the *omo-tracheal*, may be noted; the former, bounded by the hyoid bone above, sterno-mastoid externally, and the omo-hyoid internally, contains the superior thyroid artery, superior laryngeal nerve, a portion of the middle and inferior constrictors, aë of

thyroid cartilage, and thyro-hyoid membrane; the latter is bounded above and externally by the omo-hyoid, below and externally by the sterno-mastoid, and internally by the middle line of the neck, and contains the sterno-hyoid and thyroid muscles, a lobe of the thyroid body, the superior and inferior thyroid arteries, the descendens and communicans noni nerves, sides of cricoid cartilage and trachea, the recurrent laryngeal nerves, and, on the left side, the œsophagus.

Vessels.—*The superior thyroid artery* arises from the external carotid artery, below the greater cornu of the hyoid bone, and at first lies superficially, in a space bounded by the sterno-mastoid, digastric, and omo-hyoid muscles. It then passes upwards and inwards, and arches down to the upper part of the lobe of the thyroid body, lying below the omo-hyoid, sterno-hyoid, and sterno-thyroid muscles, having behind it the superior laryngeal nerve. Its crico-thyroid branch runs transversely across the crico-thyroid membrane, and may be wounded in laryngotomy.

The inferior thyroid artery, in this region, passes obliquely upwards and inwards, crossing behind the common carotid artery, internal jugular vein, pneumogastric, and sympathetic nerves; and on the left side it lies in front of the œsophagus and behind the thoracic duct, and enters the lower part of the lobe of the thyroid body. These and the superior and posterior vessels very freely anastomose with each other, and with those on the opposite side.

Veins.—*The superficial veins* are generally two small parallel ones having a loop between them, and terminating in the supra-sternal fossette, and having communicating branches on either side with the subclavian veins. They are subject to several anomalies. No fear of danger need be felt at dividing them during an operation. *The deep veins* are those coming from the lower border of the thyroid body, the middle and inferior thyroid veins. They form a plexus, and terminate in the left innominate vein.

Non-surgical wounds, whether suicidal or otherwise, are invariably made *across*, and, as a rule, the main vascular trunks escape, unless the attempt be very determined, for the head is thrown back and these main trunks recede, when the sterno-mastoid is put on the stretch. The usual situation selected for such attempts is the thyro-hyoid space, and the incisions frequently divide the larynx and some branches of the superior thyroid artery, and not unfrequently cut through the base of the tongue and epiglottis.

Trachea.—All openings made *surgically* into the air-passage are made in the *middle* line, for the very important reasons that the muscular coverings of the trachea do not unite in the mesial line, but merely approximate, leaving a cellular interval, through which the windpipe is reached, and, moreover, that normally no arteries exist in median line. Unless the middle line be adhered to, although the trachea may be opened, great difficulty will probably be experienced in the introduction of the tube, as it will have a tendency to slide between the muscles and the trachea, and miss the opening made in it. Again, supposing no difficulty to arise of this nature, the muscles may be so much wounded as to be seriously impaired, and become united to the integument after the tube is removed.

Nerves.—The superior laryngeal nerve lies deep down in this region, passing behind the external and internal carotids, and divides into two branches—an external, supplied to the crico-thyroid muscle, and a deep one, penetrating the thyro-hyoid membrane and distributed to the mucous membrane of the larynx (*vide* “Sub-clavian Artery”).

This region is of great surgical importance: as well as being the usual seat of injuries inflicted suicidally or homicidally, the operations of thyrotomy, laryngotomy, cricotomy, tracheotomy, and œsophagotomy are performed therein.

The windpipe may be opened by:—

Thyrotomy, in which the thyroid cartilage is opened

in the mesial line, and its alæ separated for growths or impacted foreign bodies.

Laryngotomy, in which the crico-thyroid membrane is divided; this is the readiest method of admitting air, the only complication which might arise being hæmorrhage from the crico-thyroid arteries, which run across this space. The incision in the membrane, which is made horizontally, must not be so wide as to injure the crico-thyroid muscles.

Tracheotomy is the operation in which the rings of the trachea are divided either above or below the isthmus of the thyroid body.

It must be borne in mind that, although the trachea is very superficial above, it recedes, and is very deep below, and just above the sternum is generally at least an inch from the surface, its depth varying according to the amount of fat or muscle in the individual, or to the curvature of the cervical vertebræ. Occasionally the rings are ossified in old persons, and may cause trouble.

In *children*, owing to the shortness of the neck, and the depth, small calibre, and mobility of the trachea, the operation is a difficult one. Again, the plexus of veins in connexion with the thyroid body and the closeness of the carotids, render it one demanding the greatest care. The innominata is proportionably higher up in the neck than in the adult, on account of its obliquity.* In children under two years of age, and in some who are far older, the thymus gland may give great trouble by bulging up into the wound, and so obstructing the operator's view of the parts.

The variations in the relation of the position of the thyroid body to the manubrium sterni in adults and children are important.

In children up to the twelfth year, when the larynx is undeveloped, the space between the lower border of the gland and the manubrium is larger than that

* In a case in the author's practice, the innominata in an *adult* held this position, and had to be carefully hooked aside before the completion of the operation.

between the upper border of the gland and the hyoid bone. In adults, where the laryngeal apparatus is developed, the space is so small that as a rule the gland is under the sternum, or may pass behind it, whilst in children the *thymus* gland crops up over the manubrium. Consequently in adults, and particularly in males, the exposure of the trachea above the isthmus is tolerably difficult, and should the gland pass down behind the sternum, there is a possibility of wounding the left innominate artery or infra-thyroid vein.

This variation in the position of the gland in adult women is similar to that in children under puberty, and has obviously an influence on the choice of method of operating.*

The absence of arteries in the middle line, as is almost uniformly the case, shows that there is less apprehension of danger in the middle line from hæmorrhage than laterally. The *thyroidea ima* is the only one which would be met with in such a plane, and this is found in one in every ten bodies. As this vessel takes its origin in almost every instance from the *innominata*, its distribution must be looked for somewhat to the right of the middle line. As the trachea lies further distant from the surface of the body as it descends, the operation of tracheotomy is easier of performance the nearer the surgeon approaches the larynx. Consequently, unless there are contra indications, it should be performed above the thyroid body. It must be recollected that this gland should be drawn downwards by a blunt instrument in order to freely expose the upper rings of the trachea, a proceeding unattended with difficulty, owing to the mobility of the organ. Should the operation be performed below the thyroid body, there is considerable depth of tissue to get through before reaching the trachea, and, moreover, great attention must be paid to the position of the vessels of the neck. The position of these trunks is

* Linhart : "Compendium der Chirurg. Operationslehre."

not so constant that any general rule for their distance from the upper edge of the sternum can be given.

In the performance of tracheotomy, there is a variation in the relative position of the trachea and the anterior surface of the neck in the different positions of the head. During extreme extension of the head, the trachea is brought considerably nearer the surface of the neck, and is consequently more accessible. Moreover, the field of operations is much more extensive than when the chin is in the usual position of depression.*

Foreign bodies in the trachea are naturally directed towards the *right bronchus* because it is wider than the left. The septum at the bottom of the trachea, which separates the bronchi, occupies the left of the median line.

The bifurcation of the bronchi takes place in front of the interspace between the third and fourth dorsal vertebræ.

The right bronchus is shorter and more horizontal than the left, being about one inch long. The left is about two inches in length, and is directed more obliquely than the right.

SURGICAL RELATIONS OF THE ŒSOPHAGUS IN THE NECK.

The œsophagus is occasionally the seat of operation, such as the removal of some foreign body, the passing of bougies in cases of stricture, or introducing the tube of a stomach-pump. The operation of *œsophagotomy* is required but rarely, but it may be had recourse to in such cases as impaction of foreign bodies, when the substance can neither be pulled out through the mouth, nor pushed downwards into the stomach, or in such a case as where a substance might be removed through a longitudinal wound in the œsophagus, but could not be drawn

* Braune: "Topographish. Anat. Atlas," translated by author.

through the more constricted portion of the tube—as, for instance, a set of false teeth, etc., or in cases of stricture.

In the neck, it commences as a constriction below the pharynx, having at this point the cricoid cartilage in front, and the fifth cervical vertebra behind it. It terminates opposite the eleventh dorsal vertebra.

Just at first, it lies in the mesial line of the body, but as it approaches the root of the neck it inclines towards the left side of it.

In front of it lie the trachea, the left lobe of thyroid body, and the thoracic duct.

Behind, left longus colli, the cervical vertebræ and a layer of loose cellular tissue, and the deep layer of cervical fasciæ.

At the sides, the common carotid vessels, the left being nearer, the thyroid body, and the recurrent laryngeal nerves.

Great care must be taken, in passing bougies or tubes through the mouth into the œsophagus, to keep the end of the instrument well against the spine, and to use very gentle pressure, as false passages are readily made (especially where there has been any disease) into the pleural cavity, posterior mediastinum, or pericardium.

The operation of œsophagotomy is thus performed. An incision is to be made on the left side of the neck, about four inches long, along the anterior border of the sterno-mastoid, as though for ligaturing the common carotid artery above the crossing of the omo-hyoid. The omo-hyoid, sterno-hyoid, and sterno-thyroid muscles are to be drawn inwards, and the sheath of the vessels, intact, drawn outwards; the œsophagus is then seen at the bottom of the wound, when a longitudinal incision is to be made upon the foreign body or bougie as it lies in the tube.

The *structures to be avoided* are—the sheath of the vessels, the thyroid vessels, the thyroid body, and the laryngeal nerves.

The occipital portion of the side of the neck, that above the crossing of the omo-hyoid, possesses few points of surgical importance beyond its being the seat of tumours. Its boundaries are—in front, the sterno-mastoid; behind, the trapezius; and below, the omo-hyoid; its floor is formed by the upper portion of the anterior scalene muscle, the middle and posterior scalene, the levator anguli scapulæ and splenius colli muscles. The spinal accessory nerve emerges from the junction of the upper and middle third of the posterior border of the sterno-mastoid and crosses the region obliquely, to enter the trapezius, accompanied by descending muscular branches of the cervical plexus; the superficial branches of the cervical plexus are seen passing upwards (small occipital) along the posterior border of the sterno-mastoid, forwards (great auricular and transverse cervical) across it, and downwards (descending cervical). There are a great many lymphatic ganglia along the posterior border of the muscle, and the integument is very tough and fibrous.

SURGICAL ANATOMY OF THE STERNO-MASTOID REGION.

Topography.—The boundaries of this region may be sufficiently stated as being those occupied by the sterno-cleido-mastoid muscle itself. This muscle forms an oblique rectangular eminence, and is attached above to the mastoid process and the superior curved line of the occipital bone, its broad tendinous *insertion* being blended with the fibres of origin of the trapezius; passing downwards and forwards, its muscular fibres become divided, the anterior set collecting themselves into a round fusiform bundle, to be attached to the manubrium sterni, and a posterior bundle, a flattened riband-like band, separated from the former by a cellular interval, and attached for a variable distance along the inner and upper aspect of the clavicle. (Occasionally these clavi-

cular fibres pass along the whole inner two-thirds of the clavicle, forming a muscular layer, almost covering in the posterior triangular space.) This interval in the disposition of the muscular fibres is of great surgical importance. The anterior border is the more prominent, and is rounder than the posterior, which becomes lost in the general surface of the posterior part of the neck. In most works on descriptive anatomy it is not sufficiently enforced that this muscle completely covers in the common, internal, and external carotids, and that while the muscle, its integuments, and the fascial coverings are intact, it may surgically be considered to extend forwards as far as the angle of the jaw. The pulsations are in reality felt beneath its anterior border, or immediately beneath its sternal and clavicular attachments.*

Topography.—*Structures superficial to the sternocleidomastoid.*—Beneath the skin and cellular tissue the first structure met with is the platysma, passing obliquely backwards from the jaw to the shoulder, and below this layer of muscular tissue the structures met with are, some filaments of the small occipital nerve, the great auricular nerve, the external jugular vein, which usually crosses the muscle obliquely at about its middle, to pass ultimately into the subclavian vein, the transverse superficial cervical nerve, passing forwards to the under surface of the platysma and integument, and some branches of the descending clavicular nerves. The disposition of the fibres of the platysma, as far as regards the direction of the external jugular vein, is important, as in venesection it is necessary to cut *across* them, and not in their continuity, otherwise the wound would close from muscular contraction. That portion of the cervical aponeurosis which forms the anterior layer of the sheath

* According to Richet it is impossible to puncture the common carotid from the side of the neck without perforating the sternomastoid. This is true in the normal position of the head, but if it be turned to either side the traction upon the sheath of the vessels causes it to emerge beyond the edge of the muscle.

of the muscle is next seen, attached above to the angle of the jaw (almost appearing to divert the anterior

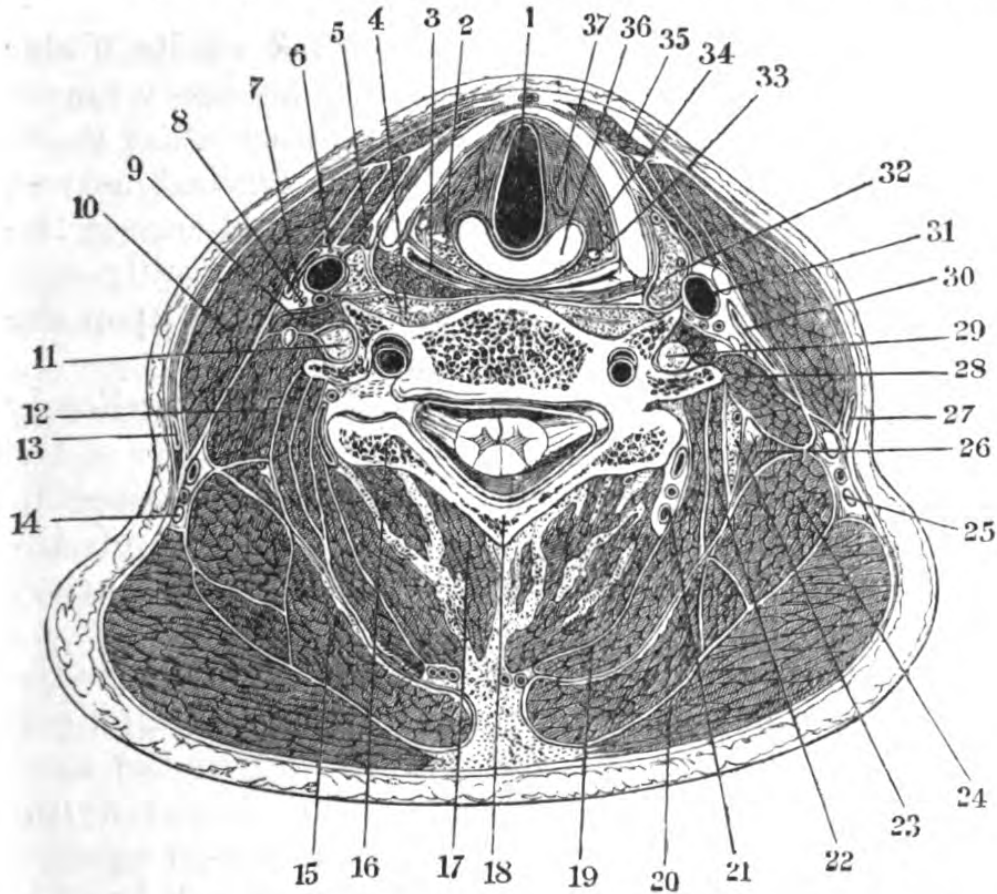


Fig. 16.—Section of Neck through the Sixth Cervical Vertebra (one half).

- 1, larynx; 2, recurrent laryngeal nerve; 3, pharynx; 4, longus colli muscle; 6, descendens noni; 7, vagus; 8, phrenic nerve; 9, scalenus anticus; 10, sterno-cleido-mastoid; 11, brachial plexus; 12, scalenus medius; 13, external jugular vein; 14, spinal accessory nerve; 15, splenius; 16, part of articular surface of seventh cervical vertebra; 17, semi-spinalis and multifidus; 18, sixth cervical vertebra; 19, biventer cervicis and complexus; 20, trapezius; 21, profunda cervicis vessels; 22, transversalis cervicis and trachelo-mastoid; 23, cervicalis ascendens; 24, levator anguli scapulæ; 25, spinal accessory nerve; 26, scalenus posticus; 27, external jugular vein; 28, scalenus medius; 29, brachial plexus; 30, internal jugular vein; 31, common carotid artery; 32, thyroid gland; 33, muscular process of the thyroid cartilage; 34, crico-arytenoid lateralis; 35, sterno-hyoid (just posterior are seen the thyro- and omo-hyoid muscles); 36, cricoid cartilage; 37, thyro-arytenoid muscle.

border of the muscle from the straight line), and below to the clavicle, and to the corresponding fascial sheath

of the opposite muscle ; and after completely enclosing the muscle at its posterior border, it becomes continuous with the aponeurosis of the neck.

The sterno-cleido-mastoid is perforated on its under surface, near the centre, by the spinal accessory nerve, which enters it obliquely and, after inosculating in its substance with the second and third cervical nerves, passes out behind its posterior border, and crosses the posterior triangular space. The muscle is readily seen in action, on rotating the head, or on bowing it upon the thorax, when *both* muscles are used.

Parts beneath the sterno-cleido-mastoid.—Immediately behind the muscular fibres, is the posterior layer of the sheath ; and between it and the muscle lie a considerable number of lymphatics, and some twigs of the sterno-mastoid branches of the superior thyroid artery and veins.

The most convenient method of grouping the structures which lie beneath the muscle is to divide it into three portions making the crossing of the omohyoid to separate the middle and lower, and a line drawn backwards from the angle of the jaw to separate its middle and upper. Beneath the posterior layer of the sheath in the upper third, from above downwards, the structures met with are—the insertion of the splenius capitis, beneath which are the attachments of the posterior belly of the digastric and of the trachelo-mastoid, the posterior auricular and occipital vessels, the external border of the complexus, while still deeper are the attachments to the atlas, of the obliqui and rectus lateralis muscles, the vertebral artery, and sub-occipital nerve. In the middle third, passing obliquely into the under surface of the muscle, is the spinal accessory nerve, which unites with some filaments of the cervical plexus ; next appear, a chain of lymphatic glands (*glandulæ concatenatæ*), the branches of origin of the superficial cervical plexus, the descendens, and communicans noni nerves. Beneath them lie the common internal and external

carotid arteries and jugular vein, the hypoglossal nerve, the vagus, the superior cervical ganglion of the sympathetic, and deeper down upon the spinal column the attachments of the rectus anticus major, scaleni, levator anguli scapulæ, and splenius colli muscles. Next is the crossing of the omo-hyoid, and in the inferior third from within outward are the outer borders of the sterno-hyoid and thyroid muscles, covered by their aponeuroses, with the nerves supplying them. Posteriorly and externally are the scaleni and the cervical plexus, the phrenic branch of which lies on the anterior scalenus, having the ascending cervical artery lying parallel and internal to it. Beneath the scalenus anticus are the third part of the subclavian artery, a quantity of lymphatic ganglia, and, enclosed in their proper sheath, lying obliquely, in the middle of this space, the common carotid artery and the internal jugular vein which joins the subclavian vein below; into the junction of which pass, on the right side, the common lymphatic trunk, and on the left the thoracic duct with its tributaries. Posteriorly, are the vagus and the recurrent laryngeal nerves, and closer down on the spine the cord of the sympathetic and the middle cervical ganglion, lying on the prevertebral aponeurosis. Posterior to the carotid vessels and below, is that portion of the *subclavian artery* which lies internal to the anterior scalenus. This vessel, on the right side, arises from the innominate, and lies immediately behind the inferior angle of the divergence of the sternal and cleidal origins of the cleido-mastoid, and is separated from the sterno-clavicular articulation and origins of the sterno-hyoid and thyroid muscles, by the junction of the internal jugular and subclavian veins. The vagus and phrenic nerves lie in front of it, with numerous branches of the sympathetic; whilst embracing it, and passing behind it, is the recurrent laryngeal nerve. Behind it is the transverse process of the seventh cervical vertebra, and internally the common carotid itself; below and externally, this

portion of the subclavian artery is in relation with the pleura.

The branches of the *subclavian artery* being normally derived from the first part of its course, it follows that on the right side these branches lie beneath the clavicular portion of the sterno-cleido-mastoid muscle; and this fact, added to the mechanical difficulty of reaching it, forms a serious obstacle to success on placing a ligature upon it in this situation. In the event of the operation being undertaken, it should be tied as near the vertebral as possible, so that a coagulum may be formed between this point and the origin of the trunk.

On the *left* side the recurrent laryngeal is not in relation with the subclavian artery in the neck (*vide* "Subclavian Artery").

COMMON CAROTID ARTERY.

As referred to the surface, the course is represented by a line drawn from the sterno-clavicular articulation, to the external aspect of the upper border of the thyroid cartilage, at which level generally it divides into external and internal carotid.

From a surgical point of view, it is advisable to divide the carotid region into three distinct portions, an inferior, a middle, and a superior; the first two corresponding with the common carotid artery, and the latter with its bifurcations.

Inferior portion.—In this portion, the left common carotid in the neck is a little deeper and rather longer than the right.

In front of it lie successively the integument, platysma, sternal origin of sterno-mastoid, sterno-hyoid, sterno-thyroid, omo-hyoid, in their aponeurotic sheaths, the anterior jugular, and a portion of the brachio-cephalic veins. It corresponds with the interval between the two heads of the sterno-cleido-mastoid, and advantage is taken of this to apply a ligature to

the vessel at this point below the crossing of the omo-hyoid.

Externally : Internal jugular vein, vagus nerve, and lymphatics.

Internally : Trachea, thyroid body, recurrent laryn-

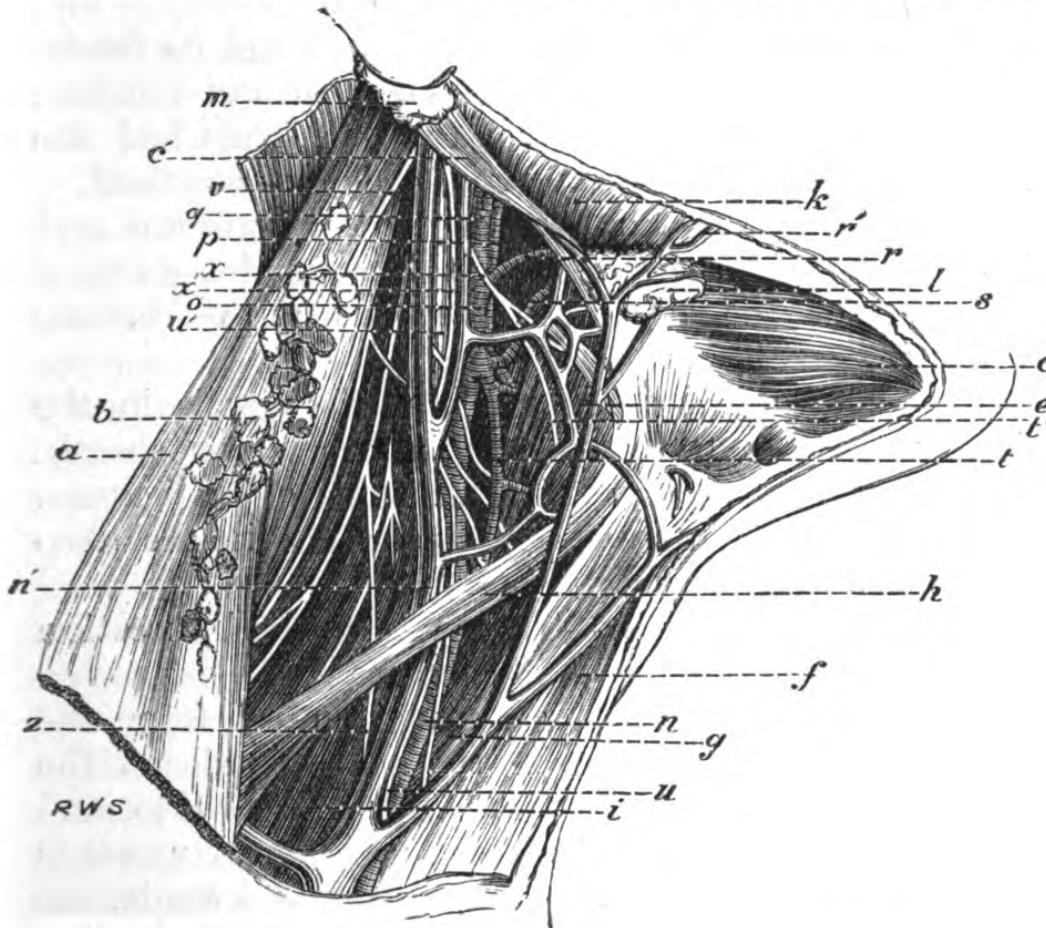


Fig. 17.—Common Carotid Artery and its Branches.

a, sterno-mastoid reflected; *b*, glandulae concatenatae; *c*, anterior belly of digastric; *c'*, posterior belly of digastric; *e*, thyro-hyoid; *f*, sterno-thyroid; *g*, sterno-hyoid; *h*, omo-hyoid; *i*, anterior scalenus; *k*, masseter; *l*, submaxillary gland; *m*, parotid gland; *n*, Common carotid; *n'*, internal jugular vein (joined by the anterior jugular and supra-scapular); *o*, external carotid; *p*, internal carotid; *r*, facial; *r'*, facial vein; *s*, lingual; *t*, superior thyro-hyoid; *t'*, nerve to thyro-hyoid; *u u'*, vagus; *v'*, spinal accessory nerve; *x*, hypoglossal nerve; *x'*, descendens noni nerve; *z*, phrenic nerve.

geal nerve, inferior thyroid artery, larynx, and pharynx.

The middle portion is the seat of election for ligature

of this vessel, and it lies in its sheath with its vein and nerves at the bottom of a well-marked furrow in the neck, and is here most superficial. This furrow is formed by the sterno-mastoid externally, and the laryngo-tracheal tube internally.

In front are merely the common integuments and the slight over-lap of the sterno-mastoid and its fascia.

Externally, the internal jugular vein and common carotid artery are covered by the omo-hyoid and the loop between the descendens and communicans noni.

Behind, the vessel is crossed by the vertebral and inferior thyroid arteries, and it lies on the anterior tubercles of the transverse processes of the cervical vertebræ, notably the sixth.

The vagus nerve also lies behind the vessels in the furrow between them and in their common sheath. This must be borne in mind in applying a ligature. The sympathetic lies quite posterior and in the deep fasciæ covering the prevertebral muscles.

The superior portion.—This contains the bifurcation of the vessel into external and internal.

The external carotid artery is given off from the main trunk, usually opposite the upper border of the thyroid cartilage; it is at first a little *internal* to, and in front of, the *internal* carotid, and passes upwards and forwards, and afterwards a little backwards, towards the angle of the jaw. Up to the level of a line drawn from the mastoid process to the hyoid bone the artery is superficial, but at this point it gets deeper, being crossed by the ninth nerve, the posterior belly of the digastric and stylo-hyoid muscles and a plexus of veins; it then enters the lower border of the parotid gland.

The branches of the external carotid are usually given off in the following order:—the superior thyroid; the ascending pharyngeal; the lingual; the facial; the occipital; the posterior auricular; and it terminates in the temporal and internal maxillary.

Relations of external carotid.—*In front*: Integument,

platysma, and fasciæ, sterno-mastoid, hypoglossal nerve, lingual and facial veins, posterior belly of digastric and stylo-hyoid muscles, and parotid gland.

Behind: Superior laryngeal nerve, styloid process, stylo-glossus and stylo-pharyngeus muscles, glosso-pharyngeal nerve, and that portion of the parotid gland which separates it from the carotid.

Internally: Hyoid bone, pharynx, parotid, ramus of jaw, and stylo-maxillary ligament.

The internal carotid artery (cervical portion) arises opposite the upper border of the thyroid cartilage, and is at first superficial and external to the external carotid, until the crossing of the digastric, where it becomes deeper and lies beneath the external carotid. Usually it gives off no branches in the neck, and is larger than the external in the child, but of much the same calibre in the adult.

Relations of the cervical portion of the internal carotid.—*In front*: Integument and platysma, sterno-mastoid, parotid, hypoglossal nerve, styloid process, stylo-glossus, and stylo-pharyngeus muscles, glosso-pharyngeal nerve and its branches.

Externally: Internal jugular vein, and vagus nerve.

Internally: Pharynx, ascending pharyngeal artery.

Behind: Rectus anticus major muscle, sympathetic, and superior laryngeal nerves.

This region is the seat of most important operations—viz., ligature of the common carotid arteries or their branches, of the subclavian in the first part of its course, of the innominate, of œsophagotomy, the removal of tumours, and opening of abscesses.

Injuries, such as stabs, etc., to those large vessels in the inferior and middle regions, are of the gravest nature, and the diagnosis of the actual vessel wounded is very difficult, and sometimes absolutely impossible. For instance, a wound inflicted by a pointed instrument might involve the common carotid, the vertebral, or the inferior thyroid, or all of them.

The point of bifurcation of the common carotid is

the most common seat of aneurisms, here the method of treatment of placing a ligature between the sac and the heart, and as far as possible away from the origin of the subclavian, is to be preferred.

In cases of *wound* of the *internal jugular vein*, a ligature should be applied above and below the point; injuries of this kind are usually fatal; but it sometimes happens that the vessel may be punctured during an operation without any very serious result, the circulation being readily re-established in the venous system of the head and neck.

With regard to the injuries to the superior portion of the neck, and the application of a ligature, there is great difficulty of recognizing the external from the internal carotid artery in the wound, and a good method is to bear in mind that the latter gives off no branch on the neck, and, moreover, that the hypoglossal nerve crosses the vessel obliquely, and is in immediate contact with the external which lies highest. Again, we may try whether by compressing the exposed vessel the temporal pulse stops or not.

Ligature of the common carotid artery.—In applying a ligature to the common carotid, that portion of it which lies either immediately above or immediately below the crossing of the omo-hyoid should be selected, as the vessel is there most easily reached.

Above the omo-hyoid.—The incision to be made varies in length, according to the nature of the case, and the depth of the subjacent structures, but is usually one about three inches in length, along the anterior border of the sterno-mastoid, from just below the angle of the jaw to the cricoid cartilage, dividing the integument, superficial fascia, and platysma; the wound being kept open by retractors, the deep fascia is observed, this is very adherent to the sheath of the vessels; a plexus of veins, and a few small arterial twigs, are often interspersed between it and the sheath. This fascia should be cautiously divided on a director,

so as to expose the sheath, upon or beneath which is the descendens noni nerve.

Next a small portion of the sheath is to be pinched up and "nicked," by holding the blade of the knife horizontally, immediately over the inner aspect of the vessel, as far from the vein as possible; and an aneurism needle is to be passed *from without, inwards*, and kept closely round the artery, so as to avoid wounding the internal jugular vein or including the pneumogastric nerve. There is a tough layer of areolar tissue between the sheath and the artery, which must be gently "teazed" through, by the needle, on being pushed against the finger nail. The jugular vein may be compressed above and below during the operation, as it is liable to become suddenly so distended as to conceal the parts. Should any difficulty in reaching the vessel be met with, owing to engorgement of the veins, an important landmark will be found in the anterior tubercle of the transverse process of the sixth cervical vertebra, which is behind and a little internal to the carotid artery, and against this the carotid may be compressed. (Chasaignac's tubercle.)

Below the omo-hyoid.—Tying the vessel *below* the omo-hyoid is much more difficult, owing to its greater depth, and to the size of the veins. An incision should be made about three inches in length from the cricoid cartilage, along the anterior border of the sterno-cleido-mastoid (which is to be drawn outwards), taking care to avoid wounding the lower sterno-mastoid artery and the middle thyroid vein; the fascia covering the sterno-hyoid and sterno-thyroid muscles is next seen, and must be cautiously divided, and these muscles pulled inwards, the sheath being reached (upon which are branches of the loop of the descendens and communicans noni nerves) is to be opened, and the needle passed *from without, inwards*. The inferior thyroid artery and sympathetic and recurrent laryngeal nerves lie immediately behind the vessel in this part of its

course. It must be borne in mind that, on the right side of the neck, at its lower part, the internal jugular vein diverges from the artery; but on the left approaches it, and sometimes crosses it, owing to the formation of the innominate veins. As before mentioned, advantage may be taken of the natural interspace between the two heads of origin of the sterno-mastoid to place a ligature on this portion of the vessel, but it is very difficult for the reason just stated. Another method of reaching it is to expose and divide the sternal attachment of the sterno-mastoid, thereby obtaining greater room and corresponding safety.

Collateral circulation after ligature of the common carotid.—Supposing the vessel to be normal—that is to say, that it gives off no branch before the usual bifurcation, the collateral circulation is very free, and is re-established by vessels both without and within the cranium; thus the current of blood being arrested in the carotid, the subclavian of the same side becomes dilated, the work outside the skull is thrown upon the inferior thyroid branch of the thyroid axis, the superior thyroid branch of the external carotid, the profunda cervicis of the superior intercostal, and the princeps cervicis of the occipital; the vertebral doing the work of the internal carotid, *within* the skull.

Ligature of the external carotid artery.—An incision is to be made similar to that for tying the common carotid above the omo-hyoid, where the vessel is most superficial, and immediately beneath the skin, platysma, and superficial fascia, and a complicated plexus of veins. The posterior belly of the digastric and its attendant muscle, the stylo-hyoid, should be drawn upwards towards the jaw, and the sterno-mastoid outwards; the superior laryngeal branch of the vagus lies usually just behind its short trunk.

The collateral circulation after ligature of the external carotid would be readily maintained by its branches anastomosing so freely on the face with those of the opposite side, and by the terminal branches of the

internal carotid (supra-orbital, ethmoidal palpebral, and nasal) with the facial, and by the profunda and princeps cervicis.

Tenotomy.—The attachments of the sterno-cleido-mastoid to the clavicle and sternum occasionally require division, *subcutaneously*, for the relief of wry-neck or *torticollis*, and considerable caution is requisite in this apparently simple operation, as there is a danger of wounding the external jugular vein as it passes into the internal jugular, or even more important vessels, if it be clumsily or hastily performed. The division should be made about three-quarters of an inch above the clavicle.

SURGICAL ANATOMY OF THE SUBCLAVIAN REGION.

Surface markings.—The hollow which exists above and behind the clavicle is almost invariably well-marked, even where there is a considerable quantity of fat in the neck; and it is this space, with its numerous contents and varying conformation, which is of such surgical import. This hollow corresponds with the apex of the lung, hence the necessity of auscultation at this point, when there is any suspicion of tubercle. It is bounded anteriorly by the posterior border of the sterno-cleido-mastoid; behind, by the rounded anterior border of the trapezius—these muscles nearly meet above at their cranial attachment, where their aponeuroses are blended; below by the clavicle, and above by the crossing of the posterior belly of the omo-hyoid, and its floor is formed by the first rib and the muscular structures attached to it.

The pulsation of the subclavian artery can be felt at the bottom of the space as it crosses the first rib, on which it can be readily pressed for any operation about the shoulder or arm. The positions of the scalene muscles, the cords of the brachial plexus, particularly those of the fifth and sixth, and the course of the omo-hyoid, are also felt, and generally to be

seen, as eminences beneath the integument. It must be borne in mind that the "triangle" formed by the crossing of the omo-hyoid is a result of *dissection*, and the detachment of its aponeurosis; no such *regular* interspace existing during life, the inner border of the muscle lying behind the clavicle, and its upper border only, being seen whilst in action. The change in the appearance of the hollow immediately above and behind the clavicle is noticeable under certain circumstances;

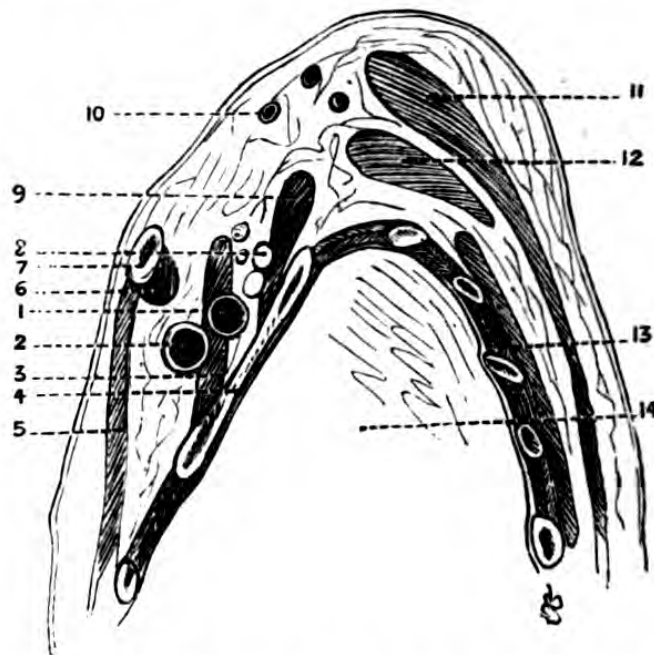


Fig. 18.—Diagrammatic Section through the Centre of the Right Clavicle, showing the relation of the subclavian vessels in their antero-posterior direction.

1, subclavian artery; 2, subclavian vein; 3, anterior scalenus muscle; 4, first rib; 5, pectoralis major; 6, subclavius muscle; 7, clavicle; 8, cords of brachial plexus; 9, scalenus medius; 10, transversalis colli artery; 11, trapezius; 12, levator anguli scapulae; 13, rhomboid; 14, cavity of thorax.

thus, in *inspiration*, it is considerably deepened, and during *expiration* becomes flatter, when the pulse in the subclavian *vein* is generally visible. Again, the various movements of the arm and of the clavicle cause considerable modifications of its form, and the relations of its contents—facts of great importance to the surgeon. The presence of a cervical rib on the seventh

cervical vertebra, by throwing up the subclavian artery, might lead to a suspicion of aneurism.

Compression of the subclavian artery is generally necessary in amputations about the upper arm, and very slight pressure is requisite. The thumb or finger is to be slipped just behind the posterior border of the sterno-mastoid, where it is attached to the clavicle, and on slight pressure being made in a *vertical* direction to the axis of the body, the pulsation of the vessel is felt; a little further pressure at the pulsating point compresses it against the first rib, and does not interfere with the circulation in the subclavian vein. The circulation may be controlled also, in many instances, by drawing the arm backwards, and forcibly depressing the tip of the shoulder.

Topography.—Beneath the skin is the superficial fascia, which is attached above to the superior curved line, and below to the anterior border of the clavicle and sternum. The first structures met with, are the descending superficial branches of the cervical plexus (the acromial and clavicular), and a considerable number of lymphatic glands. Beneath the layer of the cervical fascia which covers in the space is a quantity of loose cellular tissue and fat, in which lie lymphatics and superficial cutaneous and glandular vessels. The upper border of the omo-hyoid, enclosed in its sheath of deep cervical fascia, is next met with, the anterior layer binding down the subclavian vein against the clavicle, which vein here receives the external jugular just behind the attachment of the sterno-cleido-mastoid. This lamina of fascia is very strong, and by its resistance determines the passage of pus between it and the superficial layer, causing it to point superiorly. The deep cervical fascia in this region covers in the splenius, levator anguli scapulæ, the scalenes, the cervical and brachial plexuses, and the subclavian artery and vein (*vide* "Cervical Fasciæ"). Purulent collections developed between this and the preceding lamina do not point in the axilla; but in the case of abscess dependent on

caries of the lateral portions of the cervical vertebræ, the pus would follow the course of the brachial plexus and pass into the axilla. Immediately behind the vein, internally, is the anterior scalene muscle; and

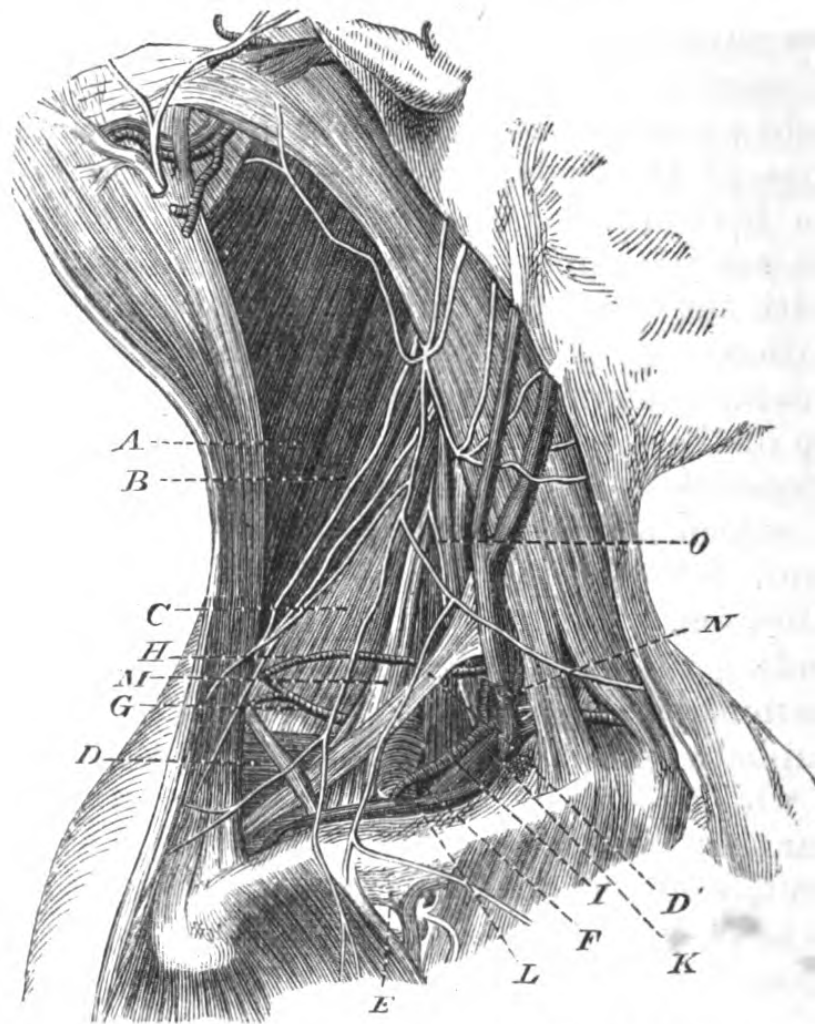


Fig. 19.—Region of the third part of the Subclavian Artery (the shoulder represented depressed).

A, splenius; B, levator anguli scapulæ; C, scalenus posticus; D, first serration of serratus magnus; E, costo-coracoid membrane and cephalic vein; F, subclavian artery; G, transversalis colli artery (deep); H, a more superficial branch; I, supra-scapular artery; K, subclavian vein; L, supra-scapular vein; M, brachial plexus; N, Scalenus anticus; O, phrenic nerve.

emerging from behind this, and meeting the vein at an acute angle in a plane superior to it, is the subclavian artery; and in a plane more posterior, but above, are the cords of the brachial plexus. The anterior scalene

muscle is inserted into a tubercle (*the scalene tubercle*) on the first rib, which is a guide to the vessel, and in front of, and behind the tubercle are grooves on the rib, in which lie, in the anterior, the subclavian vein, and, in the posterior, the subclavian artery, separated from each other by the muscle. The supra-scapular artery, a branch of the subclavian in the first part of its course (normally), with its vein, crosses the main trunk just below the crossing of the omo-hyoid, and lies along the upper border of the clavicle. The transversalis colli artery, also a branch of the main trunk in the first part of its course, lies superior to the artery, but beneath the cervical plexus it passes towards the trapezius, to reach the posterior border of the scapula. These vessels are accompanied by veins, forming a plexus, which lies superficial to the artery, and may cause considerable difficulty in any operation in this region.

The subclavian artery is divided into three portions ; it arises on the right side from the innominata, and on the left from the aorta.

Relations of the subclavian artery in the first part of its course—

The ascending portion—internal to the scalene muscles, rather shorter on the right than the left side, is separated from the sterno-clavicular articulation by the sterno-hyoid and sterno-thyroid muscles, and commencement of the innominata veins—in the right and left side the relations are different :—

On the right side, in front, are the subclavian vein and the vagus, the trunk of the sympathetic and phrenic nerves ; *externally,* the pleura and apex of lung ; *posteriorly,* the transverse process of the seventh cervical vertebra, and the recurrent laryngeal nerve.

On the left side.—The vessel is at first deep, and follows the left side of the vertebral column ; between it and the common carotid lie vagi and phrenic nerves, it next lies on the pleura, and is crossed at right angles by the subclavian vein.

Relations of the subclavian artery in its second portion—

These are the same on both sides; it here lies between the scaleni on the first rib, and has the cords of the brachial plexus above and behind it.

Relations of the subclavian artery in the third part of its course—

In front.—Integument, superficial cervical fascia, platysma, external jugular vein, and the venous plexus before mentioned, descending cervical nerves, subclavius muscle, supra-scapular artery, and clavicle.

Above.—Brachial plexus, and posterior belly of omohyoid muscle.

Below.—First rib covered by the first serration of the serratus magnus.

Behind.—The middle scalene muscle. The arterial branches given off are superior—the vertebral and superior thyroid.

Ligature of the subclavian artery in the third part of its course.—The point selected for placing a ligature upon this vessel is just where it lies on the first rib, at the bottom of the hollow above described. It is not enclosed in a definite sheath like the carotid, but is bound down by a process of the deep cervical fascia, derived from the aponeurotic investment of the omohyoid. The incision is most advantageously made, by drawing the integument down, and cutting upon the clavicle, allowing it to retract afterwards; but this proceeding must be modified by circumstances. When the vessel is reached, just as it emerges from behind the anterior scalene muscle, the needle must be passed round it from *within, outwards*; and the end of the needle must be made to insinuate itself round the vessel closely, so as to avoid the united cord of the eighth cervical and first dorsal nerves, which lie immediately behind it.

The collateral circulation developed after ligature of the third part of the subclavian artery, is as follows:—

As the third portion rarely gives off any branches,

the blood would pass towards the arm by the supra-scapular and posterior scapular branches of the thyroid axis, anastomosing directly with the dorsalis scapulæ of the axillary, on the dorsum scapulæ. The internal mammary trunk of the subclavian anastomoses with the acromio-thoracic, long thoracic, and subscapular, and the superior intercostal with the superior thoracic.

SURGICAL ANATOMY OF THE INNOMINATA.

Although the innominata, anatomically speaking, belongs to the thorax, yet any surgical proceeding in connexion with it would be attempted in the lower part of the carotid region; hence it has been thought advisable to introduce it into the surgical anatomy of the neck.

In the *neck* it, normally, ascends obliquely in the right side to the posterior aspect of the sterno-clavicular articulation, where it divides into the right subclavian and common carotid arteries, and is about an inch, or rather more, in length.

Relations.—From before backwards the structures covering it are—skin, fascia, some fibres of platysma, and descending branches of cervical plexus, sternal origin of sterno-mastoid, a portion of the manubrium sterni, origins of the sterno-hyoid and sterno-thyroid muscles, remains of thymus gland, left innominate, and right inferior thyroid veins, and cardiac branches of vagus.

On its outer side lie the right innominate vein, vagus, and pleura; on its inner, the remains of the thymus gland, and commencement of the left common carotid; and behind it is the trachea. It occasionally divides higher in the neck than at the sterno-clavicular articulation, and may be seen pulsating. Its position must be carefully made out in performing tracheotomy, particularly in children, where the space in which the operation is feasible is very limited, and the structures very close together, besides which the trachea is very small and moveable. It sometimes

gives off a branch to the thyroid body (the thyroidea ima), which might lie immediately over the site of the deep incision in tracheotomy ; and occasionally it gives off thymic and bronchial branches.

Ligature of the innominata.—In order to expose the vessel for the purpose of ligaturing it, it must be drawn out as much as possible from the deep position it occupies, by raising the shoulders and throwing back the head. Next, the sternal origin of the sterno-cleido-mastoid is to be exposed, by an incision along its anterior border, met by one along the upper edge of the sternum ; this tendon is to be divided, and the underlying origins of the sterno-hyoid and thyroid muscles carefully divided. Beneath these muscular fibres is a plexus of veins, chiefly derived from the inferior thyroid, which must be hooked aside. The deep cervical fascia is next to be cautiously scraped through, and the origin of the common carotid exposed, which vessel serves as the guide to the trunk of the innominata. The left innominate vein must be drawn down, whilst the right innominate and internal jugular veins, with the vagus nerve, are drawn outwards. The needle must be passed from *below, upwards and inwards*, taking care that it is kept close to the vessel, to avoid wounding the right pleura or trachea which lie behind it. The ligature should be applied as *high* up as possible. The vessel may be reached by an incision in the mesial line of the jugulo-tracheal space, and this incision should pass immediately in the centre between the sterno-thyroid, and thus divide the dense cervical fascia to which the great veins are intimately attached ; if this be done, the vessel can be isolated from the trachea.

Collateral circulation developed after ligature of the innominata.—The right side of the head and neck would be supplied with blood by the inosculation of the carotids with those of the opposite side ; and the circulation in the right subclavian would be re-established by means of its intercostal branch inoscu-

lating with the first aortic intercostal, assisted by the intercostal arteries, inosculating with the internal mammary, long thoracic, superior thoracic, and acromiothoracic, and by the inosculation between the superior thoracic and deep epigastric.

REGION OF THE NAPE OF THE NECK (POSTERIOR CERVICAL REGION).

This region extends from the occipital tuberosity and superior curved lines above, to the seventh cervical vertebra below, and is bounded laterally by the trapezius. The spinous processes of the three last cervical vertebræ can be felt through the integument, the seventh receiving the name of *vertebra prominens*. The integument is very tough and strong, containing a great deal of fibrous tissue, and not very vascular, and is a favourite seat of abscess or carbuncle; the subcutaneous cellular tissue contains a good deal of fat, and is united to the ligamentum nuchæ, a tough fibro-elastic mass, extending from the occipital tubercle to the seventh cervical vertebra, separating the muscles on either side of the neck. Beneath the aponeuroses lies the trapezius, the aponeurotic attachment of which superiorly is blended with that of the sterno-mastoid; and separating these muscles from the succeeding layer is a dense fascia, continuous with the dorsal aponeurosis, beneath which are found the splenius capitis and the levator anguli scapulæ, the upper portion of the rhomboidei, and serratus posticus superior; next the complexus, the trachelo-mastoid, and transversalis colli. In the fat and cellular tissue beneath this layer are several vessels of importance in the maintenance of the collateral circulation after ligature of the subclavian or carotid arteries—namely, the occipital, vertebral, profunda, and princeps cervicis. The *occipital* enters the region between the splenius capitis and obliquus superior, and lies between the splenius and the complexus, and is afterwards distributed to the scalp

its descending branch, the *princeps cervicis*, which inosculates with the vertebral and the *profunda cervicis* branch of the superior intercostal, passes between the complexus and semi-spinalis colli muscles. The profunda cervicis enters the region by passing backwards between the transverse process of the seventh cervical vertebra and the first rib. The nerves found here are branches of the sub-occipital and the posterior branches of the great occipital, and third and fourth cervical nerves. Beneath the integument are a number of lymphatic ganglia, which become engorged in constitutional syphilis. Beneath the cellulo-fatty layer are the muscles forming the sub-occipital triangle, the recti capitis postici, internally, the obliquus superior and the obliquus inferior, the floor of which triangle contains the curve of the vertebral artery, perforating the posterior occipito-atlantoid ligament, before it takes its course through the foramen magnum; and between this vessel, and the groove in the atlas, is the trunk of the sub-occipital nerve.

VERTEBRAL COLUMN IN THE CERVICAL REGION.

Owing to the curvature of the cervical spine, the prominence of the second and third cervical vertebræ in the pharyngeal cavity can be readily recognized from the mouth by palpation.

The cervical spine is liable to dislocation from the great mobility of the articulations, and, from the fact that the articular surfaces are nearly horizontal, dislocation without fracture may take place. In the space between the first cervical vertebra and the occiput the cord may be readily reached by a mere puncture—a fact which should not be forgotten by the medical legist. An injury to the cord above the third would implicate the phrenic nerve and paralyse the diaphragm, and give rise to sudden asphyxia, causing instantaneous death.

If the lower portion of the cervical cord be divided there will be paralysis both of the upper and lower

extremities, and the respiration would be entirely carried on by the diaphragm. If the injury be opposite the sixth cervical vertebra, there would be only partial paralysis of the upper extremity, owing to that portion of the brachial plexus given off from the cord above this spot being unimplicated.

The cervical spine is occasionally the seat of *spina bifida*, an arrest of development in which the spinous processes or the laminae are absent or separated, allowing of the bulging of the meninges beneath the integuments. In *spina bifida* in this region, the spinal cord and its nerves are generally adherent to the parietes of the tumour. (For course taken by pus in spinal caries, *vide* "Fasciæ of Neck.")

CHAPTER III.

SURGICAL ANATOMY OF THE THORAX.*

THE applied anatomy of the thorax is rather the province of the physician than that of the surgeon, yet at the same time there is so much in common with regard to physical examination, that it will be advisable to devote some little space to the subject.

In the region of the thorax it is intended to include that portion of the body comprising the parietes of the chest, which contains the heart, lungs, and the contents of the posterior mediastina. The interior is bounded, *superiorly*, by the superior aperture of the thorax (that is to say, the bony ring formed, behind, by the body of the first dorsal vertebra; on either side, by the first ribs; and anteriorly, by the upper part of the manubrium sterni); *anteriorly*, by the sternum; *posteriorly*, by the vertebræ; *inferiorly*, by the diaphragm; and *laterally*, by the ribs and intercostal muscles, above the limit of the diaphragm, to the exclusion of such structures as are regarded as belonging to the upper extremity—namely, those entering into the formation of the axilla, which region will be hereafter described.

The general form of the thorax is that of an inverted cone. It is flattened from before backwards, so that it presents in section an ellipse, whose greater axis is transverse; in the child, however, this section

* For the intimate relations of the contents of the thorax, the student is referred to Braune's "Atlas of Topographical Anatomy." (Translated by Author.)

is almost circular. After the removal of the upper extremities, it takes the form of a right cone. The cavity enclosed by these limits is not of the same dimensions as that of the cavity contained merely within the bony limits, since the diaphragm represents an arch, mounting up as high as the fifth rib in front, so that some of the abdominal viscera (liver, stomach, spleen, transverse colon, pancreas, and duodenum) are hidden by the thorax. Hence the thorax and abdomen are so reciprocally united, that any instrument which traversed the thorax at its inferior part would, of necessity, penetrate both cavities.

The relation of the *structures passing through the superior aperture of the thorax* would seem to form a suitable connexion between the regions of the thorax and neck. Supposing a section be made, following a plane passing through the upper part of the first dorsal vertebra behind, the upper borders of the first ribs laterally, and the manubrium sterni anteriorly, the following structures would be seen passing from before backwards, between the apices of the lungs. In the middle line are the origins of the sterno-hyoid and sterno-thyroid muscles, and a lax cellular tissue, in which are the remains of the thymus gland, the inferior thyroid veins, the trachea, œsophagus; and, in the groove separating them, the recurrent laryngeal nerves; and on the left side the thoracic duct. At the sides the internal mammary vessels, the innominate veins, and on the right the innominate artery, with the vagus nerve lying between it and the innominate vein, and on the left the common carotid and subclavian arteries, with the vagus between them, the phrenic and cardiac nerves, the trunk of the sympathetic, the longi colli muscles, and the superior intercostal arteries and first dorsal nerves.

Auscultation and percussion.—Before going into any details of structure it would seem advisable to point out the relations of the contents of the thorax to the walls of the chest—such, in fact, as relate to the auscul-

tation or percussion of the lungs, heart, and great vessels. As, however, these matters are to be found in works specially devoted to the subject, it is proposed merely to point out the chief anatomical bearings of the contained viscera.

Position of the lungs with regard to the surface.— Presuming the body to be normal, their position with regard to the thoracic walls is as follows: The *apices*

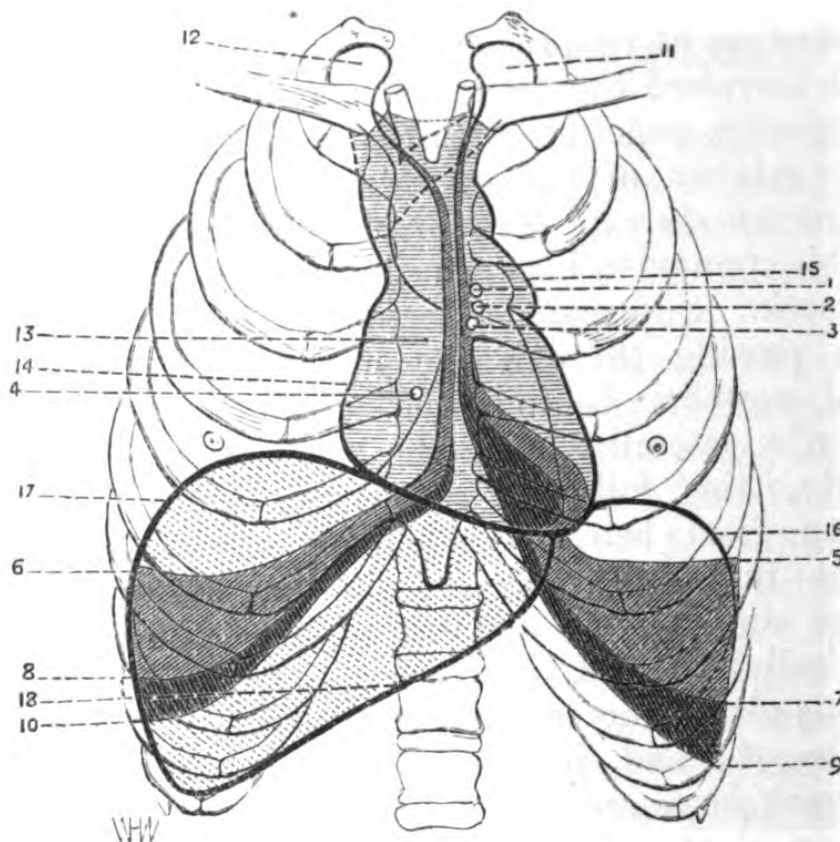


Fig. 20.—Diagram of the relations of the Thoracic Viscera to the Walls of the Chest.

- 1, situation of pulmonary orifice; 2, left auriculo-ventricular orifice; 3, orifice of aorta; 4, right auriculo-ventricular orifice; 5, limit of the anterior and inferior border of left lung in complete expiration; 6, ditto of right lung; 7, limit of left lung in inspiration; 8, ditto of right lung in inspiration; 9, limit of pleura; 10, ditto; 11, superior cul-de-sac of left lung; 12, ditto of right lung; 13, right auricle; 14, right auricular appendage; 15, left auricle; 16, limit of diaphragm in complete expiration; 17, ditto, ditto; 18, ditto, ditto, in complete inspiration.

lie beneath the scalenus anticus muscle and the subclavian artery, separated by the œsophagus, trachea,

and anterior portion of the bodies of the first and second dorsal vertebræ. The *bases* of each are separated from the abdominal viscera by the diaphragm, that of the right being considerably hollowed out by the bulging upwards of the liver, as far up in the thorax as the fifth rib; that of the left is hollowed out to a less degree by the projection of the stomach, spleen, and left lobe of liver.

The inner margin of the right lung passes vertically down the middle of the sternum, with a slight inclination to the same side, as far as the sterno-xiphoid articulation.

The inner margin of the left lung lies parallel with that of the right, about as far as to the fourth costal cartilage, where it passes outwards along this cartilage for a short distance, and then descends obliquely downwards and backwards, a little internal to the nipple, nearly as far as the seventh rib.

Position of the heart with regard to the surface.—The heart lies obliquely, and during expiration is nearly horizontal, its base being to the right and apex to the left side. The base corresponds to the interval between the fifth and eighth dorsal vertebræ, and its apex to a little below the left fifth rib, to the left of its junction with its cartilage, while the *impulse* is to be felt in the interspace between the cartilages of the fifth and sixth ribs, internal to the nipple. Its upper border corresponds to a line on a level with the upper borders of the third costal cartilages, and its lower border to a line extending between the articulation of the ensiform with the costal cartilage on the right side, to the position of the apex. Hence, for auscultation of the base, the spot is the upper border of the third costal cartilage, and for the apex, a point about two inches below the nipple, and one inch towards the middle line of the body.

Position of the great vessels with regard to the surface.—The *right auriculo-ventricular* opening is behind the centre of the sternum, on a line with the lower margin

of the articulation of the cartilage of the fourth rib with it. The *left auriculo-ventricular* opening is about three-quarters of an inch lower than the pulmonary orifice.

The *orifice of the pulmonary artery* is on a line with the space between the junction of the second and third costal cartilages with the sternum, being to the left and close to that bone.

The *orifice of the aorta* is at the commencement of the ascending portion of the arch, and is on a line with the junction of the third costal cartilage of the left side with the sternum. The *arch* attains the level of the upper border of the second costal cartilage of the right side at its junction with the sternum. (*Note.*—These relations vary slightly in the works of some authors, but those mentioned above will be found correct for practical purposes.)

WALLS OF THORAX.

The region of the walls of the thorax may be conveniently described surgically, as *sternal*, *costal*, *diaphragmatic*, and *spinal*.

The *sternal* region consists of the sternum itself, the chondro-sternal articulations, and of the structures which immediately cover them—viz, integument, subcutaneous cellular tissue, aponeurosis of pectoralis major, sterno-mastoid, rectus abdominis, and occasionally fibres of the rectus sternalis muscles.

It is surgically of importance, as being the seat of fractures, of dislocations of the clavicle from it, of necrosis and caries, or of gummata. The mechanism of the sterno-clavicular articulation, which possesses an inter-articular fibro-cartilage and two synovial membranes, allows of motion in almost all directions, and largely assists in the free play of the shoulder. The peculiarity in the construction and the curved form of the clavicle, serve to break the effect of shocks or blows upon the shoulder or upper limb. *On the right side* the sterno-

clavicular articulation is immediately in front of the innominate artery and subclavian vein, whilst on the *left* it is in relation with the left subclavian vein and the interspace between the left common carotid and subclavian arteries; the inter-clavicular space lies immediately in front of the trachea. Posteriorly and below, the sternum is covered by the triangularis sterni muscles, and laterally is in relation with the internal mammary vessels. The sternum is liable to fractures, and dislocations from it of the clavicle—an accident which may occur in any direction but downwards, owing to its close relation with the cartilage of the first rib (*vide* “Region of Clavicle”).

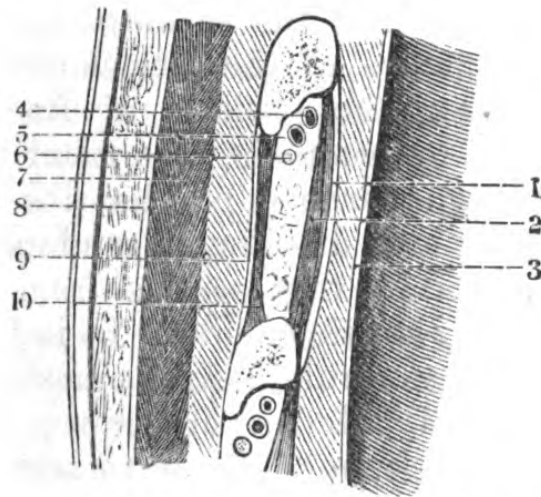


Fig. 21.—Section of sixth Right Intercostal Space, at the junction of the anterior and posterior thirds.

- 1, aponeurosis covering the internal intercostal muscle; 2, internal intercostal muscle; 3, pleura; 4, intercostal vein; 5, intercostal artery; 6, intercostal nerve; 7, serratus magnus; 8, its aponeurosis; 9, aponeurosis covering external intercostal muscle; 10, external intercostal muscle.

The costal region, which is bounded anteriorly by the sternum, laterally by the sides of the bodies of the ribs, and inferiorly by the diaphragm, presents several points of surgical importance, since it contains the mammary gland, the ribs, and the intercostal spaces. It is covered in anteriorly and posteriorly above by structures belonging to the region of the upper

extremity, in front by the greater and lesser pectoral muscles with their aponeuroses, and behind by the scapula and the muscles attached to it and between the external borders of the scapular and pectoral muscles, the ribs and the humerus is a special region—the axilla.

The ribs.—The direction of the ribs is oblique from above downwards, and from behind forwards, so that their posterior extremity is considerably higher than the anterior, and a knowledge of the relation of the ribs to a horizontal plane passing through the body is often of use—thus, the first in front corresponds with the fourth behind, the second to the sixth, the third to the seventh, the fourth to the eighth, the fifth to the ninth, the sixth to the tenth, the seventh to the eleventh. Owing to the nature of the articulation of the ribs with the sternum, the position of fracture may be readily made out by percussing the latter bone.

The close neighbourhood of the ribs to the lungs and pleura, liver and diaphragm, renders fractures by direct violence often very serious from puncture of these structures by the fragments. In indirect violence the rib is broken, as a rule, near the angle, and wounds of the intercostal arteries are rare; these vessels are, from their position, difficult to secure.

The *intercostal spaces* vary considerably in extent: thus they are wider during inspiration; the most remarkable variation in the interspace is at its middle, as here, during expiration, the ribs occasionally approximate so closely that their edges are in absolute contact.

The operation of *paracentesis thoracis* or tapping the thorax, in pleurisy, emphysema, or the pointing of an hepatic abscess, is usually performed between the fifth and sixth ribs, just behind their middle, and *never* behind the angle, because of the size of the intercostal arteries at this point, and moreover on account of the thickness of the layers of muscle. Some prefer a point situated an inch or more below the angle of the

scapula, between the seventh and eighth, or eighth and ninth ribs, the instrument being passed just above the *upper* border of the rib, so that the intercostal vessels may be avoided. On the right side, it is advised to puncture through an interspace higher, on account of the position of the liver and diaphragm on that side.

Each intercostal artery is accompanied by a vein and nerve, the nerve being superior to the artery in the upper intercostal spaces, but below it after the fourth or sixth space. They are protected from pressure, whilst the intercostal muscles are acting, by being enclosed in tendinous bands which are attached to the ribs.

The internal mammary artery belongs properly to the cavity of the chest, lying on the left side in the anterior mediastinum, whilst on the right it is so overlapped by the lung as to be excluded from the space. It lies behind the cartilages of the ribs and the sternum, upon the pleura, and at a short distance from the margin of the sternum. It is given off from the subclavian opposite the vertebral, and passes into the thorax in relation with the phrenic nerve, which crosses it anteriorly and then descends internal to it. Two veins, which usually unite to form a common trunk, accompany it. In the upper part of the chest it is covered in by the costal cartilages and internal intercostals, whilst below it lies between the triangularis sterni and the pleura. Its chief inosculating branches are given off at the interval between the sixth and seventh cartilages, they are *musculo-phrenic* and *superior epigastric*.

Wounds of this vessel, especially if situated where it has any bulk, *i.e.*, between the first and seventh ribs, are serious. It can be *tied* easily in the *first three* intercostal spaces, by making an oblique incision about two inches long from without inwards, and at about three or four lines from the border of the sternum, and the *structures divided in reaching it* are—

integument, cellular tissue, origin of pectoralis major, internal intercostal muscle. Owing to its free anastomoses, of course both ends of the wounded vessel require ligature.

MAMMARY REGION.

This region presents for examination the skin, the subcutaneous layer of fat, the mammary gland itself, a cellular layer, the aponeurosis of the pectoralis major, the pectoralis major itself, the ribs, and intercostal spaces.

The skin varies in thickness according to its locality, excepting over the nipple and areola it presents no peculiarity. The areola is pink in virgins, and becomes brown during and after childbirth; it contains some twenty or thirty tubercles formed by groups of sebaceous follicles; whilst the skin which covers the gland is very freely moveable over it, the skin of the areola is very adherent and immoveable, and there is no fat beneath it.

The subcutaneous fatty layer gives the characteristic form to the breast, and sends processes between the lobules of the gland.

The mammary gland is situated in front of the pectoralis major, towards the lateral aspect of the region of the chest, and corresponds to the interval between the third and seventh ribs (the *male* nipple lies on the fourth rib). It is a racemose gland, and is intimately associated with the generative functions. It is composed of a certain number of independent lobes, the lobules of which open into the lactiferous ducts, which uniting form larger ones, terminating in an excretory duct; these ducts are generally from fifteen to twenty in number, and converge towards the areola, and beneath the nipple become dilated into sinuses, before perforating its summit by separate orifices. A large number of muscular fibres exist in the nipple, to which is due its erectile property.

The cellulo-fatty layer beneath the gland separates it from the aponeurosis of the pectoralis major, and gives it its peculiar mobility. It is occasionally the seat of abscess known as retro-mammary; the pus usually points at the anterior fold of the axilla.

The breast is freely supplied with vessels, the arteries being derived from the internal mammary, the axillary, and the intercostals; the veins are both superficial and deep—the superficial are seen beneath the subcutaneous cellular tissue and are very much distended during pregnancy, whilst the deeper ones follow the course generally of the arteries. An anastomotic circle of veins is seen around the base of the nipple. The lymphatics are also arranged as superficial and deep: the former are immediately beneath the integument and pass into the axillary glands; the latter set accompany the galactiferous tubes, and pass into the cellular tissue beneath the gland, also to join the glands in the axilla and the intra-thoracic ganglia. The nerves are derived from the intercostals.

The breast is the seat of many forms of tumours which necessitate its removal, and its great vascularity may give rise to severe hæmorrhage during such operations; it is advisable therefore in such cases to make the *inferior* incision first, to avoid, if possible, any complication, owing to the parts being obscured by blood.

Mammary abscesses ought to be opened *vertically* (to avoid “pocketing” and the formation of sinuses), freely and deeply, to insure the exit of all matter. Moreover, these incisions should, if possible, be made parallel to the course of the galactiferous ducts, if near the nipple, in order to avoid cutting across them.

The diaphragmatic region, constituting the floor of the thorax, is formed by the diaphragm which constitutes the septum between the thoracic and abdominal viscera, and is the muscle of normal respiration. Its height, or the amount of encroachment upon the thorax

during ordinary respiration, depends in some measure upon the amount of distension and the size of those abdominal viscera in immediate relation with it—viz., the stomach, intestines, and the liver. During *normal expiration* the right arch ascends to the level of the *fifth* rib. *Forced expiration* brings the right arch of the muscle—that above the liver—to a level with the fourth costal cartilage in front, with the fifth, sixth, and seventh ribs at the side, and with the eighth rib behind. The left arch is lower than the right by two ribs. During *forced inspiration* the muscle descends to the level of a line extending from the ensiform cartilage to the level of the tenth rib.

The under surface of the diaphragm is perforated by three large foramina:—(1) The aortic, situate between the pillars of the muscle and spinal column, transmits the aorta, the thoracic duct, and the vena azygos major. (2) The caval, quadrilateral in shape and incapable of constriction, transmits the inferior vena cava. (3) The œsophageal, elliptiform and capable of constriction, transmits the œsophagus, also the vagi nerves, the left being in front. On either side of the attachment of the diaphragm to the xiphoid cartilage is a space where the muscular tissue is wanting, so that between the abdominal cavity and that of the anterior mediastinum there is a communication, filled in by a little cellular tissue; through which pass some lymphatics from the liver, and occasionally a diaphragmatic hernia. (The relations of the pleuræ and peritoneum to the diaphragm will be considered later on.)

Collections of pus forming in the thoracic cavity may find their way through these spaces; moreover, as the diaphragm separates the right lung from the liver, abscesses forming in this latter viscus may either be discharged by the bronchi or into the thoracic cavity.

Penetrating wounds of the diaphragm are very serious, partly on account of hæmorrhage, and partly

from the fact that the viscera, both of the thoracic and abdominal cavities, may be implicated; and partly on account of the intimate connexion with it of large serous cavities, the pleuræ, the peritoneum, and the pericardium.

Occasionally *paralysis* of the diaphragm occurs with ascites, or may be owing to a wound in the neck or spinal column, implicating the phrenic nerve.

An approximation of the course taken by a bullet or a weapon penetrating the walls of the thorax from its anterior or lateral aspects, may be gathered from the following facts:—That the *heart* would be reached by a wound traversing the chest at right angles, above the sixth rib, and that its apex lies about an inch and a half from the surface. Wounds in the mesial line would involve the heart and great vessels, whilst more laterally they would implicate the lungs; the position of the trunk and branches of the internal mammary artery renders penetrating wounds of the intercostal spaces near the sternum very serious.

A wound penetrating the sternum, on a line with the nipples, and striking upon the vertebra at right angles with the axis of the body, would traverse three cavities of the heart, two ventricles, and the left auricle.

If an instrument traversed any of the lower intercostal spaces during inspiration, it would wound the base of the lung, the diaphragm, and corresponding abdominal viscera, but during expiration would avoid the lung.

Spinal region of thorax.—The posterior wall of the thorax is formed by the dorsal spine and its coverings, and is represented by a region bounded superiorly by the last cervical, and inferiorly by the first lumbar vertebra, and laterally by the angles of the ribs.

The integument is very thick and dense, and contains a quantity of sebaceous follicles; the subcutaneous cellular tissue is intimately united to the spinous processes of the dorsal vertebræ (which can be plainly felt

throughout the region), thus preventing fluid infiltrating or pus appearing superficially, except along the sides of these processes. The dorsal aponeurosis invests the anterior and posterior surfaces of the trapezius and latissimus dorsi, uniting superiorly with the cervical, and inferiorly with the lumbar aponeurosis, splitting to enclose the serrati postici; it is attached to the spinous processes of the dorsal vertebræ and tubercles of the ribs, enclosing all the muscles of the back, and separating the superficial from the deep layer. The first layer of muscles consists of the lower part of the trapezius and the latissimus dorsi, the former overlapping the latter. Beneath these muscles lie the rhomboidei and serrati postici. The deep layer consists of the sacro-lumbalis internally with its accessory muscles, and the longissimus dorsi externally also with its accessory muscles; between them superiorly, the lower portions of the splenius colli, complexus, and transversalis colli; deepest of all, the transverso-spinales and levatores costarum.

A small triangular space uncovered by muscle exists at the point where the trapezius and latissimus dorsi diverge. The space is bounded by the two muscles just named towards the spine, whilst externally it is completed by the inferior angle and vertical border of the scapula. From the fact of its being uncovered by muscle it is available for auscultation.

The *vessels* met with are dorsal branches from the intercostals and the posterior scapular, and the *nerves* are the dorsal branches of the spinal, with some few branches from the cervical plexus and spinal accessory.

Vertebral column in the dorsal region.—With regard to the skeleton of this region, the arrangement of the dorsal vertebræ renders simple dislocation almost impossible, and when displacement does occur it would seem to be invariably associated with fracture of some portion of the spinal column. The spinous processes, from their position, are often fractured.

The dorsal spine is very often the seat of caries, or disease of the intervertebral substances, inducing angular curvature and paralysis of the lower limbs from pressure on the cord.

In abscesses connected with caries of the transverse processes, or laminae of the dorsal vertebræ, the pus, in consequence of the strong fascial lamina between the superficial and deep muscles, instead of passing towards the surface, gravitates into the inferior portion of the region, and occasionally extends into the axilla.

When the disease consists in caries of the bodies of the vertebræ and abscesses form, the course taken by the pus will depend upon the part of the spine which is the seat of disease; it generally escapes between the pillars of the diaphragm, and passes beneath the fascia, along the side of the aorta and iliac arteries, pointing in the abdominal parietes, *above* Poupart's ligament. If the abscess depends upon disease of the lower dorsal vertebræ, the pus is directed forwards by the sheath of the psoas muscle, and points *below* Poupart's ligament, in the front of the thigh and external to the vessels. The pus sometimes passes backwards, forming dorsal abscess. If it gets into the subperitoneal areolar tissue in the pelvis, it may find its way into the perineum by the side of the rectum, or pass out of the great sciatic notch, and appear in the region of the great trochanter.

Injuries to the cord in the dorsal region, if below the second dorsal vertebra, do not affect the upper extremity, but the respiration is greatly affected, owing to implication of the nerves supplying the intercostals and abdominal muscles; moreover, there is paralysis of all the parts supplied by the nerves below the seat of injury.

CAVITY OF THE THORAX.

As this region can scarcely be considered as within the province of *surgical* anatomy, at all events in so limited a work as the present, it is proposed therefore to allude to it as shortly as possible. Its practical bearings to the surgeon seem rather to depend upon the relations of the contents to the parietes, which have been already discussed, both as far as physical diagnosis and injury are concerned; and considerations with respect to aneurism of the aorta or its great trunks are subjects rather for systematic surgery. Since operative proceedings on the œsophagus, trachea, or great vessels are instituted in the neck, the chief anatomical bearings of these structures will be found described in the chapter on the Surgical Anatomy of the Neck.

The cavity of the thorax is most conveniently described for reference as divisible into two pleural cavities, separated in the lower four-fifths of the chest, by the three mediastina, and in the upper fifth by the great vessels springing from the arch of the aorta, a region called by Professor Wood, the *cervico-thoracic*. The posterior wall of this division, he makes the three upper dorsal vertebræ and their intervertebral substances, and the intervertebral substance between the third and fourth the anterior—the manubrium sterni, and upper fourth or fifth of the anterior mediastinum; on either side the apices of the lungs and pleuræ.

The *anterior mediastinum* is bounded as follows:—Anteriorly, by the sternum and left costal cartilages; posteriorly, by the pericardium, for the lower three-fourths or four-fifths, and for the rest, by the cervico-thoracic region; laterally, by the pleura. The *middle mediastinum* contains the heart and ascending portion of the aorta and arch, phrenic nerves and vessels, and is limited behind by the fibrous pericardium and the obliterated ductus arteriosus.* The *posterior mediastinum*

* *Vide* Professor Wood, F.R.S., on Relations of Aorta: "Journal of Anatomy and Physiology," vol. iii.

is limited above by the left portion of the arch, below by the lesser muscle of the diaphragm ; laterally, pleural cavities, roots of lungs, and ligamenta lata pulmonum.

It contains the bifurcation of the trachea and the bronchi, vagi, œsophagus, hinder part of root of lung, and recurrent laryngeal nerve of left side, descending aorta, azygos major vein, thoracic duct, and great splanchnic nerves.

CHAPTER IV.

SURGICAL ANATOMY OF THE UPPER EXTREMITY.

REGION OF THE SHOULDER.

Surface markings.—The convexity of the shoulder is due to the deltoid muscle, and the globular head of the humerus. The bony processes, the coracoid, acromion, spine of scapula, globular head of humerus, and the entire extent of the clavicle, can be readily felt, and their exact relation with regard to each other should be noticed and compared, and their respective bearings with the other bony prominences of the upper extremity carefully studied, both at rest and in action. The precise relations of these *surface* markings are of the utmost importance in the diagnosis of fracture, dislocation, or other injury to the shoulder-joint, and moreover, they serve as guides for the direction of the knife in amputations or excisions. When the arm hangs along the side with the palm turned forwards, externally, the acromion, epicondyle, and styloid process of radius corresponds, and internally, the head of humerus, epitrochlea, and styloid process of ulna.

Anterior and lateral aspects of the shoulder.—*Anteriorly*, immediately below the clavicle, is a fossa, in which the pulsations of the first part of the axillary artery can be felt, and which hollow may be obliterated by the presence of axillary tumours or dislocation of the humerus forwards.

Externally, the roundness of the shoulder is formed

by the deltoid muscle, beneath which, and below the overhanging process of the acromion, can be felt the globular head of the humerus. This portion of the bone is sometimes very large in proportion to the articulation, and might be mistaken for a displacement. In any dislocation, however, the rotundity of the shoulder gives place to a characteristic flattening; and there is impairment of the movements of the joint. Along the anterior border of the deltoid is a groove between it and the upper fibres of the pectoralis major, in which lie the cephalic vein and a branch of the acromio-thoracic artery. The skin of this region is very thick, and glides easily over the underlying tissues, owing to the presence of bursæ, which are in some individuals more or less developed, according to the use made of the shoulder by their occupation or work—thus, by carrying a ladder or a hod of mortar, etc.

CLAVICULAR REGION.

The scapulo-clavicular articulation, often distinct through the slight prominence of the clavicle upon the acromion, forms the tip of the shoulder.

This elevation of the external extremity of the clavicle, if very much marked, may be mistaken for a dislocation.

To the upper border of the clavicle is seen the attachment along its sternal portion of the outer fibres of the sterno-cleido-mastoid, and along its acromial portion the anterior fibres of the trapezius.

Below are the attachments of the pectoralis major internally, and externally the deltoid.

The *clavicle* can be felt in its whole extent, owing to its subcutaneous position, and from being so exposed is liable to fracture. Again, its structure, its curves, which intensify the shocks of indirect violence, and the want of support posteriorly, all contribute towards the frequency of the accident.

If this fracture takes place at its centre, the displacement of the outer fragment downwards, forwards, and inwards, is due to the weight of the arm, and to the action of the deltoid, pectoralis major, and subclavius. The inner fragment is occasionally tilted upwards, but only when the clavicular fibres of the sterno-cleido-mastoid are in action, as in rotation of the neck, the strong ligamentous attachment to the rib (costo-clavicular), and perhaps the clavicular fibres of the pectoralis major, retaining it in place. The slightness of the displacement on fracture of the acromial and sternal extremities is also due to their strong ligamentous attachment. The clavicle is separated from the upper part of the axilla and its contents by the subclavius muscle and its aponeurosis; behind its sternal extremity is the junction of the internal jugular vein and subclavian vein running closely along it; behind its upper border are the supra-scapular vessels, which are liable to be injured in fracture of the bone or operations upon it.

The internal extremity of the clavicle articulates with the sternum by a saddle-shaped joint, possessing an inter-articular fibro-cartilage, attached above to the clavicle, and below to the sternum and two synovial membranes, the office of the cartilage being to break shock between the two surfaces. Moreover, this extremity of the collar bone articulates with the first rib. Notwithstanding the powerful ligaments between these points, the clavicle is liable to dislocation anteriorly, posteriorly, and superiorly.

With regard to the acromio-clavicular articulation, it possesses very slight movement, but is often the seat of dislocation, which occurs after a severe fall on the shoulder, the supra-acromial form being the most frequent, and, if complete, the coraco-clavicular ligaments are generally torn.

It is worth recollecting that the inter-articular space is situated exactly in the course of a vertical line, passing through the middle of the anterior aspect of

the upper arm; this is useful in diagnosing the nature of injuries affecting the shoulder.

External aspect of the shoulder, or deltoid region.—The deltoid muscle forms the external boundary of the region of the shoulder. The subcutaneous tissue contains the terminal twigs of the acromial branches of the descending clavicular nerves, and of the cutaneous

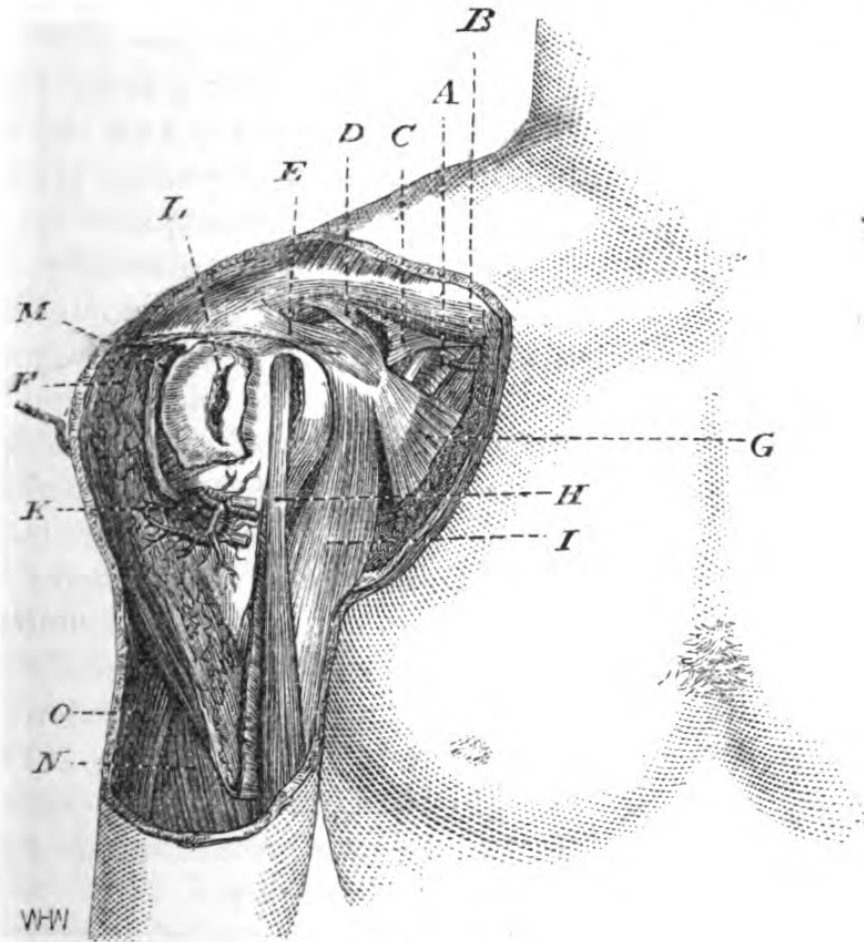


Fig. 22.

A, axillary artery; B, axillary vein; C, costo-coracoid membrane; D, coracoid process; E, coraco-acromial ligament; F, deltoid cut and pulled back; G, pectoralis minor; H, long head of biceps; I, short head of biceps and coraco-brachialis; K, circumflex vessels and nerve; L, head of humerus seen through capsule, upon which is a portion of the bursa between it and the deltoid; M, posterior portion of this bursa between the deltoid and scapular muscles; N, brachialis anticus; O, triceps.

branches of the circumflex nerve and artery. The aponeurosis of the deltoid completely covers the

muscle, and is continuous with that of the upper arm and axilla, sending down septa between the bundles of the muscular fibres, and passing beneath it, is continuous with the deep fascia. The deltoid itself, arising from the outer half of the clavicle and the lower border of the spine of the scapula, after the convergence and interlacement of its fibres, is inserted into the roughened surface on the outer aspect of the humerus.

Immediately beneath this muscle is a large bursa, often multilocular, which lies between it and the convex head of the humerus and the acromion process; the insertions of the supra- and infra-spinatus, and teres minor muscles into the greater tuberosity, and passing round the surgical neck, the posterior circumflex vessels and circumflex nerve; the bicipital groove, in which lie the long head of the biceps and the anterior circumflex artery; the coracoid process, with the short head of the biceps and coraco-brachialis attached to it, a quantity of loose cellular tissue, and the capsular ligament. Severe blows upon the shoulder frequently cause effusion into the bursa above named, and render diagnosis of the precise injury extremely difficult, and suppuration in its cavity may be mistaken for disease of the articulation. In the case of effusion of blood into the cavity, the posterior border of the axilla will become discoloured a few days after the injury.

Posterior aspect of the shoulder, or scapular region.—The spine of the scapula is seen directly beneath the skin, as a furrow in muscular persons, and as a prominent ridge in emaciated subjects, terminating in its broad acromion process, which overhangs the articulation. Above and below the spine are the supra- and infra-spinous fossæ, filled in by muscle, the superior fuller than the inferior, owing to the attachment of the trapezius along the upper border of the spine. The inferior angle of the scapula is just beneath the surface, having sometimes fibres of the latissimus dorsi

attached to it, which muscle, as it sweeps forward towards the arm, forms the posterior border of the axilla; occasionally the scapula becomes dislocated over the upper edge of this muscle, or rather the muscle slips beneath the scapula.

The supra-spinous fossa contains the supra-spinatus muscle, between which and the bone lie the supra-scapular vessels and nerve, the nerve passing below the supra-scapular ligament and the vessels over it; these vessels, after supplying the supra-spinatus muscle and the nerve, wind round the root of the acromion into the infra-spinous fossa, and there the important inosculation takes place between the dorsalis scapulae and posterior scapular, which becomes greatly developed after ligature of the subclavian in the third part of its course, playing a chief part in the maintenance of the collateral circulation for the supply of the arm. In front of the scapula, between it and the ribs, is the subscapularis, a multi-penniform muscle, the full development of which gives such an appearance of depth to the thorax in muscular persons. Beneath the tendons of the muscles inserted into the greater and lesser tuberosities are large bursæ, occasionally communicating with that beneath the deltoid, and with the synovial sac of the shoulder-joint; inflammation or suppuration of which may be mistaken for glandular inflammation or for axillary aneurism.

The bursa between the latissimus and the scapula sometimes develops enormously, passing below the lower border of that bone, and extending upwards beneath the subscapular muscle, or between it and the bone. A point of value in diagnosis of tumours of this kind is to put the latissimus dorsi in action opposing it, by placing the back of the hand in the small of the back.*

* In a case in the author's practice an enlarged bursa in this region, had been supposed to be a rapidly-growing neoplasia, and this dorsal rotation of the arm was invaluable in establishing the diagnosis.

Articulation of the shoulder-joint.—The ellipsoidal articular extremity of the humerus is very large in comparison with the glenoid cavity, which is ovoid in shape, larger below than above; and it is surgically of importance to note that not only are the articular surfaces of the humerus and scapula here in contact, but that the head of the bone is in immediate relation with the arch formed by the coracoid and acromion processes and the coraco-acromial ligaments—an approximation which is due to the action of the deltoid, in *atrophy* of which muscle there is a considerable interspace between these points. The capsule of the

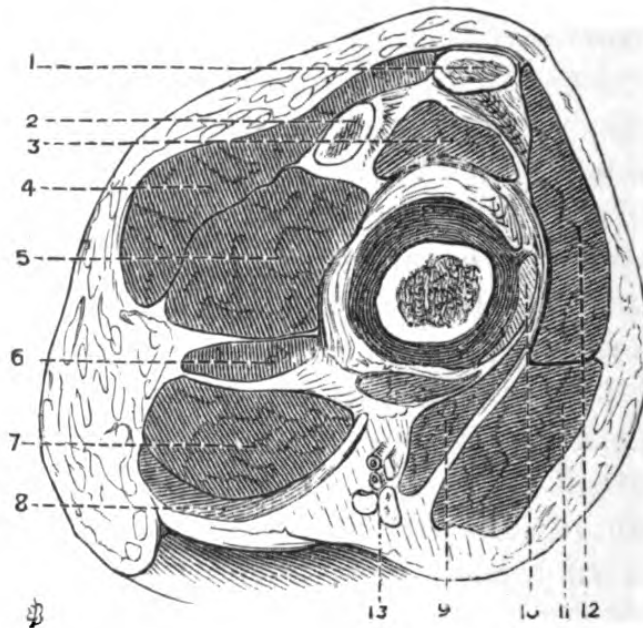


Fig. 23.—Transverse Section through Right Shoulder-joint, showing structures in contact with it.

1, clavicle; 2, acromion; 3, supra-spinatus; 4, trapezius; 5, infra-spinatus; 6, teres minor; 7, teres major; 8, latissimus dorsi; 9, coraco-brachialis and short head of biceps; 10, tendon of subscapularis blended with the capsular ligament; 11, pectoralis major; 12, deltoid; 13, axillary vessels and nerves.

joint is materially strengthened by fibrous expansion from the tendons of those muscles which are in *immediate* contact with the articulation—viz., the supra- and infra-spinati, teres minor, subscapularis, and long head of biceps and triceps, and by bands passing from

the coracoid process. The synovial membrane lining the capsule is prolonged beneath the subscapularis muscle, and into the bicipital groove.

The movements of which the humerus is capable in the glenoid cavity are very varied, and, with a view to studying the action of the muscles in dislocation and fracture of this bone, and in their diagnosis, may be classified as follows: The humerus is *raised* by the deltoid, supra-spinatus, long head of biceps, and coraco-brachialis; *depressed* by the pectoralis major, latissimus dorsi, teres major, and subscapularis; *brought forward* by the pectoralis major, anterior fibres of deltoid, coraco-brachialis, and short head of biceps; *drawn backwards* by the latissimus dorsi, teres major, long head of triceps, posterior fibres of deltoid, supra-spinatus, and teres minor; *rotated inwards* by subscapularis, teres major, latissimus dorsi, pectoralis major, and anterior fibres of deltoid; *rotated outwards* by the infra-spinatus, teres minor, coraco-brachialis, and posterior fibres of deltoid.

The great power of all these muscles upon this joint, which owes its great extent of motion to the shallow glenoid cavity and large head of humerus, and the laxity of its capsule, favours dislocation under certain circumstances; and were it not for the bony arch formed by the coracoid and acromion processes, and the ligament between them, the long head of the biceps passing through the capsule over the head of the bone and blending with the glenoid ligament, and the mobility of the scapula, such accidents would be still more frequent.

The anatomical position of the head of the humerus with regard to the neighbouring bony structures after its dislocation may be generalized thus—*sub-glenoid, sub-clavicular, sub-coracoid, sub-spinous*.

In the condition termed *sub-glenoid*, the head of the humerus rests on the inferior border of the scapula, below the glenoid cavity, between the subscapularis and long head of triceps; and the peculiar numbness

in the hand and arm, and frequent coldness and œdema in the limb, are due to pressure upon the brachial plexus and axillary vessels. In the *sub-clavicular* variety, the head of the bone lies below the clavicle, internal to the coracoid process, upon the second and third ribs; and beneath the pectoral muscles. In the *sub-coracoid*, the head of the bone lies deeply in the upper and inner part of the axilla, below the coraco-brachialis and pectoralis muscles. In the *sub-spinous* form, the head of the bone lies behind the glenoid cavity, below the spine, and between the infra-spinatus and teres minor muscles. These may be regarded as the *complete* forms, which are, of course, liable to modifications.

That portion of the bone belonging to the region of the shoulder—that is to say, as low down as the insertion of the deltoid—is liable to fracture of the anatomical neck, which is *intra-capsular*, and to fracture of the surgical neck, which is *extra-capsular*. In the former there is little or no displacement due to muscular action; in the latter case the upper fragment is abducted slightly by the supra- and infra-spinatus, teres minor, and subscapularis; the lower fragment is drawn inwards by the pectoralis major, latissimus dorsi, and teres major, whilst the deltoid draws it obliquely from the side of the body.

In cases of fracture of the anatomical neck, with separation, it may necrose, owing to there being no means of vascular supply to the fragment, and if not, it may be inferred that impaction has occurred. At any rate, whatever amount of repair does take place is due to the lower portion of the shaft of the bone. In impacted fracture the axis of the bone is obviously altered, and there is a slight cavity beneath the acromion, owing to shortening. The upper articular extremity unites with the shaft at about the *twentieth* year.

The upper epiphysis is sometimes separated in infants, in consequence of the carelessness of nurses

in lifting them suddenly up by the arm, giving rise to most serious mischief.

The accurate diagnosis of the nature of the lesion after injury to the shoulder-joint is often very difficult, and attention should be given to the following points.

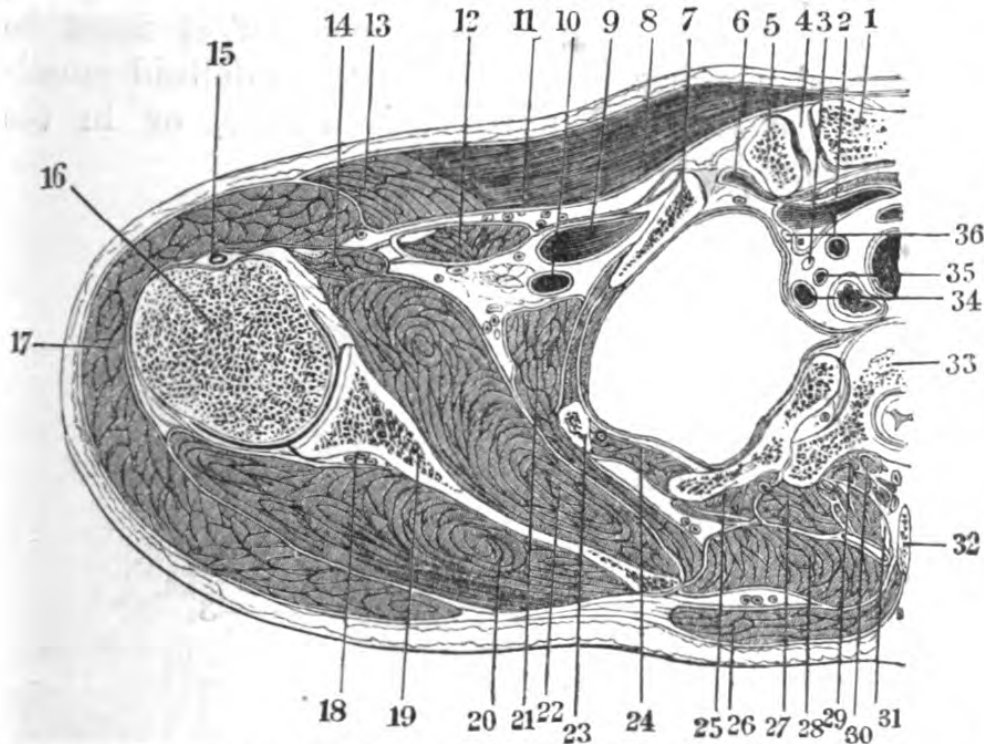


Fig. 24.—Section through head of Humerus, and passing through the Trunk at the level of the third Dorsal Vertebra. (One-fourth.)

- 1, sternum; 2, left carotid artery; 3, vagus nerve; 4, inter-articular fibro-cartilage; 5, clavicle; 6, sterno-hyoid muscle; 7, clavicle; 8, pectoralis major; 9, axillary vein; 10, axillary artery; 11, fascia behind pectoralis major; 12, pectoralis minor; 13, clavicular fibres of pectoralis major; 14, coracobrachialis and biceps; 15, long tendon of biceps; 16, head of humerus; 17, deltoid; 18, transverse scapular vessels; 19, scapula; 20, infra-spinatus muscle; 21, serratus magnus; 22, sub-scapularis; 23, second rib; 24, internal intercostal muscle; 25, levator costae; 26, trapezius; 27, longissimus dorsi; 28, rhomboideus major; 29, biventer cervicis; 30, semi-spinalis and multifidus spinæ; 31, splenius colli; 32, spinous process of second dorsal vertebra; 33, third dorsal vertebra; 34, subclavian vein; 35, vertebral artery; 36, phrenic nerve. (The humerus in this instance is rotated *inwards*.)

First of all, it must be seen whether the head of humerus is in its place; if fracture be suggested it

must be either in the surgical neck of the humerus, or its anatomical neck, the external extremity of the clavicle, the acromion, or the coracoid process or the neck of the scapula—each of which must be carefully examined in turn. In the absence of either of these conditions, there is probably a contusion or a sprain. In the event of inflammatory mischief, it must be determined whether its locale is in the deltoid muscle itself, in the bursa beneath this muscle, or in the scapulo-humeral articulation itself.

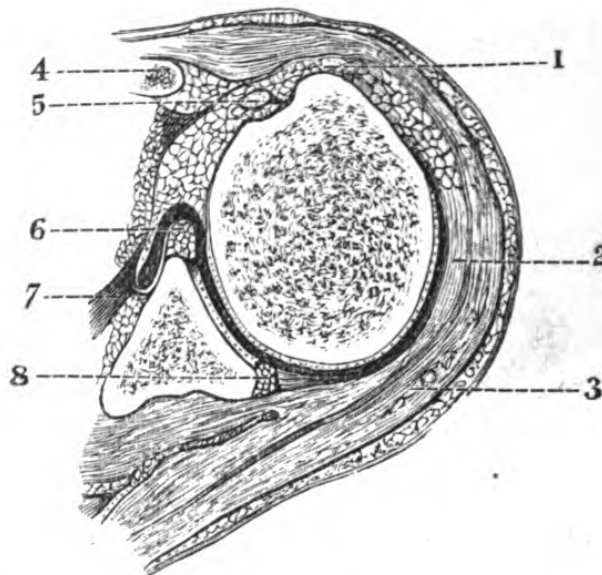


Fig. 25.—Section through Head of Humerus and Glenoid Cavity, the arm being rotated *outwards* to its greatest extent. (One-half.)

1, tendon of supra-spinatus; 2, infra-spinatus; 3, deltoid; 4, coracoid process; 5, long tendon of biceps; 6, glenoid ligament; 7, subscapularis; 8, glenoid ligament.

The landmarks already described in the superficial examination of the shoulder are of the greatest importance in the performance of the operations of *amputation at the shoulder-joint*, and of *excision of the head of the humerus*.

Contents of flaps after disarticulation at shoulder-joint by transfixion.—The external flap thus fashioned should contain—integument, the posterior fibres of the deltoid, circumflex vessels and nerve, tendons of latis-

simus dorsi, teres major, and teres minor; the internal flap—the subscapularis, long head of biceps, coracobrachialis, anterior fibres of deltoid, pectoralis major, axillary vessels and nerves, and integuments.

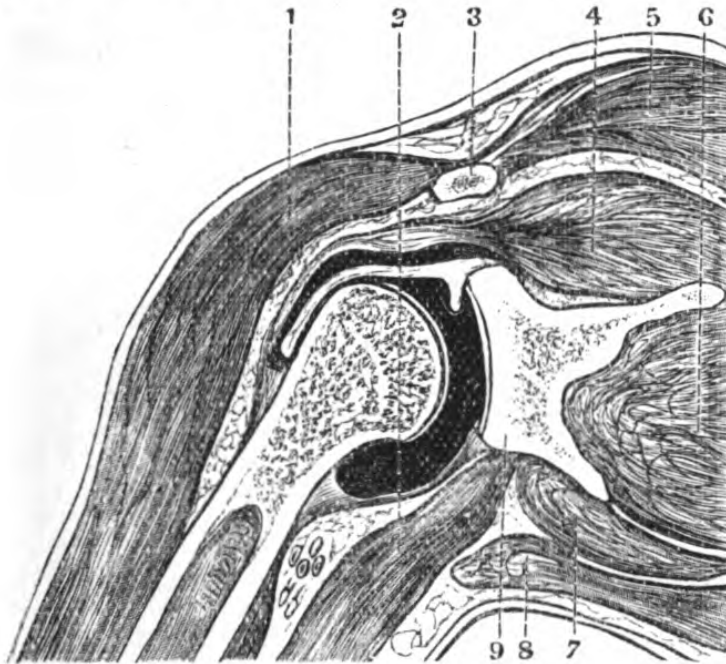


Fig. 26.—Frontal Section of the Shoulder-joint, showing the Capsule distended with fluid. (One-third.)

1, deltoid; 2, triceps; 3, clavicle; 4, supra-spinatus; 5, trapezius; 6, infra-spinatus; 7, teres minor; 8, teres major; 9, scapula.

SURGICAL ANATOMY OF THE AXILLA.

Surface markings and external form.—When the arm lies against the wall of the chest the area of the axillary space becomes confined, and for anatomical considerations ceases to exist; also when the humerus is extended beyond a right angle, the head projects into the space and obliterates its fold, but when the arm is raised to about an angle of 45° and the muscles contract, the depth of the fold of the axilla is most marked.

The *boundaries* of the axilla, which are seen beneath the skin, are—*anteriorly*, the lower margin of the pectoralis major muscle, rounded and muscular, but becoming tendinous as it approaches the humerus;

posteriorly, the lower edge of the latissimus dorsi muscle; *internally*, the chest wall; *externally*, the arm. The axillary artery is readily felt along the external boundary, and may be here compressed against the bone as it lies in the third part of its course, and it will be observed that this vessel follows

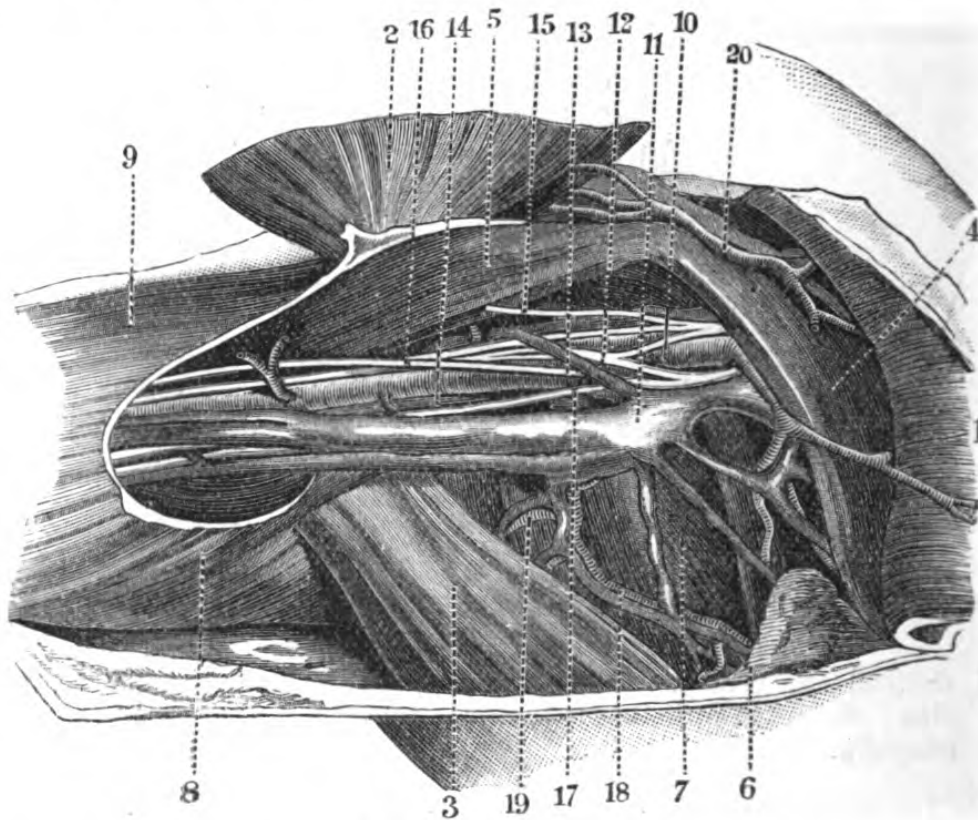


Fig. 27.—Axilla.

- 1, 2, pectoralis major reflected; 3, teres major and latissimus dorsi; 4, pectoralis minor; 5, coraco-brachialis and short head of biceps; 6, part of serratus magnus; 7, subscapularis; 8, triceps in its fascia; 9, brachialis anticus in its fascia; 10, axillary artery; 11, axillary vein; 12, median nerve; 13, musculo-cutaneous nerve; 14, musculo-spiral nerve; 15, nerve to coraco-brachialis; 16, musculo-cutaneous nerve; 17, ulnar nerve; 18, subscapular vessels; 19, circumflex vessels; 20, acromio-thoracic vessels.

the course of the arm in whatever position it takes. The *base* is formed by the integument, which is fully provided with hair bulbs and sebaceous follicles.

As the axilla would, in most cases, be attacked surgically from below, that is, from its base towards

its apex, it will be found to be advisable to describe its relations and contents as they would be met with in this direction.

Topography.—The integument is fine and covered with hair in the adult, and containing a number of sudiparous glands, next the subcutaneous cellular tissue, containing a good deal of reddish fat in its meshes; next, an aponeurosis, which is continuous in front with the sheath of the pectoralis major; behind with that of the latissimus dorsi; externally with the brachial aponeurosis, and internally with that covering the serratus magnus. On removing this aponeurosis the axillary space is opened; a large quantity of loose fat and cellular tissue and a number of lymphatic glands are seen filling up the interspace between the thorax and the arm.

Lying in this cellular tissue, and bridging across from the arm to the chest, will be seen a good many nerves, the intercosto-humeral, which, in some subjects, forms almost a plexus, supplying the skin of the base of the axilla; together with some branches of the axillary artery, the long thoracic and its veins passing downwards and forwards towards the anterior inferior aspect of the space, besides a considerable number of branches to the glands (alar thoracic). On removing this cellular tissue the walls of the axillary space can be made out.

The *internal* or *thoracic* wall, slightly convex, is formed by the first four ribs and their intercostal muscles, and the first five serrations of the serratus magnus, upon which lie the posterior thoracic nerve, the superior thoracic, and long thoracic branches of the axillary artery, with their corresponding veins.

The *external* or *scapulo-humeral* wall, formed by the scapulo-humeral region, is the most important, as on it lie the great vessels and nerves in their fascial envelope; and the fact of the close adherence of these structures to this wall of the axilla is of great value to the surgeon in the extirpation of tumours or opening

of abscesses, which fortunately, as a rule, lie along the inner wall. On either side of the bicipital groove are inserted the tendons of the pectoralis major and teres major, the latter being internal, and a little anterior and external is the tendon of the latissimus dorsi. Lying in this groove and enclosed in a prolongation of the synovial membrane of the joint is the long head of biceps itself; and most internally are seen the conjoined fibres of the coraco-brachialis and short head of biceps, the inner border of the former being the guide to the vessel; the insertion of the tendon of the subscapularis, and origin of the long head of the triceps. Above the tendon of the teres major the lower portion of the capsule of the joint is visible.

The *anterior* wall is formed by the pectoralis major and minor and their aponeuroses, and the lower border of the former covered by the integuments constitutes its anterior inferior margin. In the *female* this margin is hidden by the mammary gland, which overhangs it. The position of this gland is not influenced by the movements of the shoulder upon the trunk, as the cellular membrane between it and the anterior layer of the sheath of the pectoralis major permits of the free motion of the muscle beneath it; but in the case of scirrhus, owing to infiltration of the tissues, the movements of the pectoral are made with great pain and difficulty. On the posterior surface of these muscles are seen the acromio-thoracic vessels and external and internal anterior thoracic nerves.

The *posterior* wall is formed by the teres major and latissimus dorsi muscles below, and by the subscapularis above with their vessels and nerves.

The *apex* of the axilla may be referred to the coracoid process, though more correctly to the aperture between the clavicle, upper border of scapula, and first rib, with their muscular coverings. The cellular tissue of the cavity of the axilla becomes continuous with that of the subclavian region at the apex by enveloping the vessels that pass through this interspace.

CONTENTS OF THE AXILLARY SPACE.

The Axillary Fasciæ.

Although the axilla varies greatly in outward form during the different movements of the arm and thorax, and its various compartments become reduced or increased in capacity, the *relations* of its fasciæ are constant; and the vasculo-nervous cord formed by the axillary vessels and plexus is also a constant as regards the arm and chest-wall. The surgeon may have to deal with abscess or growths in this region with an anchylosed shoulder-joint. The axillary space is, after all, inseparable from the cervical region, both with respect to its fasciæ and cellular tissue, and, of course, is surgically continuous; but the result of suppuration may be localized in the armpit.

The pectoralis major is covered by a strong lamina of fascia, which is attached to all the subcutaneous bony eminences, and after assisting in forming the sharp anterior fold of the axilla, where it is very tough, it spreads out as a thinner but perfectly continuous layer, which forms the fascial floor of the axilla, and, covering the latissimus dorsi and teres muscles, passes upwards and backwards, becoming developed into the dense deltoid and scapular aponeuroses, whilst anteriorly and externally it is continuous with the brachial fascia. A deeper layer is given off at the anterior axillary fold, which passes upwards and forms the posterior layer of the sheath of the pectoralis major. The superficial pectoral aponeurosis sends down a process between the pectoralis major and deltoid, which becomes continuous with the costo-coracoid membrane, and supports the cephalic vein and some branches from the acromial axis.

The middle lamina of the deep cervical fascia, after having split to enclose the subclavius, reunites, and is attached to the clavicle, coracoid process, and fascial covering of the serratus magnus, forming the *costo-*

coracoid membrane, which covers in the axillary vessels and nerves and clavi-pectoral triangle. Again dividing, it encloses the pectoralis minor; reblending at the lower edge of this muscle, it becomes incorporated with the superior pectoral fascia and the anterior fold of the space, forming the *suspensory ligament of the axilla*, a most important factor in the disposition of abscess, and the existence of which is too frequently ignored or undescribed; hence it completely isolates the vasculo-nervous cord from the anterior compartment of the axilla, its internal border being continuous with the sheath of the pectoralis minor, and its external with the brachial aponeurosis.

The pectoralis minor is enveloped in a zone of loose areolar tissue, which is most favourable for supuration. Hence the pus may exist between the pectorals, or below the pectoralis minor: in the former case it would "point" at the anterior border of the axillary fold, or in the furrow between the deltoid and pectoralis major; in the latter, the pus being behind, and bound down by the clavi-pectoral fasciæ, would have a tendency to surround the vasculo-nervous cord and ascend into the neck, infiltrating the cellular space, and ultimately find its way into the superior aperture of the thorax, and so into the anterior or posterior mediastinum. There is a great tendency for the pus to find its way beneath the latissimus, and burrow into the subscapular fossa, whence it may involve the articulation of the shoulder. In some instances the pus will extend down as far as the brim of the false pelvis.*

The axillary artery, axillary vein, and brachial plexus form a vasculo-nervous cord, bound together by a dense cellular sheath which is placed on the outer wall of the space, and lying along the inner border of the coraco-brachialis muscle; the pulsations of the artery are felt at the apex (if the pectoralis major is

* Abstract of Clin. Lect. delivered in Charing Cross Hospital by author. 1879. *Med. Times and Gaz.*

relaxed), and at its lower portion, and in thin persons the *cord* of the median nerve is usually seen stretched over it when the arm is raised from the side. The *course* of this vessel is indicated by a line passing through the axilla, drawn from about the centre of the clavicle to the inner border of the coraco-brachialis muscle. It lies in an envelope of nervous cords—the median, musculo-spiral, musculo-cutaneous, ulnar, and internal cutaneous. The axillary vein is very large, and lies internal to and a little in front of the artery, and in ligature of the artery it is seen first, and must be drawn to one side. It is adherent to the cellular tissue and by fascial attachment to the coracoid process, and if wounded is liable to gape considerably, and thus admit air, an accident which has happened in removing axillary tumours.

Relations of axillary artery.—In the *first* part of its course, *i.e.*, between the clavicle and the upper border of the pectoralis minor muscle, it lies beneath the clavicular attachment of the pectoralis major, in a triangle (the *subclavicular*), which is bounded above by the subclavius muscle, below by the pectoralis minor, and internally by the thoracic wall. Immediately beneath the pectoralis major is a dense fascia (the *costo-coracoid membrane*). In *front* of the vessel in this part of its course lie the clavicular portion of pectoralis major, the subclavius muscle, costo-coracoid membrane, and cephalic vein, and the loop from the outer and inner cords, giving off the external and internal anterior thoracic nerve; *externally*, the cords of the brachial plexus; *internally*, the axillary vein; *posteriorly*, the first intercostal muscle, second serration of serratus magnus, and the nerve of Bell.

The *second* part of the course of this vessel lies beneath the crossing of the pectoralis minor, and by dividing the remaining portion of the pectoralis major and the pectoralis minor, the whole extent of the vessel will be exposed.

In *front* of the second portion of the vessel lie the

pectorals and inner head of median nerve ; *externally*, the external cord of the brachial plexus ; *internally*, the axillary vein and inner cord of the plexus ; *posteriorly*, the posterior cord of the plexus and the subscapularis muscle, separated from it by a cellular interval.

The *third* portion of the vessel is beyond the pectoralis minor, and between it and the lower border of the pectoralis major by which it is covered. In *front* of the third portion of its course lies the pectoralis major ; *externally*, the coraco-brachialis, the median, and musculo-cutaneous nerves ; *internally*, the ulnar and internal cutaneous nerves and axillary vein ; *posteriorly*, the musculo-spiral and circumflex nerves, and the tendons of the latissimus dorsi, teres major, and subscapularis muscles.

The branches of the axillary artery are usually given off in the following order : the *thoracica suprema*, which runs along the upper part of the inner wall ; the *acromio-thoracic*, sending branches to its anterior wall ; the *long thoracic*, lost on the thorax and mammary gland ; the *subscapular*, which descends obliquely along the inferior border of the subscapularis, and is distributed to the muscles of the posterior wall, one large branch in particular, the *dorsalis scapulae*, passing to the dorsum scapulae in the triangular interval between the two teres muscles and long head of triceps ; the *posterior circumflex* passes through the quadrilateral space formed by the two teres muscles, long head of triceps, and humerus, and winds round the neck of the humerus, supplies the deltoid, and is accompanied by the circumflex nerve and veins ; the *anterior circumflex*, a small branch, is supplied to the articulation beneath the coraco-brachialis and biceps, and inosculates with the former.

Thus, if the vessel be normal, the acromio-thoracic, and thoracica suprema are given off above the pectoralis minor, the external mammary about opposite the middle of this muscle, and the dorsalis scapulae and anterior

and posterior circumflex at the lower border of the subscapularis muscle.

Besides the large nervous trunks, branches derived from them are met with passing to the muscles covering the several walls of the space. Thus, the anterior wall is supplied by the loop formed round the first part of the artery by the external and internal anterior thoracic nerves, the inner wall by the posterior thoracic, the posterior wall by the subscapular, the outer by the circumflex and musculo-cutaneous.

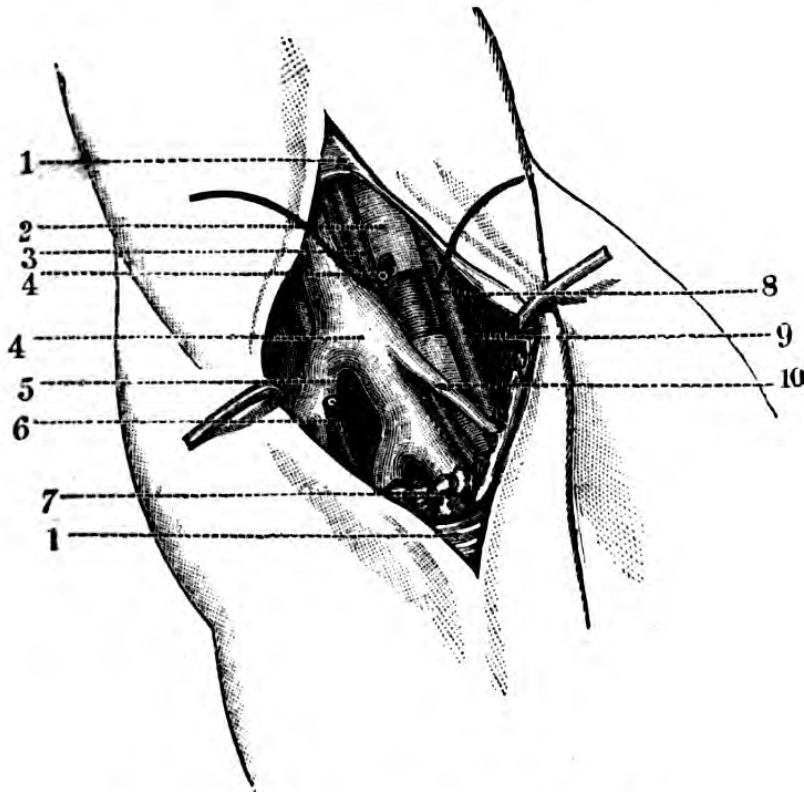


Fig. 28.—Ligature of left Axillary Artery.

1, axillary fascia; 2, axillary artery; 3, internal cutaneous nerve; 4, external thoracic artery (cut); 5, subscapular vein; 6, external thoracic artery (cut); 7, lymphatics; 8, median nerve; 9, coraco-brachialis muscle; 10, external thoracic vein. (The sheath of the artery has been denuded at the point of ligation.)

The *lymphatic glands* are very numerous, and lie, some along the course of the vessels, and some along the lower border of the pectoralis major. These *glands* receive the lymphatics of the upper extremity, back,

and posterior part of neck, the lateral lymphatics of the trunk, those of the epigastrium and anterior part of thorax, and mammary region.

Ligature of the axillary artery.—The axillary artery may be tied in the first part of its course or in the third.

In the first part it is very deep and difficult of access, but it may be reached, either by an incision separating the fibres of the pectoralis major and deltoid, or by a semilunar one, extending from a little external to sterno-clavicular joint towards the coracoid process, taking care to avoid the cephalic vein; next the clavicular fibres of the pectoralis major must be divided, the arm adducted, and the pectoralis minor drawn down. The costo-coracoid membrane, which is next seen on the stretch, must be opened, the cords of the plexus drawn outwards, and the axillary vein inwards, when the ligature can be passed from *within, outwards*.

This operation is very difficult and dangerous, from the close relation of the axillary and cephalic veins, and the acromio-thoracic vessels.

In the third part the vessel is easily reached.

The arm is to be extended and supinated, in order to throw out the fold of the coraco-brachialis muscle, the inner border of which is the guide to the artery, and an incision of about three inches in length is to be made through the integument, rather nearer the anterior than the posterior fold of the axilla, the deep fascia being scratched through and the basilic or axillary vein avoided; the artery is seen lying crossed by the median nerve, and having the axillary vein to its inner side, and sometimes on it; these structures must be carefully isolated, and the needle passed from *within, outwards*. Occasionally the vessel divides high up into the brachial and radial, thus complicating the operation of ligature. Again, after division, these trunks may reunite by cross branches, and the circulation continue as freely as before, unless a ligature be applied to each.

On applying a ligature to the axillary artery in its third part the following hint may be useful: divide the integuments at the junction of the anterior with the two posterior thirds of the fold of the axilla, look for the axillary vein, count two nerves, and next in order is the artery.

Collateral circulation after ligature of the axillary.—Ligature of the axillary artery in the upper part of the first portion of its course, above the giving off of the acromial thoracic, may be regarded as equivalent to ligature of the subclavian in the *third part* of its course (*vide* “Ligature of Subclavian”). If the vessel be tied below this point, the subscapular inosculating with the supra-scapular and posterior scapular, and the long thoracic with the internal mammary and intercostals, are called upon to restore the circulation. If the ligature be applied below the giving off of the subscapular, the posterior circumflex, anastomosing with the supra-scapular and acromio-thoracic, and the subscapular with the superior profunda, form the chief collateral channels.

Malgaine and Tillaux have both recorded a muscular anomaly which would be likely to embarrass the operator; should he encounter it, this is a subaponeurotic muscular band, which crosses the vessels obliquely, passing from the latissimus dorsi to the pectoralis major, and which might be mistaken for the coraco-brachialis.*

SURGICAL ANATOMY OF THE BRACHIAL REGION.

Surface markings.—This region may be considered as lying between a line drawn round the lower border of the axilla, and another round the arm just above the condyles of the humerus. Its general form is that of a cylinder, flattened internally and externally,

* This slip is considered by Professor Wood to be an imperfect development of the *dorsi-epitrochlear* muscle of the lower animals. (*Vide* Wood, Proc. Roy. Soc., June 21, 1856.)

convex in front, owing to the swell of the biceps muscle. Along the inner aspect of the biceps is a well-marked groove, extending from the axilla to the bend of the elbow; whilst a shallow groove exists also on its outer surface, becoming lost at the point of insertion of the deltoid; beneath the skin is seen in the internal groove the basilic vein, and external to the biceps, the cephalic. The posterior surface of the brachial region is rounded at about its middle, where the greater mass of the triceps muscle lies, and below this point its flattened sharp-edged tendon forms towards its insertion into the olecranon. In the inner groove lies the brachial artery, where it can be felt or seen pulsating, overlapped by the inner border of the biceps at about its middle, the muscle forming the guide to it throughout its course, either for its deligation or compression. The surgical considerations affecting this region refer chiefly to amputation, ligature of its vessel, fractures, and the removal of tumours.

Topography.—Beneath the integument the subcutaneous cellular tissue, divided into two laminae by a layer of fat, is first met with, and it is in this tissue that the superficial veins and lymphatics lie.

The *brachial aponeurosis* completely envelopes the arm, and is thickest at the back and sides; it is continuous above with that covering the deltoid, axillary, and subclavicular regions, and below with that covering the forearm, and sending processes between the muscles forms septa, which are attached to the humerus. The attachment of this aponeurosis is very evident laterally, where it is inserted into the condyles and condyloid ridges of the humerus, dividing the region into two distinct compartments, an anterior and a posterior.

The *anterior* contains, successively, the biceps, immediately beneath which, in the lower half of the arm, is the brachialis anticus, enclosing at the upper part of its origin the insertion of the deltoid, and passing

downwards to its own insertion, covers in the humerus completely between the lateral margin of the anterior and posterior compartments. Behind, and internal to the biceps above, is the coraco-brachialis;

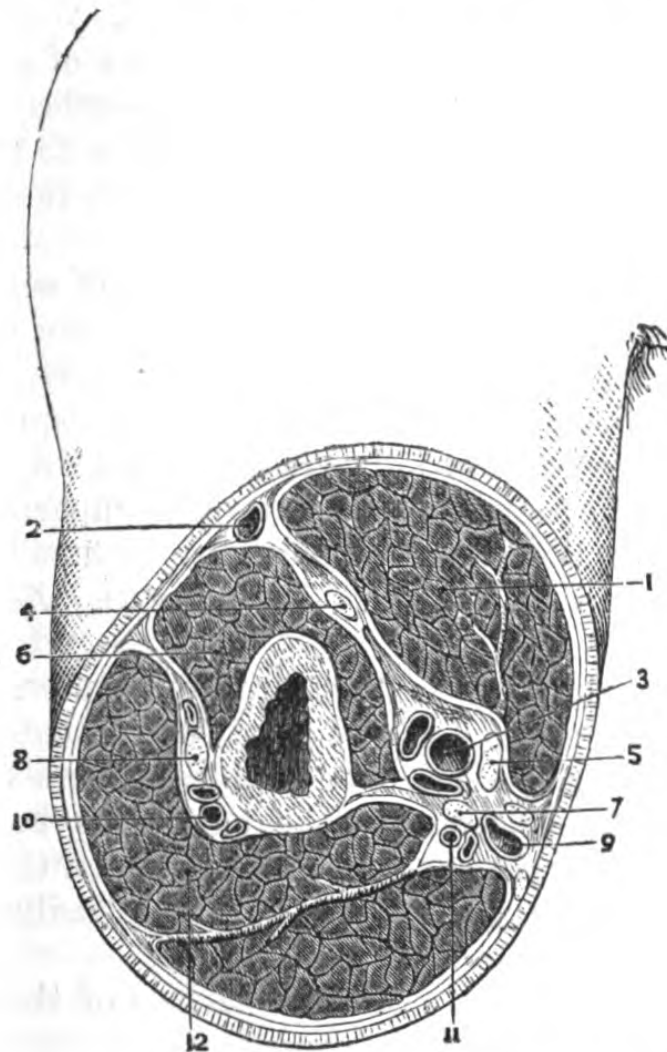


Fig. 29.—A Section through the middle of the Right Upper Arm.

1, biceps; 2, cephalic vein; 3, brachial vessels; 4, musculocutaneous nerve; 5, median nerve; 6, brachialis anticus; 7, ulnar nerve; 8, musculo-spiral nerve; 9, basilic vein, with internal cutaneous nerves; 10, superior profunda vessels; 11, inferior profunda vessels; 12, triceps, with fibrous intersection. (Heath.)

below and externally are, the musculo-spiral nerve, the origins of the supinator longus and extensor carpi radialis longior.

Lying along the inner border of the biceps is the vasculo-nervous cord, formed by the brachial artery, its veins, and the median, ulnar, external and internal cutaneous nerves; the median accompanies the artery throughout, lying first outside it, then upon it, and lastly internal. In the upper third, this vasculo-nervous cord lies along the inner border of the coracobrachialis, having the long head of the triceps behind, and just on the humerus, against which the vessel is easily compressed; in its lower two-thirds it lies on the brachialis anticus.

The *posterior* aponeurotic compartment contains the triceps, which covers in the entire posterior surface of the humerus and the musculo-spiral nerve before it passes anteriorly, as it lies in the musculo-spiral groove with the superior profunda vessels, before it perforates the septum to pass into the anterior compartment. It also contains the ulnar nerve, which at first lies in the anterior compartment, in contact with the brachial artery above.

This aponeurotic investment presents, moreover, two superficial openings, by means of which collections of pus or blood may become subcutaneous, one above and external, giving passage to the cutaneous branches of the musculo-spiral nerve, and the other on the internal aspect of the arm, giving passage to the basilic vein and internal cutaneous nerve.

A correct knowledge of the relations of the layers of these muscles, their aponeuroses, and the course taken by the main vessel and its branches, determines the contents of the flaps in amputation of the upper arm.

Relations of the brachial artery (above bend of elbow).—Its course is indicated by a line drawn from the junction of the anterior with the posterior two-thirds of the axilla, to the centre of the bend of the elbow. It is accompanied by venæ comites, which frequently interlace and conceal the vessel when cut down upon. In *front* of the vessel is the integument and fasciæ and the median nerve; *externally*, median nerve (in upper

half), coraco-brachialis, and biceps; *internally*, internal cutaneous and ulnar nerves, and in lower half the median nerve; *posteriorly*, lie the brachialis anticus, coraco-brachialis, musculo-spiral nerve, and superior profunda vessels, separating the middle and long heads of the triceps.

Ligature in the upper third is performed by making an incision about two inches in length along the inner border of the coraco-brachialis muscles; the subcutaneous tissue and aponeurosis are to be divided, taking care to avoid the basilic vein; then the internal cutaneous and ulnar nerves will be found on the inner side of the artery, the median externally, and a number of venæ comites superficial to, and on each side of it. The needle should be applied from *within, outwards*. Occasionally two arteries are found lying parallel to each other, or placed one over the other, the posterior lying very deep, the result of a high division; under such circumstances it is obvious that it must be determined by pressure whether one or both communicate with the aneurism or wound.

In the middle third the vessel is not so easy to tie as might be imagined from its superficial position; it is beneath a very dense part of the fascia, and is often overlapped by the biceps, which structure is very moveable beneath the integuments. It is reached by an incision along the inner border of this muscle, the forearm being slightly flexed so as to relax the biceps. The median nerve is usually first met with, crossing the vessel; this should be drawn inwards and the biceps outwards, and the venæ comites carefully separated from the trunk before a ligature is applied. In this instance, as in several others, it is advisable to make the incision slightly *oblique* to the real course of the vessel, as room is gained, and also a better view of any deviation from its natural position. The inferior profunda, if large, or the ulnar nerve, may sometimes be mistaken for this vessel.

Branches of the brachial artery.—The *superior pro-*

profunda is given off generally opposite the lower border of the teres major, and accompanies the musculo-spiral nerve; the *nutritious* artery enters the nutrient canal near the insertion of the coraco-brachialis, and passes downwards towards the elbow-joint; the *inferior profunda* accompanies the ulnar nerve; the *anastomotica magna* arises on the inner side, about two inches above the elbow-joint, and lies between the brachialis anticus and median nerve, crossing the latter, and finally divides into two large branches. In applying a ligature to the lower portion of the main trunk, the position of this vessel is of importance, as it is the chief means of carrying on the collateral circulation.

Collateral circulation. — After ligature *above* the origin of the profunda superior, the posterior circumflex and subscapular, anastomosing with the ascending branches of the profunda, carry on the circulation; if *below*, the superior profunda, inosculating with the recurrent branches of the radial, ulnar, and interosseous, would maintain it.

The *action of the muscles* attached to the humerus upon the fragments in *fractures* of this bone, is generally as follows:—If below the insertion of the muscles attached to the bicipital groove, but above the insertion of the deltoid, this muscle drags the lower fragment upwards and outwards, whilst the former set draw the upper fragment towards the trunk. If below the insertion of the deltoid, the action of the muscles depends upon the direction of the fracture; that is to say, whether it be oblique or transverse.

Bearing in mind that the period of union of the shaft and its superior epiphysis is about the thirteenth year, we have an important diagnostic point, in cases of difficulty, between fractures immediately above the condyles, separation of the epiphysis, and dislocation of both radius and ulnar backwards. If the fracture exists, the crepitation and ready reduction of the bones to their normal position would distinguish it from dislocation. Again, if instead of being transverse, the fracture of the

shaft be oblique, in a direction from above downwards and forwards, the triceps will draw the lower fragment upwards and backwards; if oblique in a contrary direction, the lower fragment would be drawn upwards and forwards by the brachialis anticus and biceps. Occasionally, however, there is no displacement, in the case of the "screw fracture," or fracture *en V.*, which may take place from violent muscular action, as in throwing a cricket-ball.*

Owing to the attachment of the flexors and extensors of the wrist and fingers to the condyles, unless the forearm be also put up in a bent splint, there is a great liability to ununited fracture, as any movement of the wrist would tend to displace or rotate the lower fragment.

SURGICAL ANATOMY OF THE REGION OF THE ELBOW.

Surface markings.—This region includes the articulation of the elbow-joint, and its immediate relations, and presents for superficial examination four surfaces. In *front* a hollow is formed by the muscles attached to the condyles, within which lies the tendon of the biceps, its margin sharp externally, and flattened internally where its fascia is felt passing to the muscular mass attached to the inner condyle, and below which can be seen or felt the pulsation of the brachial artery; beneath the skin are visible, particularly in thin persons, the superficial veins of the bend of the elbow. On the *outer* side can be felt the external condyle, and the head of the radius; *internally*, the inner condyle; whilst *posteriorly*, nearer the inner than the outer condyle, is the olecranon, with the insertion of the triceps tendon.

The mutual relations of these structures to each other should be carefully examined in every position of the normal arm, in extreme and intermediate flexion and extension, and in pronation and supination of the forearm, and in cases of injury compared with the opposite

* Vide case in author's practice. *Lancet*, May 11, 1878.

side. In complete extension, the olecranon is above the level of the condyles ; in semiflexion, on the same

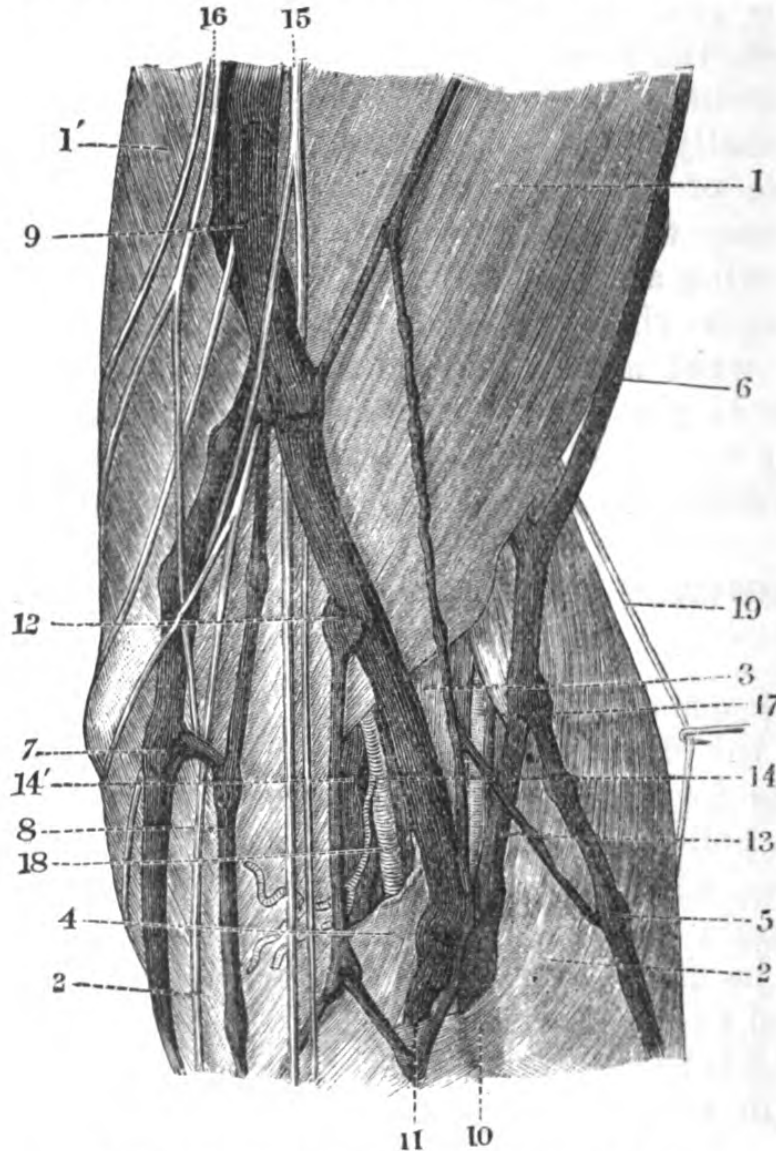


Fig. 30.—Bend of Elbow. (One-half.)

, 1', brachial aponeurosis; 2, 2, anti-brachial aponeurosis; 3, slip of brachial aponeurosis, passing to the muscles attached to the external condyle; 4, bicipital fascia; 5, superficial radial vein; 6, cephalic vein; 7, epitrochlea; 8, superficial ulnar vein; 9, basilic vein; 10, median vein; 11, deep radial vein; 12, median basilic vein; 13, median cephalic vein; 14, 14', abnormal vessels; 15, 16, internal cutaneous nerve; 17, external cutaneous nerve; 18, brachial artery and venæ comitēs; 19, cutaneous branch of musculo-spiral nerve.

level; and in flexion, at a right angle below the level of the condyles.

Bend of elbow. — Anterior aspect. — Beneath the

skin, which is thin, lax, and plicated, is the subcutaneous cellular tissue, in which lie the cutaneous nerves, separated from an important plexus of veins and lymphatics by the superficial aponeurosis. The folds in the skin are constant, and depend upon the several movements of the limb being placed well above the interarticular spaces. These serve as useful guides in operations. In fracture of the inferior extremity of the humerus, the transverse fold lies below, or on the level with the upper fragment, and in dislocation it is slightly above it. The nerves are derived from the internal cutaneous, lesser internal cutaneous, median and musculo-cutaneous. The superficial veins are derived principally from the radial, ulnar, and median veins, and at the inner border of the biceps tendon the median joins the basilic, by means of a large oblique branch, the median basilic; and also the cephalic, by a similar branch; the median cephalic lies along the lower border of the biceps. At the point of bifurcation, the aponeurosis of the forearm is perforated by a communication between these veins and those accompanying the brachial artery, also between the superficial and deep lymphatics. The aponeurosis of the bend of the elbow is a continuation of the brachial, and is strengthened internally by an offset from the tendon of the biceps (the bicipital fascia). It is this process which separates the median basilic vein from the brachial artery. It receives, moreover, posteriorly a slip from the tendon of the triceps, is attached to both condyles, and has a further slip from the brachialis anticus tendon.

Beneath the aponeurosis is the mass of muscles which form the boundaries of the space. *Externally*, from above downwards, in order, are the supinator longus, extensor carpi radialis longior and breviar, covering the lower and external part of the humerus, and the external lateral ligament. *Internally*, the common tendon of origin of the flexors and pronators of the wrist and forearm above; and passing between these muscular masses are, externally, the tendon of the

biceps; internally, the tendon of the brachialis anticus, covering in the anterior part of the articulation, part of the head of the radius, and the coronoid process. These muscles form two wedge-like troughs, in the outer of which lie the musculo-spiral nerve, superior profunda and radial recurrent vessels; in the inner, the brachial artery, with its venæ comites, and the median nerve.

The brachial artery at the bend of the elbow lies in the middle of this space, at first superficial, and afterwards, before it divides, deep, and opposite the coronoid process forms the radial and ulnar, and has the following relations:—In *front*, integument and superficial fascia, median basilic vein, bicipital fascia; *externally*, tendon of biceps; *internally*, median nerve; *posteriorly*, the brachialis anticus.

The *lymphatics* are both superficial and deep, the former lying upon the aponeurosis, and communicating with one or more large glands immediately over the anterior aspect of the inner condyle; these glands become enlarged in poisoned wounds of the finger, and indurated in constitutional syphilis. The *deep lymphatics* follow the course of the *arteries*.

This aspect of the region is of the highest surgical importance, as in the operation of bleeding from the median basilic vein, there is a chance of wounding the brachial artery; in the event of such an accident occurring, either an aneurismal varix, or varicose aneurism, or a diffuse or circumscribed traumatic aneurism, might be the result. Arterial hæmorrhage from wounds in this region, can be generally controlled by extreme flexion of the arm, aided by a pad of lint or small roller. Owing to the great number of inosculating vessels lying round the joint, there is considerable chance of secondary hæmorrhage.

The *posterior* aspect of the region of the elbow presents for examination the olecranon process of the ulna, between which and the integument is a bursa; external to the olecranon can be felt the articulation

of the head of the radius with the capitellum; and internally a deep depression, between it and the projecting inner condyle, in which lies the ulnar nerve and posterior ulnar recurrent artery, passing between the two heads of the flexor carpi ulnaris. The posi-

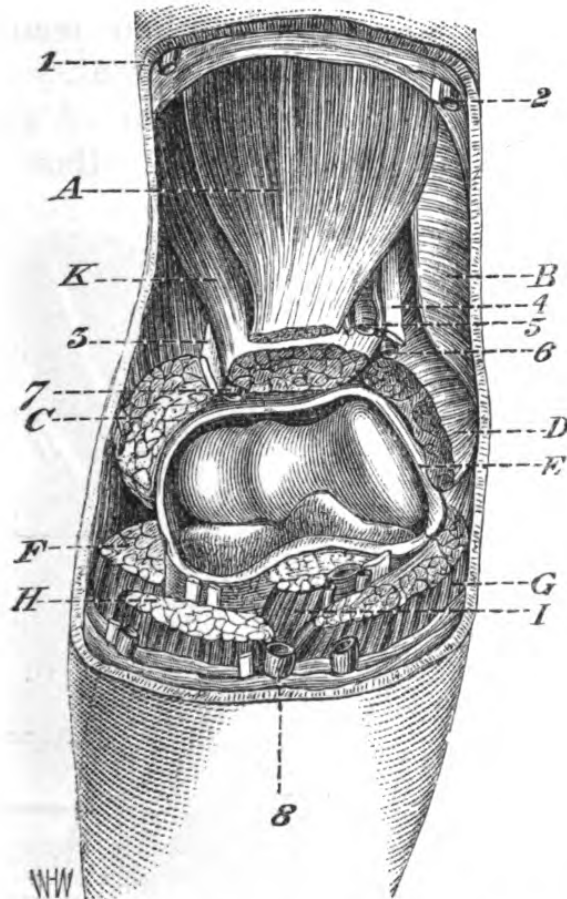


Fig. 31.—Structures in Relation with the Anterior Aspect of the Elbow-joint.

1, cephalic vein; 2, basilic vein and internal cutaneous nerve; 3, musculo-spiral nerve; 4, median nerve; 5, brachial artery and venæ comites; 6, anastomotica magna; 7, radial recurrent; 8, median vein; A, biceps; B, triceps; C, supinator longus and extensor carpi radialis longior (the division between them is not evident enough). D, origins of flexors and pronators; E, capsule of joint; F, extensor carpi radialis longior; G, pronator teres; H, supinator longus; I, tendon of biceps (beneath which is the brachialis anticus and the capsule).

tion of this nerve must be borne in mind in resection of the elbow-joint, and it must be carefully isolated, and hooked out of the way in the course of the operation, to avoid injury. The artery is only

protected in this operation by the brachialis anticus, so that after the bones are divided, the knife must be used cautiously. The great vascularity of the region of the elbow-joint is, no doubt, one cause of the success attending its excision, the inosculating branches being the superior and inferior profundæ, anastomotica magna, anterior and posterior ulnar recurrent, interosseous recurrent, and radial recurrent. It is worthy of notice that the nutrient vessels of the humerus, radius, and ulna run *towards* the elbow-joint.

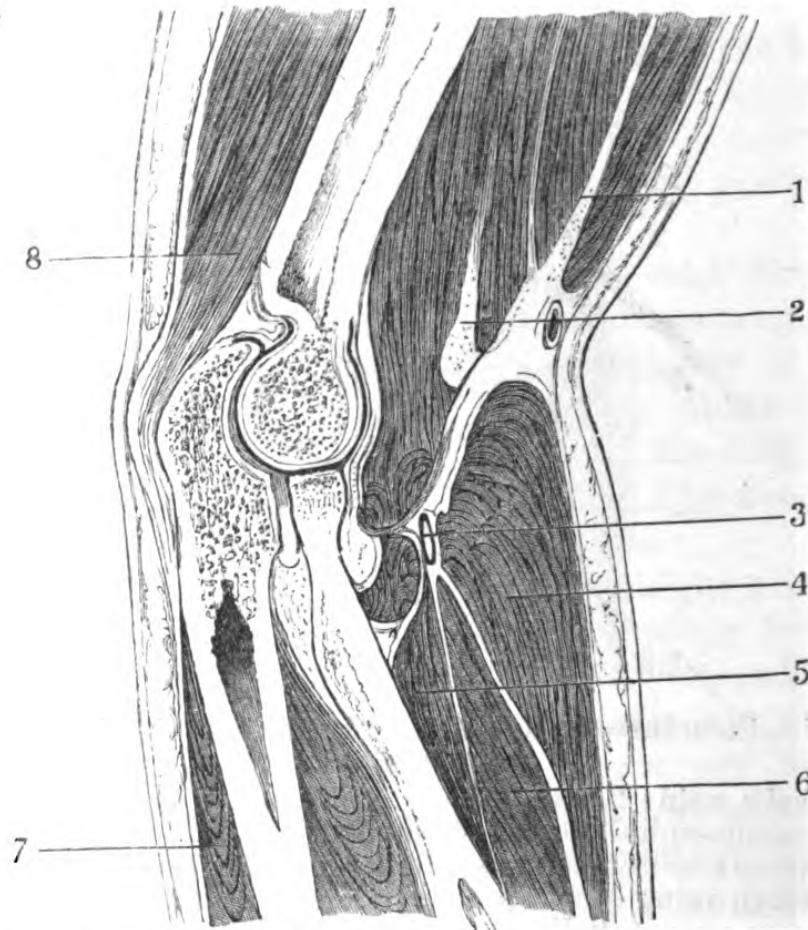


Fig. 32.—Longitudinal Section of Elbow-joint. (One-half.)

- 1, biceps; 2, brachialis anticus; 3, musculo-spiral nerve; 4, supinator longus; 5, supinator brevis; 6, extensor carpi radialis longior; 7, extensor carpi ulnaris; 8, triceps.

Vertical section through the elbow-joint.—Skin and integument, containing the superficial veins and nerves already described, aponeurosis of arm, supinator longus,

pronator teres, brachial artery and veins, and median nerve and musculo-spiral nerve, extensor carpi radialis longior, tendon of biceps, brachialis anticus, supinator brevis, flexor carpi radialis, extensor carpi radialis brevior, external and internal lateral ligaments, flexor sublimis, ulnar nerve, extensor carpi ulnaris, flexor carpi ulnaris, anconeus, olecranon, and olecranon bursa, and then the integument.

The *articulation of the elbow-joint* admits of flexion and extension, and the direction of the articular surfaces not being parallel to a line drawn through the condyle, it follows that the axis of the forearm is not continuous with that of the arm, the trochlear surface being lower down than the capitellum. The *ligaments* connecting the bones of the joint are very strong—namely, an

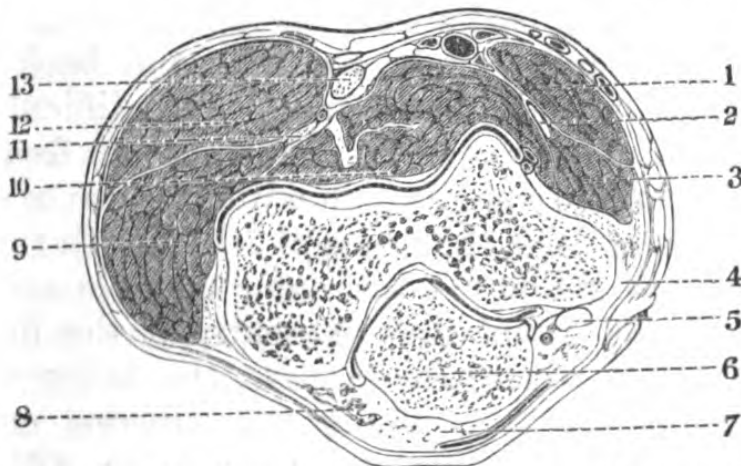


Fig. 33.—Vertical Section of Elbow. (One-half.)

1, pronator teres; 2, median nerve; 3, flexor carpi radialis; 4, internal lateral ligament; 5, ulnar nerve; 6, olecranon; 7, tendon of triceps; 8, anconeus; 9, extensor carpi radialis longior; 10, brachialis anticus; 11, radial nerve; 12, supinator longus; 13, tendon of biceps.

anterior, a posterior, and two lateral, whilst there is a very large synovial membrane, the arrangement of which, in diseases of the articulation, causes the swelling to take place posteriorly on either side of the olecranon, and anteriorly at the bottom of the fold at the bend of the elbow.

Fractures of the humerus, in the region of the joint, frequently implicate it, and are to be distinguished

from dislocation by there not being the change in the normal relation of *three* bony processes—viz., the olecranon, epicondyle, and epitrochlea. The internal condyle should be midway between the last rib and the iliac crest, as the arm hangs by the side. In extension of the forearm, the olecranon is about an inch away from the internal condyle, and on the same level with it—in flexion at a right angle it is an inch and a half away from it and below it. Almost any form of dislocation may exist, but the most common is that of both bones of the forearm backwards, the strength of the lateral ligaments being a great obstacle to lateral displacement.

The *dislocations* to which the articulations of the elbow-joint are liable are, in the first place, of both radius and ulna, backwards, outwards, inwards, forwards; of the radius only, forwards and backwards; and of the ulna only, backwards. The difficulties in the diagnosis of these several conditions are frequently enhanced from the complication with fracture or separation of the epiphyses, the union of which with the shaft takes place as follows:—the outer condyle and both portions of the articulating extremity of the humerus at the *sixteenth or seventeenth year*, the inner condyle at the *eighteenth year*, whilst the superior articular extremities of the radius and ulna unite with their shafts at *puberty*. It may be here remarked that it is not the *complete* dislocations or fractures which are difficult to diagnose, but the *incomplete* or *partial*.

SURGICAL ANATOMY OF THE FOREARM.

Surface markings.—The front of the forearm, or antebrachial region, may be described as lying between the lower margin of that assigned to the elbow and the first fold seen in front of the wrist-joint. In shape it is that of a flattened cone, which varies in form according as the limb is pronated or supinated, the roundness of its lateral boundaries being due to the flexors and pronator

teres on the inner, and the supinators and extensors on the outer. The bones, the radius and ulna, are capable of being felt almost entirely throughout the region, particularly the ulna, the posterior border of which is subcutaneous from the olecranon to the styloid process; the radius, however, has its shaft thickly covered with muscles, and is felt with greater difficulty, and the several tendons of the muscles clothing them are readily seen on putting them in action. The radial and ulnar pulses are seen in the lower part, while the radial can be felt in the upper along the inner border of the mass of muscles at the radial side.

Topography.—Beneath the skin, which is thin and smooth, and provided with hairs, the subcutaneous fascia is met with, containing a good deal of fat, in which lie the superficial veins and cutaneous nerves and lymphatics. Beneath this layer is the antebrachial aponeurosis, continuous with that already described at the elbow. It is dense, tough, and by its prolongation forms fibrous sheaths for the muscles and other structures of the region. This general antebrachial aponeurosis may be considered as forming into two chief compartments, attached laterally to the radius and ulna; thus the anterior is bounded by the anterior lamina, the anterior surfaces of the radius, ulna, and interosseous membrane, and the posterior by the posterior surface of these bones and the interosseous membrane, and by the aponeurosis.

The anterior of these compartments contains from the surface to the interosseous membrane, the integument of the forearm, aponeurosis, the radial vessels and nerves, lying in a cellular interspace between the radial and ulnar mass of muscles, pronator teres as far as the middle third, palmaris longus, flexor carpi radialis and ulnaris, on the inner aspect, and the supinator longus, extensor carpi radialis, longior and brevior on the outer aspect, beneath which muscles are the supinator brevis, the flexor sublimis digitorum, median nerve, and ulnar vessels and nerve, flexor profundus, and flexor longus

pollicis, lying on the bones and interosseous membrane. In the lower third, the tendons of the muscles passing to the wrist lie over the pronator quadratus, and upon the membrane itself the anterior interosseous vessels and nerves.

The posterior compartment contains from the surface to the bones the extensor communis digitorum, slightly

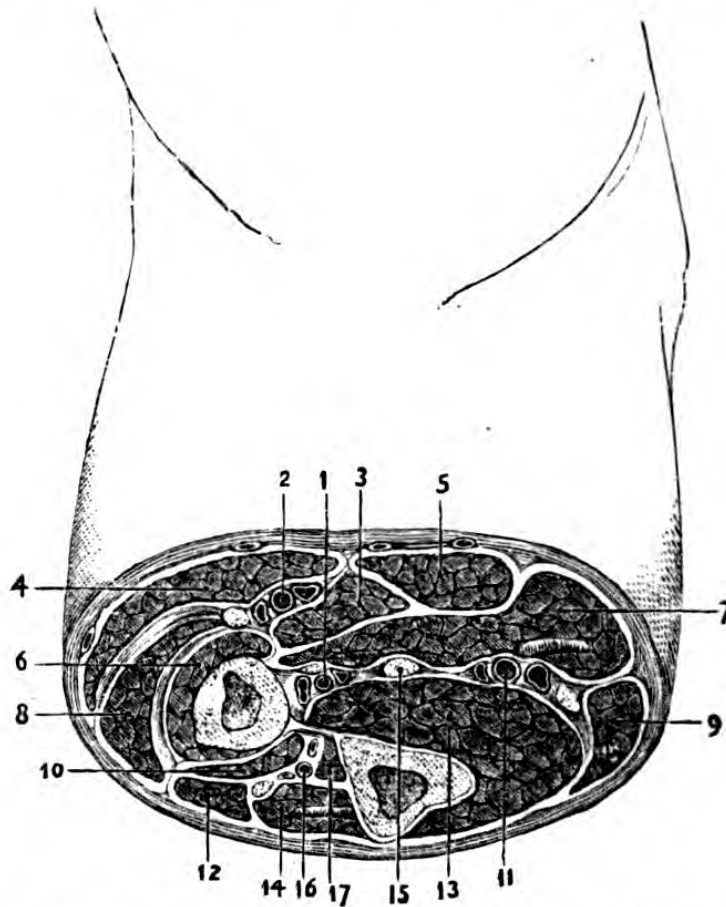


Fig. 34.—Section through the Middle of the Right Forearm.

1, anterior interosseous vessels and nerve; 2, radial vessels and nerve; 3, pronator teres; 4, supinator longus; 5, flexor carpi radialis; 6, supinator brevis; 7, flexor sublimis digitorum; 8, extensores carpi radialis longior and brevior; 9, flexor carpi ulnaris; 10, extensor ossis metacarpi pollicis; 11, ulnar vessels and nerve; 12, extensor communis digitorum; 13, flexor profundus digitorum; 14, extensor carpi ulnaris; 15, median nerve; 16, posterior interosseous vessels and nerve; 17, extensor secundi internodii pollicis.

covered in above by the extensor carpi radialis longior, and lower down, lying along the extensor carpi radialis

brevior, extensor minimi digiti, extensor carpi ulnaris, and anconeus. The second layer comprises the extensor ossis metacarpi, primi and secundi internodii pollicis, the extensor indicis, and the posterior interosseous vessels and nerves. The extensors of the thumb will be seen to form a sort of spiral round the lower part of the radius; they are enclosed in a sheath which is very liable to be the seat of severe tenosynovitis, especially met with in reapers and labourers.

Relations of the radial artery in the forearm.—Supposing the vessel to be normal, a line drawn from the middle of the bend of the elbow to the inner side of the styloid process of the radius represents its *course* in the upper third; it is concealed by the pronator teres and by the edge of the supinator longus, and lies on the tendon of the biceps, and in a bed of fat and cellular tissue, in relation with some muscular branches of the musculo-spiral nerve, and on the supinator brevis. In the middle third it lies between the tendons of the flexor carpi radialis and supinator longus, having the radial nerve to its outer side, and on the pronator teres and flat head of flexor sublimis. In the inferior third it has the same tendons on either side, whilst it rests upon the flexor longus pollicis, pronator quadratus, and radius. It is accompanied throughout by venæ comites.

To tie the radial artery.—The vessel is readily secured throughout its course, and any incisions made through the integument along the margin of the supinator or its tendon would reach it, but its deligation on the upper third is only required in cases of wound, which, in such instances, would be enlarged, and the vessel tied above and below the point of injury. The vessel is liable to several irregularities, the most common of which is a high origin from the brachial, when it lies often merely subcutaneous and can be seen pulsating throughout its course.

Relations of the ulnar artery in the forearm.—Arising at the bifurcation of the brachial, it runs

obliquely downwards, on the ulnar side of the arm towards the radial side of the pisiform bone, and in its upper third it is covered by the pronator teres, flexor carpi radialis, palmaris longus, and flexor sublimis, and having on its inner side the flexor carpi ulnaris, on its outer the flexor sublimis, and resting on the brachialis anticus. In the lower two-thirds, it is covered in by the fasciæ; on its inner side are the flexor carpi ulnaris and ulnar nerve, on its outer the flexor sublimis, and it rests on the flexor profundus; venæ comites accompany it throughout. This vessel occasionally arises high up, when it also lies immediately beneath the integument and fasciæ, uncovered by muscles. The same remarks, with regard to tying it in the upper third of the arm, may be made as have been in the case of the radial. It is very difficult to secure in its upper third, owing to being so covered in by muscles.

The *nerves* of the forearm are cutaneous and deep, the former being branches of the external and internal cutaneous as far as the wrist, of the lesser internal cutaneous and musculo-spiral, and in the lower third of the ulnar and radial.

The musculo-spiral enters the forearm between the brachialis anticus and supinator longus, and after breaking up in the supinator brevis is distributed to the extensors and supinators; the median enters the forearm between the two heads of the pronator teres, and is accompanied by a vessel, the *comes nervi mediani*, which is occasionally of considerable size, and may form one of the chief supplies to the palm; the ulnar enters the forearm between the two heads of the flexor carpi ulnaris, and accompanies the ulnar artery.

In amputation through the upper third of the forearm the flaps would contain the structures as follows:— In the *anterior*, integument and superficial veins and nerves, the flexor carpi radialis, supinator longus, palmaris longus, flexor carpi ulnaris, extensor carpi radialis longior, pronator teres, flexor sublimis and profundus, and the radial, ulnar, and anterior inter-

osseous vessels and nerves. The *posterior*, the extensor carpi radialis brevis, supinator brevis, and the ulnar and common extensor of the fingers, with the posterior interosseous vessels and nerves, integuments, and superficial veins and nerves. The vessels requiring ligature are the radial and ulnar, which will be found just beneath the integument, the anterior and posterior interosseous, which retract along the interosseous membrane, and perhaps the comes nervi mediani.

In performing the flap amputation the bones should be placed midway between pronation and supination ; and in cases of simple fracture of one or both bones, the same position must be maintained, as they are then most nearly parallel and furthest separated from each other, and there is less chance of any union between them. Moreover, owing to the tendency to motion that exists between these bones, a false joint may be the result unless accurate adaptation and perfect rest be maintained.

The fractures which occur in the forearm are those affecting either one or both bones and their processes. If the coronoid process be fractured—a rare accident, dependent on muscular action or dislocation—that amount of flexion performed by the brachialis anticus is necessarily lost ; symptoms of fracture of the olecranon are obvious, and the powerful action of the triceps in separating the fragments accounts for the rarity of bony union ; moreover, the articulation is generally opened. If the neck of the radius be fractured, a result of direct violence, the diagnosis is obscure, and must be deduced from the want of power of *voluntary* pronation and supination.

The *action of the muscles* of the forearm upon fragments is well marked in such a case as fracture of the shaft of the radius alone. Thus, supposing it broken about its centre, the upper fragment is drawn forwards by the biceps, inwards by the pronator teres ; the lower fragment is pronated and drawn downwards and inwards by the pronator quadratus, and its styloid process

tilted upwards by the supinator longus. In fractures of both bones the action of the muscles often causes great deformity.

SURGICAL ANATOMY OF THE REGION OF THE WRIST.

Surface markings.—Beneath the integument are seen the cutaneous veins and the tendons of the muscles acting on the wrist and fingers, the *anterior* ones being most evident in flexion of the hand or clenching the fist, especially the palmaris longus and flexor carpi radialis; the *posterior*, in extension of the wrist or fingers, and in extension of the thumb. The position of the styloid processes of the radius and ulna can be felt, the former lower down than the latter; the relation of these processes, however, is altered during pronation and supination. In front of the styloid process of the radius is the root of the thumb and prominence of the scaphoid, and on the inner side is the pisiform bone, with the tendon of the flexor carpi ulnaris attached to it. The pulsations of the radial and ulnar arteries can be easily felt and generally seen; the former on the radial side of the flexor carpi radialis; the latter on the radial side of the flexor carpi ulnaris.

Topography.—Beneath the skin is the subcutaneous cellular tissue, free from fat, and lying in it are the cutaneous vessels, nerves, and lymphatics. The aponeurosis is a continuation of that forming the sheath of the muscles of the forearm, which is remarkable at the wrist as being very strong, and affording special channels for the passage of the tendons of the muscles of the forearm. It consists of two portions—an anterior, very thick and strong (anterior annular ligament), continuous with the deep fascia of the forearm, which is attached to the pisiform, unciform, radius, scaphoid and trapezium, receiving an expansion of the tendon of the palmaris longus, and forming an arch between the thenar and hypothenar regions; and a posterior, dense, and formed of circular and longitudinal bundles

of tissue attached to the ulna, cuneiform, pisiform bones, to the radius, and to the several eminences on its dorsal aspect, which separate the extensor tendons, and thus form six compartments, each lined with a separate synovial membrane.

Anterior region of wrist.—The first layer of structures beneath the integument and aponeurosis of the wrist, followed from the radial towards the ulnar side, consists of—the supinator longus, the radial vessels, the flexor carpi radialis and palmaris longus,

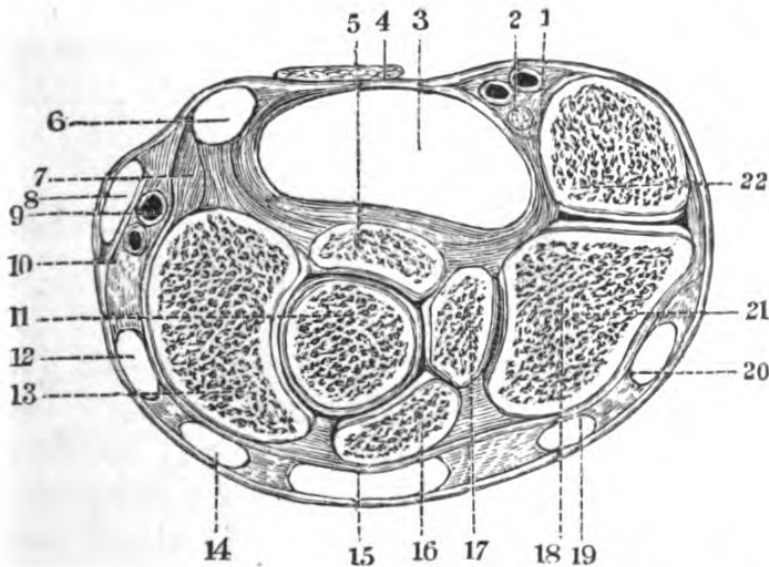


Fig. 35.—Transverse Section of Wrist, through the Middle of the Pisiform Bone.

1, ulnar vessels; 2, ulnar nerve; 3, sheath of flexors sublimis and profundus digitorum and flexor longus pollicis, enclosed by true annular ligament; 4, cut tendon of palmaris longus; 5, semilunar bone; 6, sheath for flexor carpi radialis; 7, radial origin of annular ligament; 8, 10, sheath for extensor ossis metacarpi and primi internodii pollicis; 9, radial vessels; 11, os magnum; 12, sheath of extensor secundi internodii pollicis; 13, scaphoid; 14, sheath of extensor carpi radialis, longior and brevior; 15, sheath of extensor communis and indicator; 16, semilunar; 17, unciform; 18, 21, cuneiform; 19, sheath of extensor minimi digiti; 20, sheath of extensor carpi ulnaris; 22, pisiform.

the former of which perforates the denser portion of the annular ligament, the ulnar vessels and nerve, and the flexor carpi ulnaris. All these tendons have separate sheaths, derived from the annular ligament and

synovial membranes. The second layer consists of the flexor sublimis, enveloped in synovial membrane, and the median nerve, with its accompanying artery. The third consists of the flexor longus pollicis and the flexor profundus digitorum, having their synovial sheaths in common with the superficial flexor, and close on the bone are the carpal branches of the radial and ulnar.

The posterior region.—Between the skin of the back of the hand and the fascia are a number of superficial veins and cutaneous nerves, derived

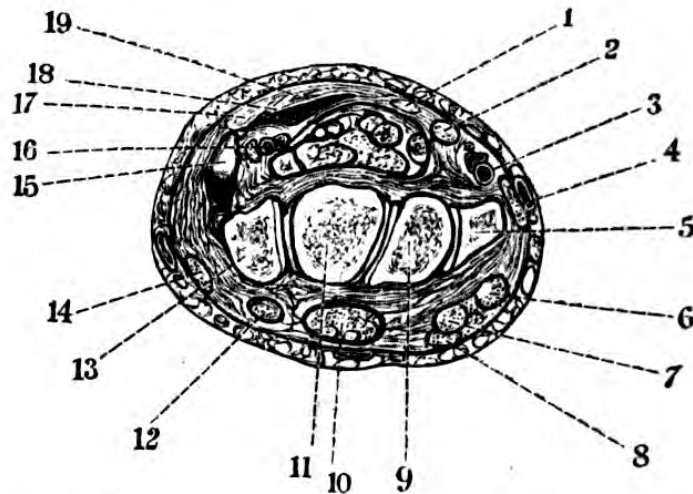


Fig. 36.—Section of Carpus, through the first row of carpal bones (one-half).

- 1, palmaris longus; 2, flexor carpi radialis; 3, radial vessels; 4, supinator longus; 5, radius; 6, extensor carpi radialis longior; 7, extensor carpi radialis breviar; 8, extensor longus pollicis; 9, scaphoid; 10, extensor communis digitorum; 11, semi-lunar; 12, extensor minimi digiti; 13, cuneiform; 14, extensor carpi ulnaris; 15, pisiform; 16, ulnar vessels and nerve; 17, flexor carpi ulnaris; 18, flexor brevis minimi digiti; 19, anterior annular ligament. (The flexors sublimis and profundus occupy the unfigured space.)

from the radial and dorsal branch of the ulnar. Beneath these is a strong fibrous membrane, apparently continuous with the dorsal portion of the annular ligament. There is a deeper layer, covering the bones and interossei, which is blended with the palmar aponeurosis laterally, the dorsal tendons pass between

these layers. Beneath the annular ligament are the six compartments for the following tendons, beginning on the radial side:—(1) extensores ossis metacarpi and primi internodii pollicis; (2) extensores carpi radialis, longior, and brevior; (3) extensor secundi internodii pollicis, crossing the two last mentioned very obliquely; (4) extensores digitorum and indicis; (5) extensor minimi digiti; (6) extensor carpi ulnaris.

The tendons of the extensor muscles, having arrived at the metacarpo-phalangeal articulation, receive the tendons of the lumbricales and interossei, whilst at the first pharyngeal joint they divide into three fasciculi, the central one being inserted into the base of the second phalanx, and the two lateral passing on and reuniting, are inserted into the base of the unguis. They have no distinct synovial sheaths.

The radial artery at the wrist can be felt or seen beating between the tendons of the flexor carpi radialis and supinator longus, where it is quite superficial and easily secured. Accompanied by venæ comites, it winds round the outside of the wrist, to gain the first interosseous space, when it enters the palm between the two heads of the first dorsal interosseous, and is crossed by the extensors of the thumb. It is readily secured at the base of the well-marked hollow formed by these muscles. In disarticulation of the metacarpal bone of the thumb it stands a chance of being divided, but if the knife be kept close to the bone it can be avoided. The most important branch of the radial is the superficial volar, which ordinarily lies subcutaneously, and completes the superficial arch. The other branches given off at the wrist supply the carpus and dorsal aspects of the thumb and first finger.

The ulnar artery, at the wrist, lies with its venæ comites, on the radial side of the flexor carpi ulnaris, and with its nerve to its inner side.

Articulations of the wrist-joint.—These are the inferior radio-ulnar, the radio-carpal, which exist between the lower end of the radius, and the scaphoid, and semi-

lunar bones. The synovial membrane of this articulation is also extended over the cuneiform bone and the inter-articular fibro-cartilage between the ulna and that bone; the inter-carpal and carpo-metacarpal joints, which include the anterior articular surfaces of the cuneiform, semilunar, and scaphoid, the entire unciform, os magnum, and trapezoid, with the bases of the four inner metacarpals, have a common synovial membrane, whilst the pisiform and the trapezium have one each. Of these articulations the most important to the

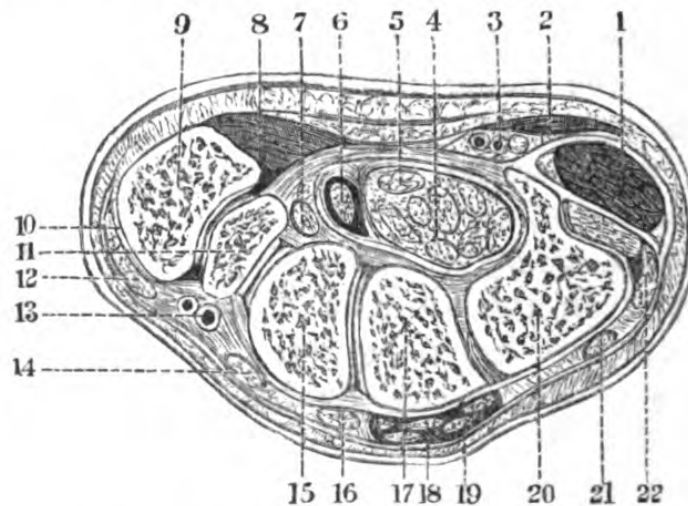


Fig. 37.—Section of Carpus through the middle. (Two-thirds.)

1, hypothenar muscles; 2, palmaris brevis; 3, ulnar vessels and nerve; 4, flexor sublimis and profundus; 5, median nerve; 6, flexor longus pollicis; 7, flexor carpi radialis; 8, thenar muscles; 9, base of first metacarpal bone; 10, extensor ossis metacarpi pollicis; 11, trapezium; 12, extensor primi internodii pollicis; 13, radial vessels; 14, extensor carpi radialis longior; 15, trapezoid; 16, external carpi radialis brevior; 17, os magnum; 18, extensor indicis; 19, extensor communis digitorum; 20, unciform; 21, extensor minimi digiti; 22, extensor carpi ulnaris.

surgeon is the radio-carpal, as dislocation of the hand and carpus from the radius, either backwards or forwards, takes place here. Moreover, amputation is occasionally performed at this joint.

Fracture of the radius just above the articulation (Colles's fracture) is almost always transverse, and in young subjects the lower epiphysis is occasionally separated. In these injuries the deformity is well marked;

the result of the combined action of the supinator longus, extensors of thumb, and radial extensors of the wrist causes the lower fragment to make a partial rotation on its transverse axis.

In examining the lower end of the forearm, in

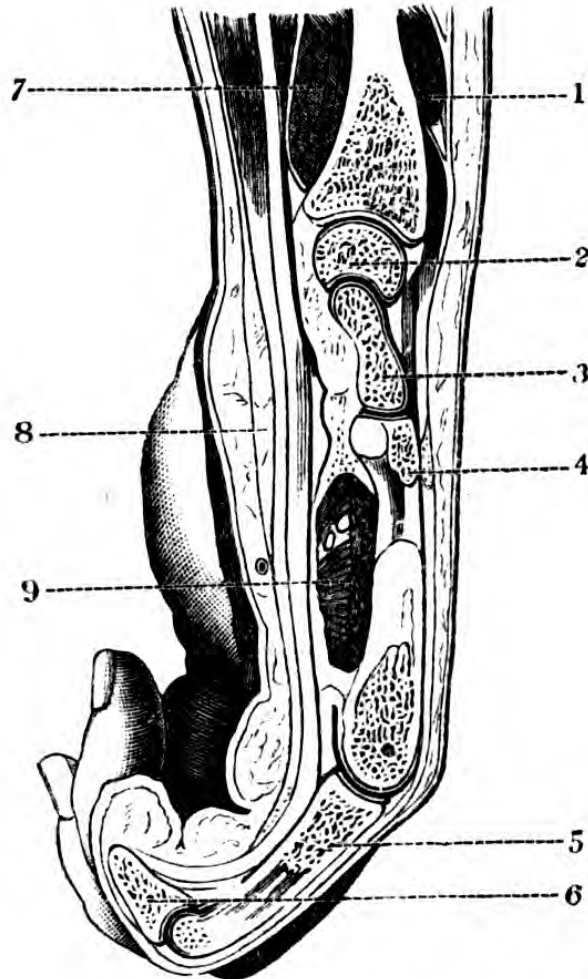


Fig. 38.—Longitudinal Section of the Wrist-Joint through the Radius and Middle Finger. (One-half.)

1, extensor primi internodii pollicis; 2, semi-lunar bone; 3, os magnum; 4, middle metatarsal bone; 5, first phalanx; 6, second phalanx; 7, pronator quadratus; 8, annular ligament; 9, adductor pollicis.

cases of injury, it must be remembered that the *head* of the ulna is prominent in *pronation*, and its *styloid* process in *supination*, owing to the rotation of the radius at its inferior radio-ulnar articulation.

Amputation at the wrist-joint may be performed

either by a semilunar dorsal flap, and an anterior, formed from the palm, or by rectangular flaps. The knife may get notched against the pisiform bone, so that some little neatness is necessary in avoiding it. The styloid processes of the radius and ulna require removal, and the vessels which would be ligatured are the superficialis volæ, some branches of the ulnar in palm, and perhaps an abnormal median.

For the operation of *excision* of the joint, an accurate knowledge of its component parts and relations is of the utmost importance, as this excision, like that of the ankle, reduces itself to an anatomical problem—viz., to remove the disease, and at the same time to preserve to the hand the tendons passing from the arm to it, and if possible to retain their functions.

SURGICAL ANATOMY OF THE HAND.

PALMAR REGION.

Surface markings.—This region extends from the wrist to the web of the fingers. It is concave, and presents two muscular eminences: one on the radial side, due to the mass of muscles acting on the thumb, called the *thenar* prominence, and the other due to muscles of the little finger, the *hypothelar*. The intermediate space is marked by several furrows, indicating the more marked flexions of the hand, one of which, the oblique central one, lies almost in the course of the superficial palmar arch. The deep palmar arch may be referred to the surface marking, by an imaginary line drawn between the centres of those circles, which form the bases of the thenar and hypothelar eminences. The root of each finger presents a longitudinal depression, placed in front of the superior extremity of the first phalanx. The bifurcation of the digital vessels takes place a little nearer the palm than the web of the fingers, and their course is subsequently along the under lateral aspects of the digits.

The skin is very thick and adherent and very sensitive, notwithstanding the horny condition it acquires in those who have much manual labour, and it is furrowed by ridges, in which lie the orifices of the sweat

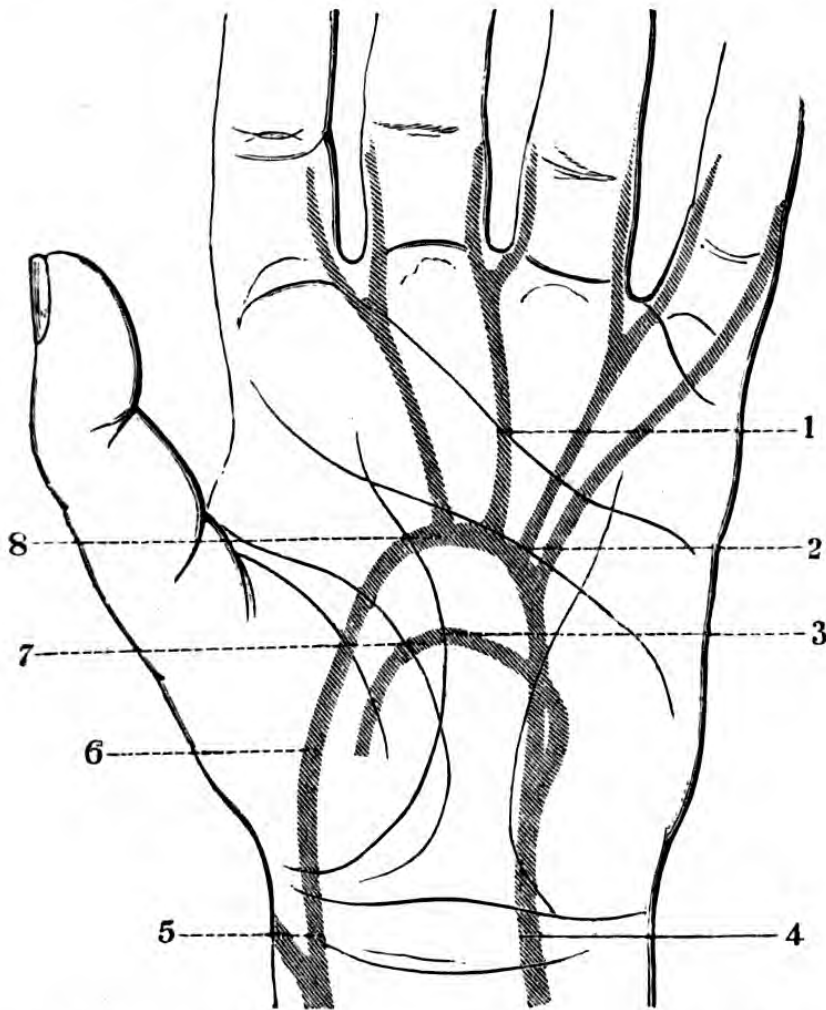


Fig. 39.—Relation of the Palmar Arches to the Folds of the Palm.

1, inferior fold; 2, middle fold; 3, superior fold; 4, ulnar artery; 5, radial artery; 6, superficialis volæ; 7, deep palmar arch; 8, superficial palmar arch.

ducts. The great vascularity of the skin of the palm predisposes this region to the occurrence of erectile tumours.

Topography.—The subcutaneous tissue is full of lobulated fat; beneath the fat and cellular tissue is the palmar fascia, particularly strong in its central fasci-

culus, and into the posterior portion of which is inserted the palmaris longus, opposite the heads of the metacarpal bones it divides into four slips, which slips themselves divide into two processes, attached to the sides of the first phalanx, giving passage to the flexor tendons, whilst the intermediate spaces transmit the digital vessels and nerves. Vertical septa pass down and divide the central set of palmar muscles from the thenar and hypothenar, the expansion of the palmar fascia covering which is very thin. It will be observed that there is a great difference between the superficial and deep surfaces of the fascia; the former being rough and coarse, whilst the deep is polished and shining, owing to the reflection on to it of the bursal tissue of the sheaths of the tendons. This palmar aponeurosis is frequently the seat of contraction which implicates the fingers. The little palmaris brevis muscle is attached to the skin and ulnar portion of the central portion of the aponeurosis.

On removing the palmar fascia the underlying structures are met with in the following order, dissecting down to the metacarpus. Commencing with the *thenar* eminence, beneath the fascial covering, lie the superficialis volæ artery, abductor pollicis, opponens pollicis, and radial head of short flexor of thumb, tendon of flexor longus pollicis, ulnar head of flexor brevis pollicis, princeps pollicis, and radialis indicis arteries, metacarpal bone of thumb, trapezium, and tendon of flexor carpi radialis.

In the middle segment of the palm, between the central fasciculus of the palmar fascia and the anterior annular ligament, with which the fascia is continuous, lie the superficial palmar arch and its digital branches, and the ulnar nerve, the median nerve, with its digital branches, the tendons of the flexor sublimis and profundus digitorum, with which latter are associated the lumbricales (these muscles enclosed in their synovial sheaths), lie under the annular ligament, next a layer of fibrous tissue separating these from the deep arch,

the deep branch of the ulnar artery, the adductor of thumb and interossei, whose tendons, with those of the lumbricales, pass into the general dorsal aponeurosis, and lastly, the metacarpus.

Beneath the palmar fascia of the *hypothenar* eminence lie the palmaris brevis, some cutaneous vessels and nerves, the abductor and flexor brevis, minimi digiti, the commencement of the superficial palmar arch, with its accompanying ulnar nerve, opponens minimi digiti, deep branch of ulnar artery and nerve, and fifth metacarpal bone.

The metacarpal bone of the thumb articulates with the trapezium by a saddle-shaped surface, and its shaft is considerably curved anteriorly; and in amputation at the metacarpo-trapezial joint, the secret of separating the bone neatly consists in abducting it forcibly and dividing the lateral ligaments, of which it is better to cut the inner one first. There are several methods of performing this operation, but that should always be chosen which will leave the greatest amount of *opposing* structure; as the muscular pad, resulting from the flaps, even though it loses its bony support, is of great importance when the hypothenar mass of muscle is intact, as it will in a great measure retain the power of approximation. Care must be taken to avoid wounding the trunk of the radial artery, as it passes between the two heads of the first dorsal interosseous muscle, if possible. The metacarpal bones of the fingers, having a common synovial membrane with their carpal bones, ought, if possible, to be removed without disarticulation, owing to the liability of general suppuration. There is some little difficulty attending amputation of the fifth metacarpal bone, owing to its double articulation with the os unciforme.

Synovial membranes of the palm.—These sheaths for the flexor tendons are arranged thus, generally:—
1. That of the flexor longus pollicis, which extends from the extremity of the thumb to about half-an-inch above the annular ligament. 2. That common

to the tendons of the flexor sublimis and profundus digitorum. It extends from about half-an-inch above the annular ligament, and is separated from the preceding by the median nerve. It expands in the palm, and has three prolongations; the two first are associated with the tendons of the index and middle fingers, and the third is common to the tendons of the ring and little fingers.

Abscess in the palm (*palmar abscess*), unless opened early, is liable to spread up the arm, along the synovial sheaths of the muscles, by passing beneath the

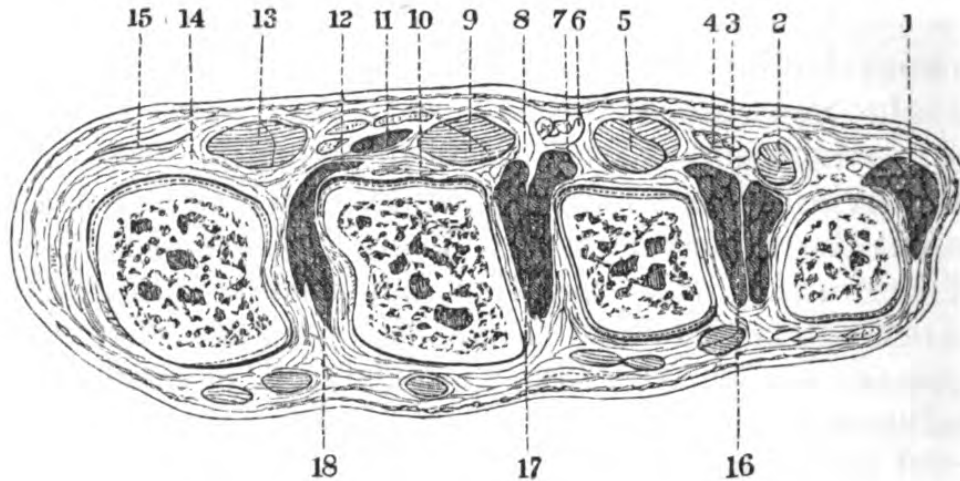


Fig. 40—Horizontal Section of the Hand through the Carpo-Metacarpal Joints.

1, hypothenar muscles; 2, 5, 9, 13, flexor tendons in the sheath; 4, 6, 11, lumbricales; 8, volar aponeurosis; 10, 14, deep volar aponeurosis; 3, 12, anterior carpal ligament; 16, 17, 18, interossei.

annular ligament, the excruciating pain attending it being due to the tenseness of the palmar fascia. In opening collections of pus in the palm, the position of the palmar arch must be recollected, and the knife should be entered upon the head or neck of the metacarpal bone, and not *between* the fingers, so that the bifurcation of the digital artery may be avoided.

The superficial palmar arch is formed by the ulnar

artery, which enters the palm on the radial side of the pisiform bone, and lies beneath the palmaris brevis and on the annular ligament. The ulnar nerve is on its inner side, and it is accompanied by venæ comites, opposite the position of the intercarpal articulation, it sends a branch to join the deep arch, accompanied by the deep branch of the ulnar nerve, penetrating between the abductor and flexor brevis minimi digiti. At about this point the superficial arch commences; its convexity being forwards, and extending to, and gradually lessening as it approaches the interspace between the ball of the thumb and the index finger, where it anastomoses with the superficialis volæ, and thus completes the arch. It supplies the opposed surfaces of the index and middle, of the middle and ring, and the entire little finger. The digital branches arise from the arch by short common trunks, branching in the web of the fingers, and at this spot communicating branches are given off to the deep arch. The superficial arch is covered by the skin, subcutaneous cellular tissue, and by the palmar fascia, and is posteriorly in relation with the superficial and deep flexors, and the digital branches of the median and ulnar nerves, the lumbricales and bursal tissue of the flexor tendons.

The deep palmar arch is formed by the radial artery, which enters the palm by the first interosseous space, between the two heads of the first dorsal interosseous muscle, and takes a direction from without inwards, nearly transversely, beneath the flexor brevis and adductor pollicis—where it gives off the princeps pollicis and radialis indicis, which supply the thumb and radial side of the index finger—towards the base of the metacarpal bone of the little finger, at which point it anastomoses with the deep branch of the ulnar. It gives off interosseous branches and perforating branches, which pass backwards between the muscular fibres of the three inner interossei, and inosculate with the dorsal interosseous branches. The arch is

completed by its inosculation with the communicating branch of the ulnar artery.

The structures which lie between the deep and superficial arches are, the flexor tendons of the fingers and their sheaths, the lumbricales, part of the flexor brevis pollicis, and the muscles of the little finger. The deep branch of the ulnar nerve accompanies the deep arch. Beneath it are the carpal ends of the metacarpal bones and the interossei muscles. The

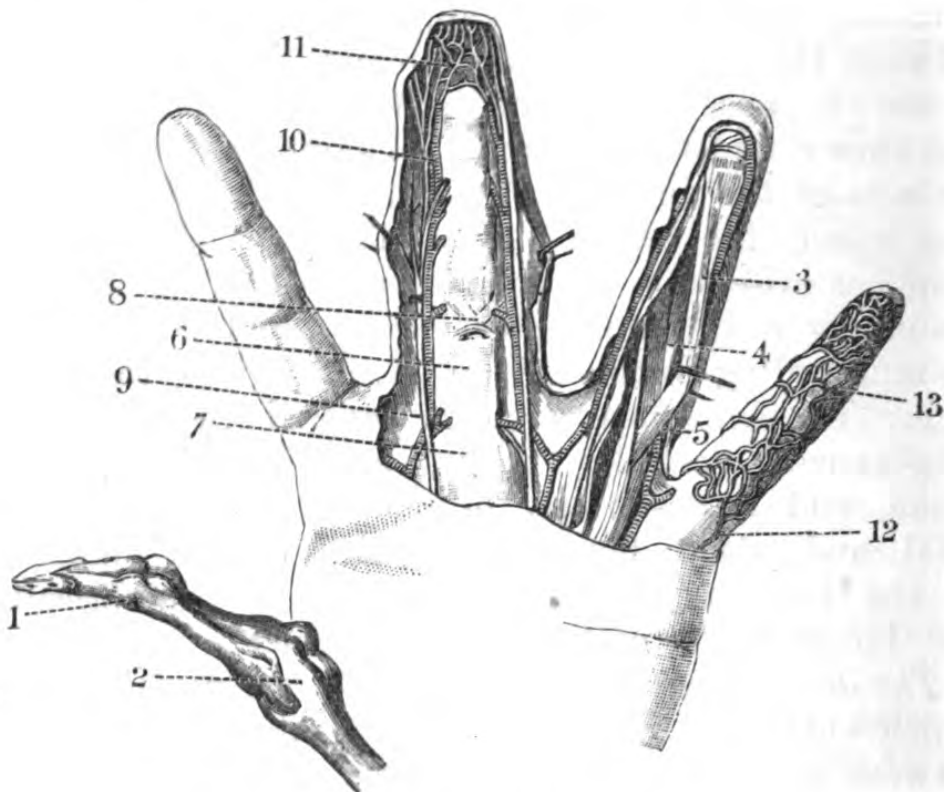


Fig. 41.—Anterior Aspect of Fingers.

1, 2, lateral ligaments; 3, flexor profundus digitorum; 4, flexor sublimis; 5, cut edge of theca; 6, sheath of flexors; 7, point of commencement of theca; 8, crossed fibres of theca; 9, digital nerves; 10, digital vessels; 11, termination of digital vessels and nerve; 12, 13, arrangement of veins.

deep arch is situated about half-an-inch nearer the wrist than the superficial arch.

In wounds of the palmar arch, if ligature of the radial and ulnar fail, the circulation is probably carried

on by an enlarged anterior interosseous or comes nervi mediani, and ligature of the brachial must be had recourse to.

Bursal swellings are commonly met with in association with the synovial sheaths of the flexor tendons in the palm, and generally communicate beneath the annular ligament, with the continuation of these sheaths in the forearm.

In the *fingers* the skin is very thick, particularly on the palmar aspect, highly vascular, and freely supplied with nerve-fibres. The subcutaneous tissue contains a good deal of fat; beneath this tissue is the sheath or theca of the flexor tendons, an osseo-fibrous canal, formed by the phalanges and a dense tube of fibrous tissue, disposed in circular and oblique bands, very thin immediately opposite the flexures, and perforated at the roots of the fingers for the passage of vessels and cellular tissue. The sheath is very thin on the palmar aspect of the unguis phalanx, and purulent infiltration into it is common at this point. The flexor tendons which lie in the sheath are those of the flexor sublimis (*perforatus*) attached by two slips to the sides of the second phalanges, and those of the flexor profundus (*perforans*) which divides them, and is inserted into the base of the unguis. The canal is lined with a synovial membrane, which is reflected on to the tendons. Slender tendinous filaments, called *vincula*, connect these tendons to the walls of the canal. On the dorsum there is a strong aponeurosis formed by the extensor tendons, further strengthened by the expansion of the interossei and lumbricales. The common extensor passes on to the second phalangeal articulation, opposite which it divides into three fasciculi, the central one being inserted into the base of the second phalanx, whilst the two lateral slips reunite and pass on, to be inserted into the base of the unguis.

The synovial sheaths of the flexor tendons of the thumb and little finger communicate with the common sheath, whilst those of the other three do not, a fact

which accounts for the greater frequency of suppuration in the common sheath when whitlow occurs in either of them.

In *excision* of the phalangeal articulations it is necessary to retain as much as possible of the dorsal aponeurosis, in order that the power of extension may be afterwards preserved. In *disarticulation* of a phalanx, it must be remembered that immediately the lateral ligament is divided the joint is opened, and

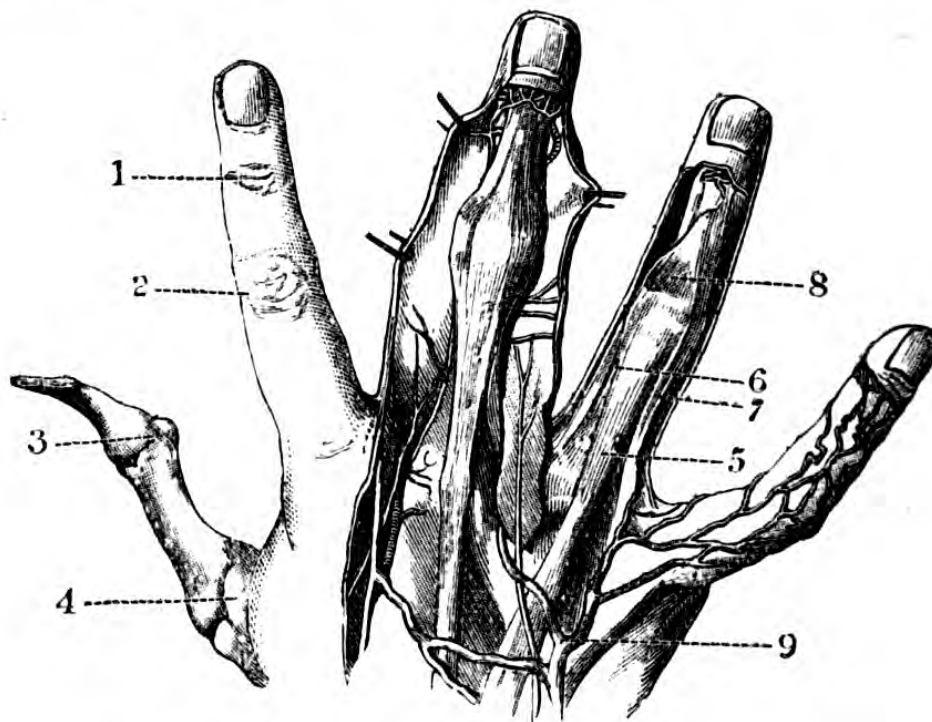


Fig. 42.—Dorsal Aspect of Fingers. (One-third.)

- 1, 2, digital articulations and their corresponding skin folds; 3, 4, lateral ligaments; 5, common extensor tendon; 6, 7, lumbricales and interossei tendons; 8, splitting of extensor tendon; 9, dorsal ulnar vein.

that this lateral ligament does not coincide with the palmar fold of the digit, but is a little in front of it, so that the guide for entering the knife is the second fold in the skin seen on the dorsal aspect of the joint.

The *vessels* supplying the fingers, with the thumb, are derived from the digital branches of the radial and ulnar arteries. The arteries anastomose very freely in

the pulp and matrix of the nail. The veins accompany the arteries and pass posteriorly, and form a considerable plexus, passing along the back of the fingers into the veins of the back of the hand.

The digital *nerves* are derived from the radial, median, and ulnar. The branches of the radial are supplied to the posterior surfaces of the thumb and index, middle, and ring fingers; those from the median to the palmar surfaces of the same digits, and those from the ulnar to the inner half of the ring and both sides of the little finger.

Dislocation of the first phalanx of the thumb is difficult of reduction, and if reduced, of being maintained in position, owing to the great power exerted by the mass of muscles forming the ball of the thumb, and to the fact that when the phalanx lies on the dorsal aspect of the metacarpal bone, the narrow head of the latter becomes constricted by the two terminal attachments of the flexor brevis pollicis, the tendons of which are further strengthened by the conjoined insertion of the adductor and abductor.

CHAPTER V.

SURGICAL ANATOMY OF THE ABDOMEN.

ON commencing the surgical anatomy of the abdomen, it is advisable to point out the relations of the contents of this cavity to the surface of the body, considerations of importance to the surgeon as aids to diagnosis.

Relations of the viscera to the abdominal parietes.—In order to facilitate the description of the abdomen, it can be mapped out by certain arbitrary lines into nine regions, to which the contained viscera can be referred—a method of reference of considerable use in a certain way, but of no great value as bearing upon the subject of Surgical Anatomy, properly so called.* These lines are vertical and horizontal; the vertical passing from the seventh costal cartilage to the middle of Poupart's ligament, on either side, and the horizontal through the level of the ninth costal cartilages, and crests of the ilia. The regions thus indicated are called the—

Right hypochondriac.	Epigastric.	Left hypochondriac.
Right lumbar.	Umbilical.	Left lumbar.
Right iliac.	Hypogastric.	Left iliac.

The *epigastric* region contains the left lobe of the liver, part of the anterior surface of the stomach with

* For a detailed account of the relations of the viscera to the surface and each other, the reader is referred to Prof. Braune's "Atlas of Topographical Anatomy after sections of frozen bodies." (Translated by Author.)

the œsophageal and pyloric orifices, the gastro-hepatic omentum, and the foramen of Winslow. Behind the stomach is the lesser bag of the peritoneum, second and third portions of the duodenum, the pancreas, cœliac axis and its branches, the superior mesenteric artery and solar plexus, the aorta and vena cava, and vertebral column.

The *right hypochondriac* region is almost entirely filled up by the right lobe of the liver; it contains also the fundus of the gall bladder, a portion of the transverse colon, the tip of the right kidney, and the supra-renal capsule.

The *left hypochondriac* region is almost entirely filled by the greater cul-de-sac of the stomach, the spleen and gastro-splenic omentum, and occasionally a small portion of the left lobe of the liver. Inferiorly it includes the tip of the left kidney and supra-renal capsule, a small portion of the descending colon, and the tail of the pancreas.

The *umbilical* region contains the great omentum, the transverse colon, the mass of the small intestine, the mesentery, the aorta, and inferior vena cava.

The *lumbar* region contains convolutions of the small intestine, the ascending colon on the right and the descending on the left, the kidneys and ureters, and a quantity of cellulo-fatty tissue.

The *hypogastric* region contains the great omentum, the small intestine, and the bladder, if distended.

The *iliac* region contains the cœcum in the right, and the sigmoid flexure in the left, and convolution of the small intestine.

It may be stated that in the female the gravid uterus occupies several regions in succession, according to the period of gestation.

The regions of the abdomen will be considered under the heads of—

(1) Abdominal parietes; (2) Such portions of the abdominal cavity as are of practical surgical importance; (3) Pelvis.

ABDOMINAL PARIETES.

The region of the abdominal parietes may be divided as follows—(1) Antero-lateral; (2) Inguinal; (3) Crural; (4) Lumbar.

(1) *Antero-lateral region of the abdomen.*—*Topography.*—The skin is very lax (excepting at the umbilical depression), beneath it is the subcutaneous cellular tissue and fascia, which latter may be divided into as many lamellæ as the skill of the dissector permits of; two of which, however, may be considered as ample for all surgical purposes, the superficial and the deep. The superficial lamina is continuous with that of the thigh, and glides freely over Poupart's ligament, the deep one is firmly attached to it. The position of these laminae are clinically interesting, from the fact that fluid or gas situated between them will descend towards the thigh, but supposing the effusion is behind the deeper layer it is arrested by Poupart's ligament. These fasciæ are continuous, and interlace on either side of the linea alba, which is seen as a well-marked depression, and some of their fibres are attached to it, and in the lower portion of the abdomen pass downwards to the scrotum, strengthening the suspensory ligament of the penis, and giving origin to the dartos (*vide* Inguinal Region). In the fat existing between these laminae lie numerous cutaneous branches of the superficial epigastric and intercostal vessels and nerves. A loose layer of cellular tissue separates the deep layer of fascia from the external oblique muscle and its aponeurosis. Next in order is the external oblique muscle, the fibres of origin of which interdigitate with those of the serratus magnus and latissimus dorsi, and its aponeurosis passes inwards, to be inserted into the iliac spine, the linea alba, and iliac and pubic crests. The fibres of this muscle are oblique from above downwards. Beneath it lies the internal oblique, separated from it by a thin cellular membrane, derived originally from the

lumbar aponeurosis, and in which lie filaments of the lower intercostal and last dorsal nerves; its tendon is inserted into the cartilages of the lower ribs, the linea alba, and ilio-pectineal line, enclosing the rectus for its upper two-thirds behind, and passing in front of it entirely for the remaining third. The fibres run in the contrary direction to those of the former muscle. The transversalis is separated from it by a thin cellular membrane, and having its origin from the lower ribs and lumbar aponeurosis is inserted along the linea alba and by the conjoined tendon, the upper three-fourths passing behind the rectus, and blending with the tendon of the internal oblique, whilst its lower fourth passes in front of it. It is separated from the peritoneum by the transversalis fascia. The rectus abdominis passes vertically down the abdominal parietes, on either side of the linea alba, enclosed in a partial sheath, and having three or four tendinous intersections, which are very readily seen beneath the skin when the muscle is in action. Below it is a little muscle, the pyramidalis, attached below to the pubis and inserted into the linea alba, at the junction of the middle with the lower third of the rectus. The continuity of the thin aponeurotic laminae, which exist between the abdominal muscles, with the lumbar aponeuroses, accounts for the occasional pointing of lumbar abscess in the parietes, above Poupart's ligament, or at the edge of the rectus. The *deep epigastric* artery, with its veins, after passing between the peritoneum and transversalis fascia, gets behind it, and entering its fibres, freely anastomoses with the superior epigastric from the internal mammary, which vessel itself enters the rectus below the cartilages of the eighth or ninth ribs. Between the transversalis fascia and the peritoneum is the sub-peritoneal cellular tissue. The peritoneum itself closely lines this region of the abdominal wall, excepting for a short distance above the pubes, where its attachment is very lax—a circumstance taken advantage of in puncture of the bladder in this region.

The abdominal muscles are separated from one another by a lamina of cellular tissue, which favours the effusion of fluids, and the laxity of the sub-peritoneal layer explains reduction *en masse* or *en bloc* of a hernia, which instead of having been replaced *within* the peritoneal cavity, has been pushed back, unreduced, between either the muscles themselves or between the fascia transversalis and the peritoneum.

Operations for the removal of abdominal tumours and for paracentesis abdominis are performed in the mesial line, as the simple structure of the linea alba, presenting no *layers*, does not admit of infiltration into muscular aponeurosis or sheaths. In the operation of paracentesis the parietal layer of the peritoneum only would be involved; but in operations on an *ovarian cyst*, for example, both parietal and visceral are divided. In the case, however, of the incision through the parietes made for the application of ligatures to the iliac arteries, the abdominal muscles and fascia transversalis are divided, whilst the peritoneum is kept entire. The resilience of the walls of this region allows of the ready manipulation of its contents, with a view to diagnosis. Penetrating wounds are frequently followed by hernial protrusion, on account of the laxity of their cicatrices.

In the linea alba, between the two recti, is the *umbilicus*.

Umbilical hernia, of which there are several varieties, may be thus classified:—1. Congenital, which is a prolapse of the intestine into the cord, possessing no peritoneal covering. 2. In children, occurring from about the first to the fourth month, the coverings are the skin, the cicatricial membrane of the umbilical depression and the peritoneum; the fascia propria is so thin as to be almost unappreciable. 3. In adults, several varieties are met with as regards the shape of the opening and the contents. The opening may merely admit the finger tip, or the entire hand may be passed through it. As regards the coverings,

they are generally the same—skin, subcutaneous cellular tissue, cicatricial tissue of the umbilical aperture, fascia propria, sac, and sub-peritoneal cellular tissue. But these again may vary in texture, or in some cases be wanting.

The contents are most frequently omentum and the transverse colon, small intestine without omentum, or all these structures at the same time. In operating for strangulated umbilical hernia, it is of importance to divide the constriction downwards or inwards, and downwards or outwards and downwards. In adults the hernia invariably contains omentum, which must be pushed upwards, in order to get at the intestine.

SURGICAL ANATOMY OF THE INGUINAL REGION.

This important region is the seat of operation in cases of inguinal hernia, for ligature of the external iliac and epigastric arteries, and the pointing of abscesses of the iliac fossæ.

Surface markings.—This region (the inferior portion of the antero-lateral region of the abdomen) may be indicated superiorly by a line drawn from the anterior superior spine of the ilium to the mesial line of the body internally, and the mesial line itself below Poupart's ligament. Between the bony prominences, the anterior superior spine externally, and the crest of the pubes internally, is a curved furrow, with its convexity downwards, indicating the fold of the groin, and the position of Poupart's ligament. Just above the pubes can be felt the external abdominal ring, and the structures forming the cord are readily recognizable.

The student should pass his finger up into the external ring without using any force, by tucking up the scrotal tissue upwards along the cord, in order to ascertain under what positions of the leg the examination of the canal could be most readily made, and the exact relations of the structures composing it.

Topography. — The skin of this region is freely supplied with hairs, which must be carefully shaved

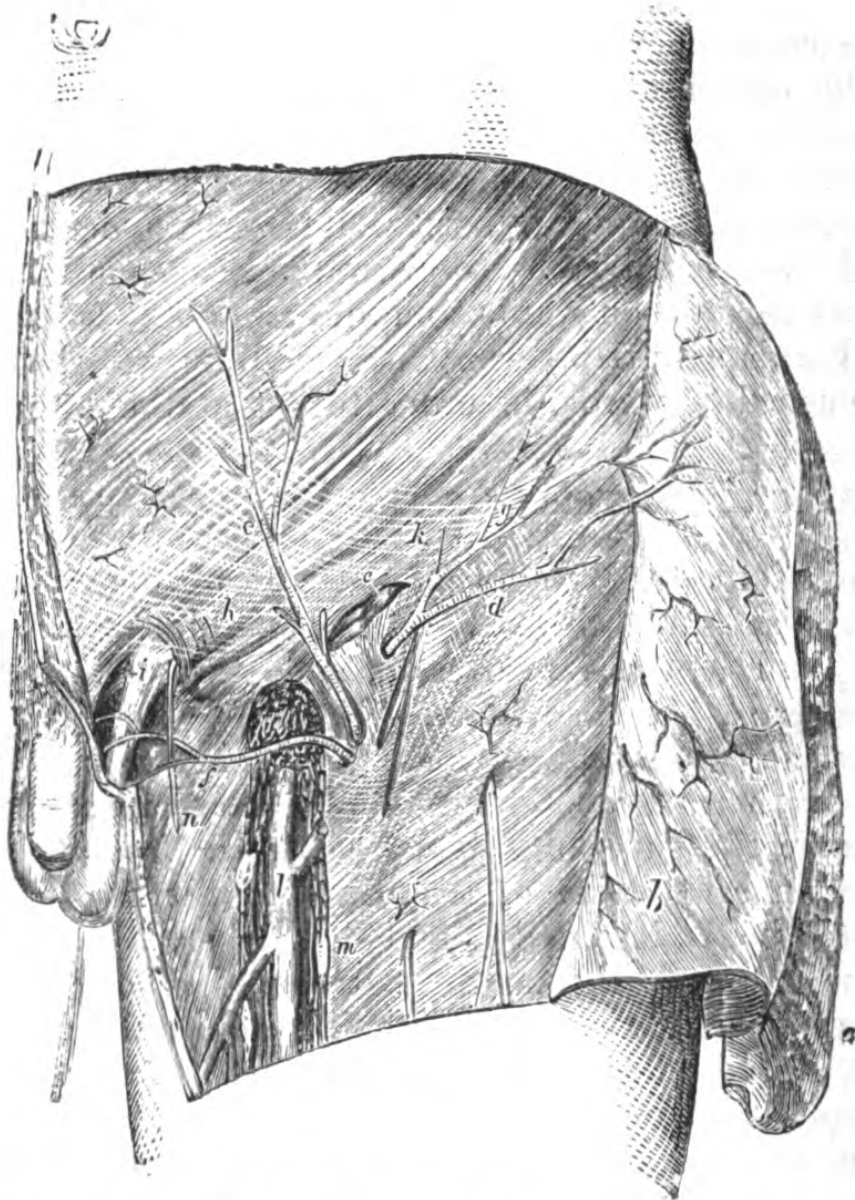


Fig. 43.—Superficial Dissection of the Inguinal and Femoral Regions.

a, superficial layer of fascia (reflected); *b*, deeper layer of fascia (reflected), the superficial vessels being left attached to the external oblique; *c*, inguinal lymphatic glands; *d*, superficial circumflex iliac artery; *e*, superficial epigastric artery; *f*, superior external pudic artery; *g*, Poupart's ligament; *h*, intercolumnar fascia; *i*, external abdominal ring; *k*, arciform fibres of external oblique; *l*, internal saphena vein; *m*, femoral lymphatic glands; *n*, ilio-inguinal nerve; *o*, saphenous opening.

off before an operation is undertaken. Beneath it is the superficial fascia, readily divisible into two layers, and between which lie the cutaneous vessels and lymphatics, the deep layer being closely attached to Poupart's ligament and to the crest of the ilium. The superficial layer of this fascia is freely moveable over the subjacent aponeurosis, a circumstance which is taken advantage of by the surgeon in making his incisions down upon a strangulated hernia, when, owing to this laxity, by pinching up a fold of integument and transfixing it, he obtains a linear incision, which does not include either sac or gut. It is, moreover, taken advantage of in introducing the needles in Wood's operation for the radical cure. Between these layers of fascia are the lymphatics, transmitting the ducts from the external genitals, the termination of the ilio-hypogastric and ilio-inguinal nerves, and three superficial branches of the common femoral artery—viz., the superficial epigastric, superficial circumflex iliac, and superficial external pudic, with their accompanying veins. In plastic operations for the relief of extroversion of the bladder, the superficial epigastric should be carefully preserved to nourish the flaps. Beneath the deep layer of the superficial fascia is the aponeurosis of the external oblique; its lower portion, by its union with the fascia lata and deep fascia, forms the *crural arch*, which extends from the anterior superior spine of the ilium to the spine of the pubes, having also an attachment to the ilio-pectineal line (Gimbernat's ligament). The attachment to the ilio-pectineal line is strengthened by a triangular band of fibres passing upwards and inwards towards the linea alba, behind the inner pillar of the external ring. It will be noticed that extension and abduction of the leg renders the crural arch tense, so that in the examination of the parts or in the application of the *taxis*, the external abdominal ring must be relaxed by flexion and adduction. The two *pillars* of the external ring are bound together by a set of aponeurotic fibres, which

interlace, more or less, over the whole of the inner part of this region, constituting the *intercolumnar bands*, from which a fascia is derived, forming a covering to the emerging cord—the *intercolumnar* or *external spermatic* fascia. It is the weakness or giving way of these bands which favours the hernial protrusion. The inner pillar of the ring is flat and ribband-shaped, whilst the outer is sickle-shaped and thick, and upon it the cord or round ligament rests. Beneath the aponeurosis of the external oblique is a cellular interval separating it from the muscular fibres of the internal oblique, and the *conjoined tendon* of this muscle and the transversalis, this latter passing in front of the rectus and pyramidalis to the linea alba and pubes: blended with the lower fibres of the internal oblique and transversalis are the fibres of the cremaster muscle, on which the ilio-inguinal nerve lies. Beneath the internal oblique is a second cellular layer separating this muscle from the fibres of the transversalis, which forms an arch over the cord, and beneath this arch is the spout-like prolongation of the transversalis fascia (*the infundibuliform*) investing it. Behind the transversalis and the rectus is the transversalis fascia, closely lining them, and here forming with the subperitoneal aponeurosis the posterior layer of the sheath of the latter muscle; in its lower fourth it is attached to the under surface of the crural arch, becoming continuous with the fascia iliaca. Beneath this fascia is the parietal layer of the peritoneum.

The position of the *deep epigastric vessels* can be easily seen, lying beneath the transversalis fascia and the peritoneum, and passing obliquely upwards and inwards, to gain the under surface of the rectus at about its lower third, and internal to the cord.

Before describing the inguinal canal, we must obtain a correct idea of the disposition of the peritoneum, and its method of application to the posterior aspect of the region, where we observe the three *fossettes* which play so important a rôle in the relations of inguinal herniæ.

These may be considered as external, middle, and internal. On examining the internal aspect of the region, it will be noticed that there are several struc-

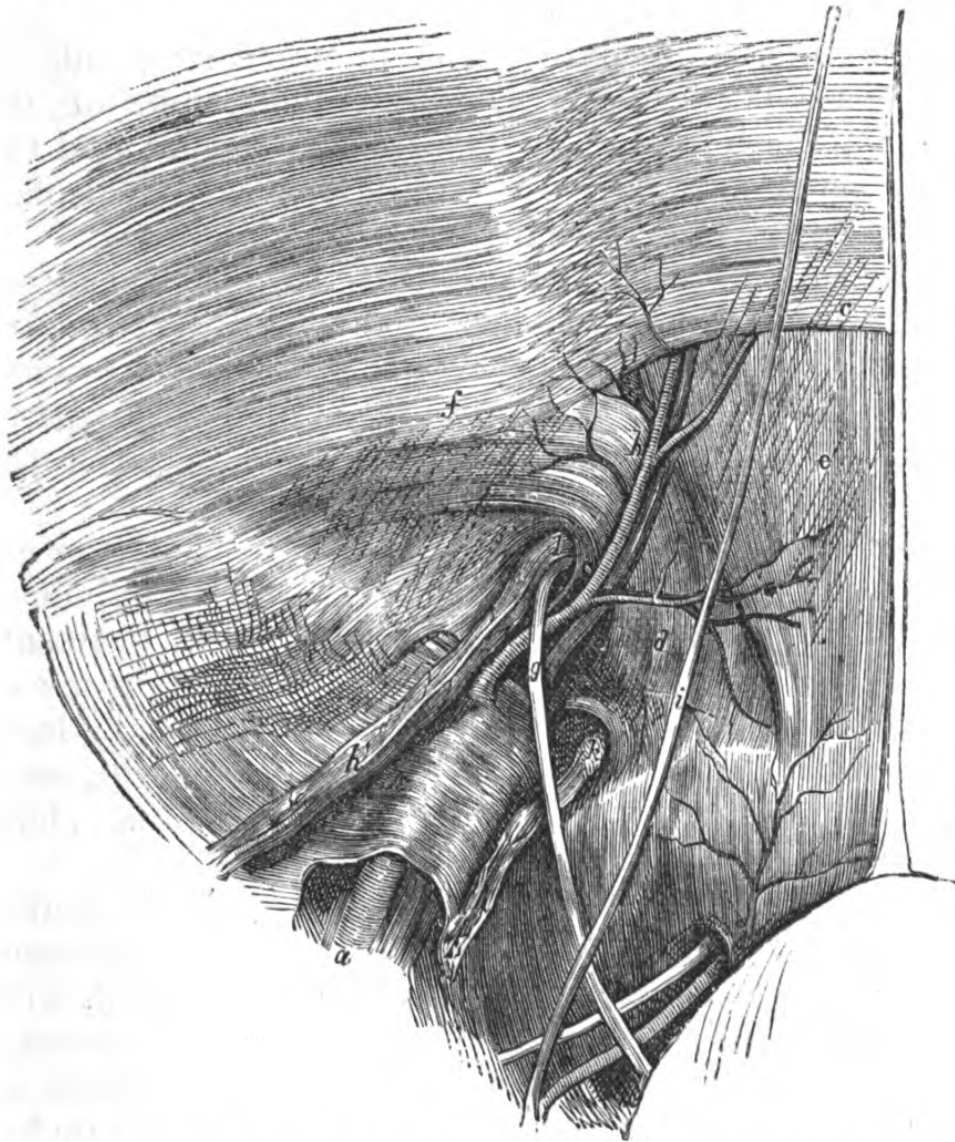


Fig. 44.—Dissection of the Lower Part of the Abdominal Wall from within, the peritoneum having been removed.

a, external iliac artery; *b*, epigastric artery; *c*, border of the posterior part of the sheath of the rectus (fold of Douglas); *d*, conjoined tendon in the triangle of Hesselbach; *e*, posterior surface of rectus; *f*, fascia transversalis; *g*, vas deferens; *h*, spermatic vessels; *i*, obliterated hypogastric artery; *k*, lymphatics in crural rings; *l*, internal abdominal ring.

tures lying beneath the peritoneum, which raise it, and they are the epigastric artery, the obliterated

umbilical artery, and the urachus, whilst between these are the fossæ above mentioned, and they correspond to the two orifices of the inguinal canal, the internal abdominal and external rings.

The internal fossette (supra-pubic) corresponds to the space between the symphysis and spine of the pubis. The external is the larger and deeper, and the peritoneum may be most readily stripped off, displaying the cord, which lies inferiorly and internally.

The position of the *internal abdominal* ring is recognized as a dimple-like depression in the peritoneum, indicating the closure of its vaginal process. Below this is a furrow showing the position of Poupart's ligament, and below this again a depression over the crural ring.

The cords of the obliterated hypogastric arteries are seen as ridges, passing upwards towards the umbilicus, forming the margins of the superior false ligaments of the bladder, and between them lie the remains of the urachus. Beneath the peritoneum is seen the loose subperitoneal fascia, in which lie the deep epigastric and circumflex ilii vessels, the latter running along the deep surface of the crural arch.

Parts concerned in inguinal hernia.—Inguinal hernia is described as being oblique or direct, with reference to the inguinal canal; and external or internal, with reference to its position to the deep epigastric vessels.

The *inguinal canal* is an oblique channel, about an inch and a half long in the male, and about two inches in the female, owing to the greater breadth of the pelvis, and its openings are the internal and external abdominal rings; *the relation of the internal or deep ring to the surface* is indicated by a point taken about half or three-quarters of an inch above the centre of Poupart's ligament, along a line at right angles to it. This internal ring is an oval opening in the fascia transversalis, transmitting the cord in the male and the round ligament in the female, and is bounded above and externally by the arched fibres

of the transversalis muscle, and internally by the deep epigastric vessels.

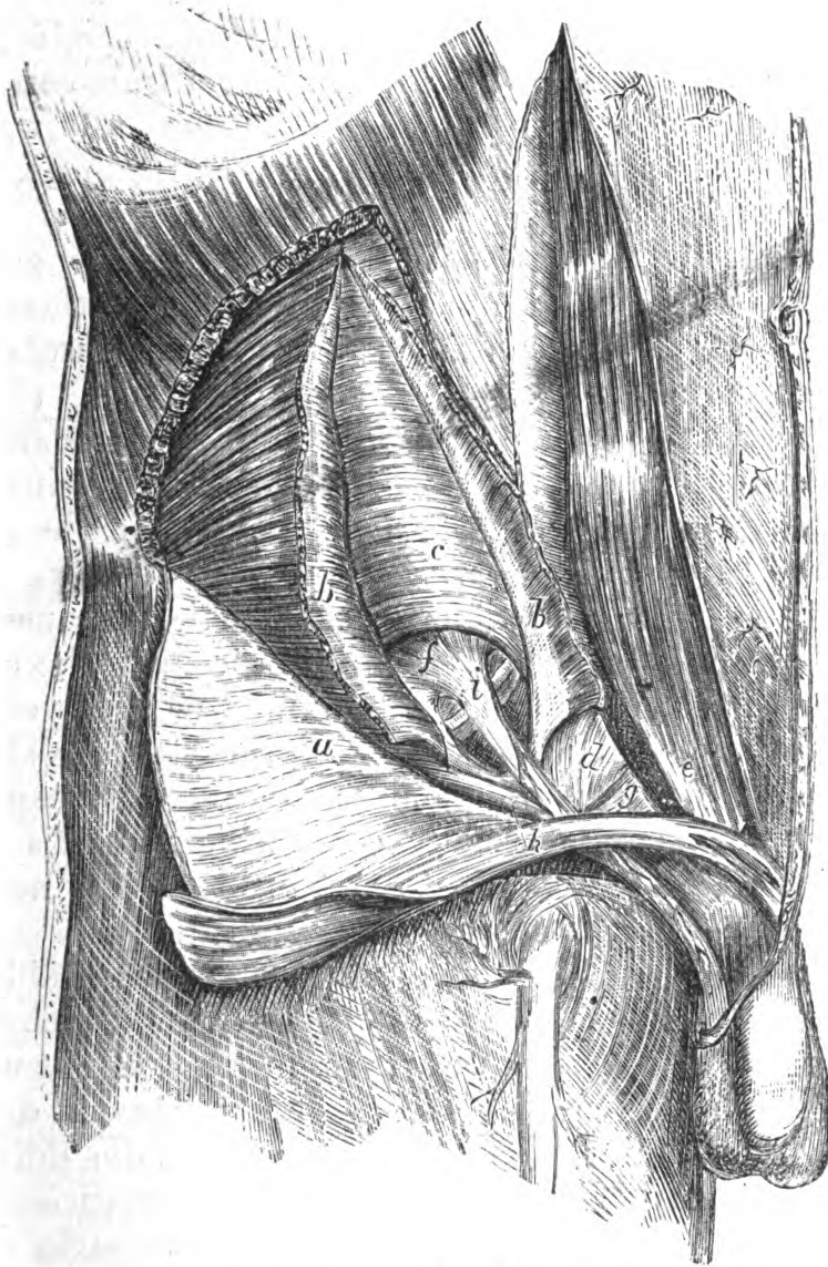


Fig. 45.—Dissection of the Inguinal Canal.

a, external oblique (turned down); *b, b*, internal oblique; *c*, transversalis; *d*, conjoint tendon; *e*, rectus abdominis, with sheath opened; *f*, fascia transversalis; *g*, triangular fascia; *h*, cremaster; *i*, infundibular fascia.

The boundaries of the inguinal canal are—In front, the integument and superficial fascia, the aponeurosis of external oblique, the internal oblique for its outer

third, and a small portion of the cremaster. *Behind*, the conjoined tendon, triangular fascia, transversalis fascia, subperitoneal fat, and peritoneum. *Above*, the fibres of the internal oblique and transversalis; and *below*, Poupart's ligament and the fascia transversalis.

Oblique or external inguinal hernia follows the course of the spermatic cord or round ligament, passing through both rings.

The coverings of an oblique inguinal hernia are the same as those of the cord—viz., from without inwards:—(1) Integument. (2) Superficial fascia. (3) Inter-columnar fascia. (4) Cremaster muscle. (5) Infundibuliform fascia. (6) Subserous cellular tissue. (7) Peritoneum (*sac*). If the intestine passes into the scrotum, it is called *complete*; if retained in the canal, *incomplete*, or *bubonocoele*.

In cases of strangulation, the constriction is caused by some portion of either of the rings, or if in the canal, by the fibres of the internal oblique or transversalis, and any incision for the relief of the stricture should be made *upwards*, to avoid wounding the deep epigastric vessels or spermatic cord, which in this form of hernia lie—the former to the inside of the neck of the sac, and the latter directly behind it.

Varieties.—Oblique inguinal hernia is liable to varieties, known as congenital, infantile, and encysted. In the *congenital* form the pouch of peritoneum which accompanies the cord and testis in its descent during foetal life remains patent, and the gut falls into this pouch, and thus lies in contact with the testicle. (In congenital hydrocele the condition of the parts is the same.)

In the *infantile* form, the peritoneal pouch is only partially obliterated, and the sac descends along the inguinal canal into the scrotum, behind the pouch; hence there are three layers of peritoneum in front of the gut and its proper investment—viz., two of the tunica vaginalis testis, and the sac itself.

Direct or internal inguinal hernia differs in its

course from oblique, in not passing through the inner ring, but through the space known as the triangle of Hesselbach, the boundaries of which are—*externally*, the epigastric artery ; *internally*, the outer edge of the rectus, and *inferiorly*, Poupart's ligament. This space is filled in on its inner two-thirds by the conjoined tendon, and for the rest by the fascia transversalis. Any hernial protrusion through this interval and emerging from the external ring, would have the

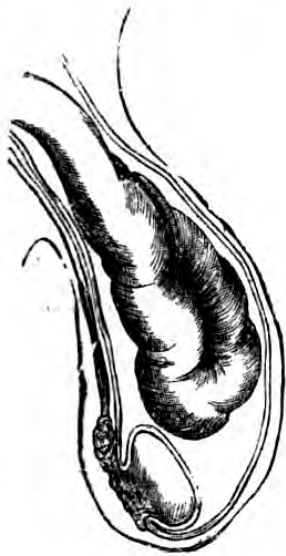

Fig. 46.

Diagram of a congenital hernia, the sac being continuous with the tunica vaginalis testis.

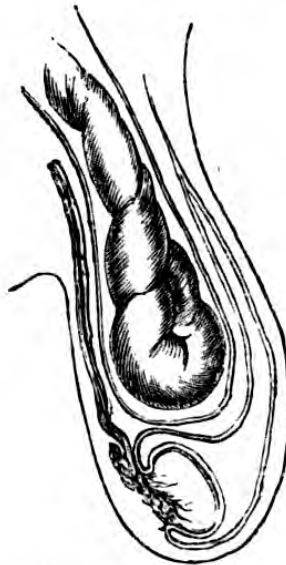


Fig. 47.

Diagram of an infantile hernia, showing the tunica vaginalis prolonged in front of the sac.

deep epigastric artery external to its sac, and the spermatic cord internal and posterior. This form of rupture may either force its way through the conjoined tendon, or push it before it.

Coverings of direct inguinal hernia.—The same as those already given in the case of the oblique variety, with the exception that the conjoined tendon takes the place of the cremaster, the infundibuliform fascia being replaced by that portion of the fascia transversalis behind or immediately contiguous to the conjoined tendon.

The seat of stricture, in strangulation, is either at the neck of the sac, at the external ring, or is due to the fissured edges of the conjoined tendon. The incision for its relief is to be made *upwards*.

The parts divided in operation for strangulated inguinal hernia would be those between the outer ring and the gut, and the sac, if so indicated by the nature of the case, and when reached, the constriction itself.

Structures to be avoided.—The deep epigastric vessels and the cord.

The *position of the deep epigastric artery with regard to the abdominal parietes* is pretty much that of the superficial epigastric vessels seen beneath the integuments, and its course is indicated by a line drawn from a point a little internal to the centre of Poupart's ligament to about the middle of the space between the umbilicus and symphysis pubis.

SURGICAL ANATOMY OF THE CRURAL REGION.

In works on Descriptive Anatomy this region is generally described and dissected as belonging to the lower limb; but as its surgical relations essentially concern those of the contents of the abdomen, and as it has so many points in common with it, besides forming, by its deep aspect, part of the abdominal parietes, it has been thought advisable to introduce it here, and to refer back to it again when describing the superior femoral region.*

The boundaries of this region are—*above*, the crural arch; *externally*, a line passing from the anterior iliac spine to the trochanter major; *internally*, the prominence of the adductor longus; and *below*, a line drawn through the point of meeting of the sartorius and adductors. These several muscular eminences enclose

* This plan has been adopted by Malgaigne, and latterly by Tillaux, and seems to the Author the most natural.

an irregular triangular space, sloping towards the centre, in which lie the common femoral vessels; it is the seat of crural or femoral hernia, which appears at the inner and upper part.

Topography.—Beneath the skin is the superficial layer of superficial fascia, continuous with that over the abdomen, containing a good deal of fat, in which lie the superficial circumflexa ilii, epigastric and external pudic vessels; filaments from the external, internal, and middle cutaneous, crural and ilio-inguinal nerves, lymphatic glands, and ducts. It will be noticed that the lymphatic ganglia in the axis of the thigh are those which become enlarged in ulcers or injuries of the lower limb, whilst the upper series, which lies in the fold of the groin, receive the lymphatics of the genital organs, and become affected in venereal complaints. Below this layer is the deep portion of the superficial fascia attached to Poupart's ligament, and to the margins of the saphenous opening, forming a spout-like prolongation over the internal saphena vein as it lies in this opening. That portion of the superficial fascia which closes in the saphenic opening, is called the *cribriform* fascia, from its numerous perforations, due to the passage of lymphatic ducts and the superficial vessels already named. The *fascia lata* is next seen, a dense aponeurotic structure, attached by an outer or iliac portion to the crest and anterior spine of the ilium; and blended with the lower edge of Poupart's ligament to the spine of the pubes and the ilio-pectineal line, where it unites with Gimbernat's ligament. This portion of the fascia lata forms a falciform process, which passes in front of the sheath of the vessels, and is the outer pillar of the saphenic opening. The inner portion, or pubic, is attached along the inferior outlet of the pelvis, and is there connected with the perineal fasciæ and penis, and passing behind the femoral vessels, becomes attached to the ilio-pectineal line, being thus connected with Gimbernat's

ligament, the falciform process of the iliac portion, the fascia iliaca, and the capsule of the hip-joint. It is through this opening that the internal saphena vein passes to join the common femoral vein.

The crural canal.—Below the fascia lata attached along Poupart's ligament is the anterior layer of the *sheath of the vessels*, a process of the fascia transversalis emerging from beneath the crural arch. The

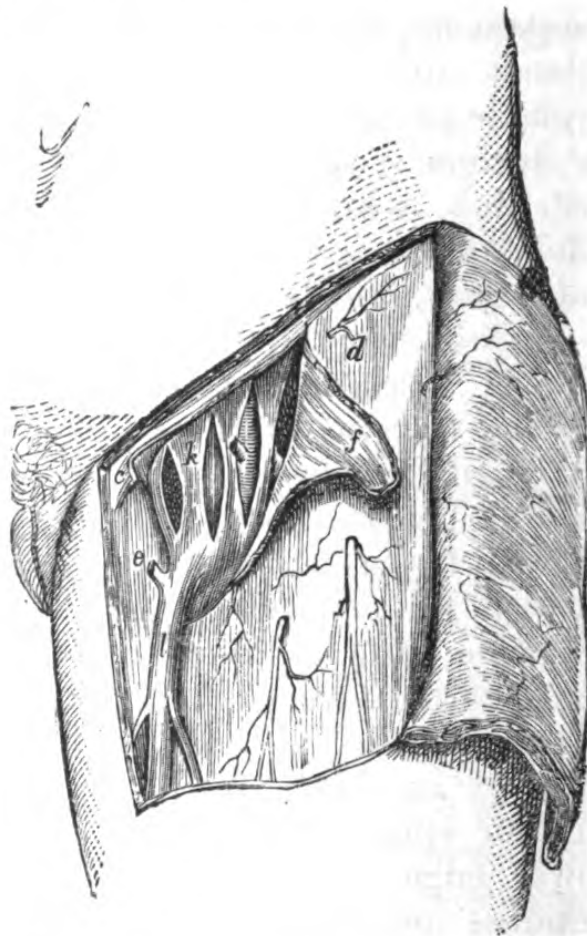


Fig. 48.—Crural Sheath laid open.

a, middle cutaneous nerve; *c*, placed to the inner side of Gimbernat's ligament; *d*, iliac portion of fascia lata; *e*, pubic portion of fascia lata; *f*, margin of saphenous opening (turned back); *k*, femoral sheath opened by three incisions; *l*, saphena vein.

posterior portion of this sheath is formed by the fascia iliaca, and it will be seen that it occupies the space between the psoas muscle and Gimbernat's ligament.

If the crural arch be pulled upwards a dense band of fibres will be seen connecting the upper layer of the sheath with the crural arch, and reaching from the psoas to Gimbernat's ligament and the conjoined tendon. This is the *deep crural arch*. The sheath is divided into three compartments, separated by distinct processes. The inner compartment is termed the *crural canal*. The interval between the femoral vein in its compartment and the curved edge of Gimbernat's ligament is the *crural ring*, the other boundaries of which are—*above*, the deep crural arch; *behind*, ilio-pectineal line, origin of pectineus, and attachment of pubic portion of fascia lata. On passing the finger into the crural ring the inferior portion of Gimbernat's ligament can be felt along the ilio-pectineal line, considerably behind the ring. The crural ring is blocked in above by a thin fascia derived from the subperitoneal, termed the *septum crurale*, which transmits ducts of glands. The crural canal is usually occupied by a lymphatic gland.

In the employment of *taxis*, for the reduction of a crural hernia, it must be remembered that the direction of the crural canal is *downwards*, and slightly *forwards* and *outwards*; moreover, that, in order to relax the orifices of this canal, the thigh must be flexed upon the pelvis, adducted and rotated inwards.

The course taken by a crural hernia is as follows:—First, passing into the femoral ring, it descends vertically in the femoral canal as far as the saphenic opening; next, being here prevented from passing further along the sheath of the vessels, it is directed forwards, and subsequently upwards, upon the external pillar of the opening and Poupart's ligament.

The coverings of a crural hernia are—sac, subserous areolar tissue, septum crurale, sheath of vessels, cribriform fascia, superficial fascia, and integuments.

The seat of stricture may either be the sac itself, or the junction of the falciform process, with Gimbernat's ligament, or the outer margin of the opening; and in

dividing the obstruction, the incision is to be made *upwards* and *inwards*.

An irregular course of the *obturator artery* bears a very important relation to the crural ring, should it arise by a common trunk with the deep epigastric, and when it would course along the border of Gimbernats ligament, in order to gain the thyroid foramen. In this case the neck of the hernia would be surrounded by an arterial ring, and in an operation for the relief of strangulation, might run great risk of being wounded. Practically, however, it

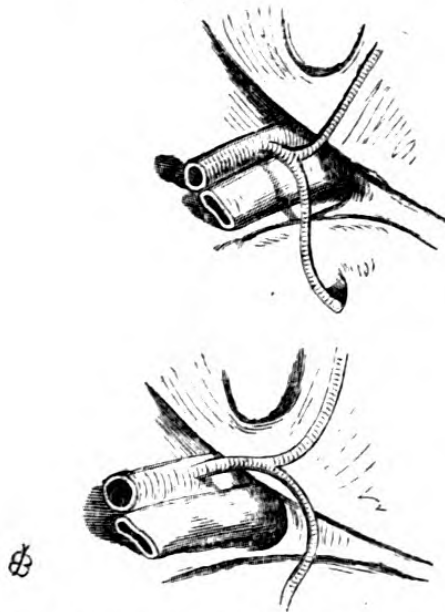


Fig. 49.—Irregular course of Obturator Artery.

would probably recede, unless the knife were roughly

pushed past the posterior aspect of the ring.

Besides herniæ, the fold of the groin is the seat of other *tumours*, of which an accurate knowledge of the anatomy of the region affords the chief help towards the diagnosis; such as aneurism, the pointing of a psoas abscess, an inflamed lymphatic gland, cysts, enlargement of the bursæ beneath the tendon of the psoas, which is often connected with the hip-joint.

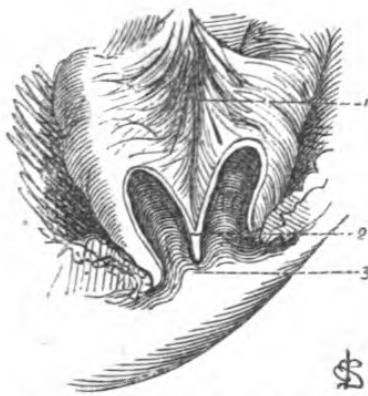

Fig. 50.—Sketch of Artificial Anus.

1, mesentery; 2, eperon; 3, opening of artificial anus.

Artificial Anus.—In cases of strangulated hernia, whether inguinal or crural, when the bowel has become gangrenous,

or if the intestine has been wounded, and given way in a state of gangrene, surgical principles indicate the

removal of this portion, and the subsequent formation of an artificial anus, and the following condition generally results, which explains the impediments in the way of its healing:—The edges of the gut become attached to the aperture in the abdominal wall, and that generally at an angle which soon becomes acute. As the upper portion of the intestine only transmits fæces, the lower remains as a useless tube, and consequently contracts in its calibre. That portion of the bowel to which the mesentery is attached, becomes drawn out into a spur-like process (*éperon*); which acting as a valve, serves to direct the fæces out of the body, and to divert them from their proper channel.

SURGICAL ANATOMY OF THE ILIAC FOSSA.

POSTERIOR WALL OF ABDOMEN.

The iliac fossa forms the inner aspect of the region just described, and is of great surgical interest. From before backwards the structures successively met with are—the peritoneum, with the viscera it encloses, the subperitoneal fat and cellular tissue, which contains a considerable amount of fat (allowing the peritoneum to be readily stripped off in ligature of the vessels), the common and external iliac arteries and their veins, lymphatics, the spermatic or ovarian vessels, the ureters, and the fascia iliaca. Beneath the fascia is a second cellulo-adipose layer, in which are the circumflex ilii artery and veins, the iliacus and psoas muscles, in the substance of which is the anterior crural nerve; upon the former muscle are seen the external cutaneous and the ilio-inguinal, and upon the latter the genito-crural nerves, and the nutrient vessels derived from the ilio-lumbar, finally the bone.

Fascia iliaca.—This structure is of the utmost importance surgically, as affecting collections of fluid in the region. It may be regarded as a continuation of the fascia transversalis, it is very dense and tough, and

by its attachment converts the iliac fossa into an osseofibrous compartment. It is attached anteriorly and externally to the crest of the ilium and Poupart's ligament, and behind this it is attached to the internal oblique and transversalis. Posteriorly and internally it is attached to the superior outlet of the pelvis, passing behind the vessels and forming a kind of cellular sheath. Superiorly it is attached to the inner lip of the iliac crest, to the ilio-lumbar ligament, and is continuous with the aponeurosis which covers the quadratus lumborum. Inferiorly, just above the crural arch, it divides into five laminae, the anterior becoming continuous with the transversalis fascia, and the posterior forming the aperture through which passes the iliopsoas muscle.

The peritoneum is very loosely united to the subjacent tissues. It completely invests the left iliac fossa, and the right incompletely, on account of the presence of the cœcum. The subperitoneal cellular tissue is very lax, and contains a considerable amount of fat, and continuous with that of the abdomen, and is the frequent seat of abscess of various kinds, effusions of blood, or urine. Pus developing in this tissue has for its limits the fascia transversalis in front, the fascia iliac behind, and Poupart's ligament below; pushing up the peritoneum it may, however, pass along the course of the vessels.

Vessels.—*The common iliac.*—The course taken by this vessel, with regard to the surface of the body, is from a point just to the left of the umbilicus to the centre of Poupart's ligament. After the intestines and peritoneum have been raised, it will be seen that the aorta bifurcates, or does generally, on the left side of the fourth lumbar vertebra; consequently the vessels of the right and left side differ somewhat in length, the right being slightly the longer, and lies rather more obliquely across the body of the fifth lumbar vertebra. Their length is about two inches, more or less, and passing downwards

and outwards, at the sacro-iliac synchondrosis divide into external and internal iliacs ; the vena cava inferior lying to the right side, and being formed by the union of the two common iliac veins, the right common iliac artery crosses their junction, rendering the relation of the vessels on the right side more intimate, the vein projecting external to the artery above, and being internal to it below, whilst on the left side the vein lies below and internal to its artery. Both are crossed at their bifurcation by the ureter.

The relations of the common iliac of the right side :—In *front* of it, the peritoneum, ilium, sympathetic plexus, and ureter ; *externally*, the cava, right common iliac vein, psoas magnus ; *behind*, junction of common iliac veins, obturator nerve. On the *left* side it has, in *front*, peritoneum, sympathetic, rectum, inferior mesenteric artery, ureter ; *externally*, psoas magnus ; *internally*, left common iliac vein ; *behind*, left common iliac vein, obturator nerve.

Ligature of common iliac artery.—In order to reach this vessel a curved incision is recommended, commencing from just above the middle of Poupart's ligament to a point two or three inches above and to the inner side of the anterior superior spine, or, commencing from a point close to the anterior superior spine, towards the edge of the rectus. The first incision divides the integuments ; next the external oblique, the internal oblique, and the transversalis are to be divided in succession and to an equal extent. Beneath this latter is the transversalis fascia, which is to be carefully pinched up, nicked, and a director insinuated between it and the peritoneum. It is then to be divided to the length of the incision in the muscles (the deep circumflex iliac artery will stand a chance of being cut). The peritoneal bag and its contents are to be then pulled away towards the middle line, when the vessel will be seen just above the sacro-iliac synchondrosis. The needle is to be passed *from within outwards*.

The collateral circulation would be maintained by the inosculation of the lateral sacral and middle sacral, epigastric and internal mammary, aortic inter-costals and lumbar, the ilio-lumbar and last lumbar, the obturator, with its fellow of the opposite side, and the epigastric, gluteal, and sacral, hæmorrhoidal of the internal iliac, with the superior hæmorrhoidal of the inferior mesenteric, and the vesical of the opposite sides, and the uterine and ovarian in the female.

The external iliac artery.—The course of this vessel would be indicated on the surface of the body by a line extending from either side of the umbilicus to the centre of Poupart's ligament. It commences at the bifurcation of the common iliac, and extends to the crural arch, where it becomes common femoral.

Its relations are—in *front*, intestines and peritoneum, a considerable quantity of loose areolar tissue, the spermatic vessels, the genito-crural nerve (near Poupart's ligament), the circumflexa ilii vein, and a chain of lymphatics; *externally*, the psoas muscle, and fascia iliaca; *internally*, the external iliac vein, vas deferens, and lymphatics; *behind*, the external iliac vein and psoas magnus muscle.

Ligature of external iliac.—An incision (curved for preference) is to be made, commencing at the middle of Poupart's ligament, and at about an inch above it, to a point just beyond the anterior superior spine of the ilium. The structures divided and the method of dividing them are those described in ligature of the common iliac, with this exception, that here they are more aponeurotic, from being nearer Poupart's ligament; and the deep epigastric artery is in this instance in danger of division, if the incision be made too near the rectus muscle.

When the peritoneum and intestines have been pulled away from the point where the ligature is to be applied, it often happens that neither artery nor vein is to be found; in this case they have followed these structures, and will be discovered lying adherent

to the under surface of the peritoneal bag, with the ureter, from which they must be cautiously separated. The needle is to be applied *from within outwards*.

Collateral circulation after ligature of external iliac.—The gluteal anastomoses with the external circumflex from the profunda femoris; the ilio-lumbar, with the circumflexa ilii; the obturator, with the internal circumflex from the profunda; the ischiatic, with the perforating and circumflex branches of the profunda; the internal pudic, with the superficial and deep external pudic, and the internal circumflex from the profunda; and the deep epigastric with the superior epigastric from the internal mammary.

Beneath the fascia iliaca is a second cellulo-fatty layer, which is associated with the tendon of the iliopsoas, as far as its insertion, and pus forming therein would pass beneath the crural arch external to the vessels, and point at the internal and superior portion of the thigh, at the level of the small trochanter.

SURGICAL ANATOMY OF THE LUMBAR REGION.

The lumbar region forms the posterior portion of the abdominal parietes, and is of surgical importance from the relation to its anterior aspect of the abdominal viscera, from the numerous fasciæ which enter into its formation, and the relation of these fasciæ to abscess, the operation of colotomy, nephrotomy, the opening of peri-nephritic abscess, etc.

The limits or boundaries of the region may be defined as follows:—*above*, the lower border of the last rib; *below*, the crest of the ilium; *externally*, a line drawn through the end of the last rib perpendicularly to the iliac crest; and *internally*, the line of the spinous processes of the vertebræ.

Topography.—The integument is tough and thick; the subcutaneous cellular tissue contains a great deal of fat, excepting along the middle line. We next see, in order, from without inwards, the following structures:

the aponeurotic origin of the latissimus dorsi and serratus posticus inferior, part of the external oblique, and common aponeurotic attachment of the internal oblique and transversalis, the mass of the erector spinæ muscles, a considerable number of vessels and nerves lying between these muscles, the attachment to the transverse processes of the lumbar vertebræ of the middle lamina of the aponeurosis of the transversalis muscle, the quadratus lumborum muscle and ilio-lumbar ligament, branches of the lower part of the dorsal and upper part of lumbar plexuses, psoas muscles, transversalis fascia, a large quantity of fat and cellular tissue separating the kidney from the parietes, the kidney itself, with the ureter and spermatic or ovarian vessels, and in the front of the psoas, the colon, the ascending on the right, and the descending on the left. The ascending colon is generally enclosed in peritoneum, which forms, by its attachment to the spine, a mesocolon, whilst the descending is covered only anteriorly and laterally, and is for that reason selected for the operation of opening the colon in the left loin (Amussat).

“The descending colon has fixed positions, and being incompletely invested by peritoneum, an incision can be made into it without wounding this membrane. It is usually stated that the descending colon lies along the outer border of the quadratus lumborum, and in conformity with this, an incision is to be made vertically along the outer border of this muscle. This is not always correct. At the lower border of the kidney, the colon lies further away from the middle line than it does in the iliac region; and the quadratus lumborum being narrower above than below, this rule is true as far as regards the position of the gut at the level of the third lumbar vertebra, but not so beyond this point. At the level of the symphysis between the third and fourth lumbar vertebræ, and at that of the fourth below the kidney—and therefore exactly in the field of operation—the quad-

ratus lumborum covers in the colon posteriorly, and must be cut in order to reach it. It is only when disturbed, a condition which is not so constant as one would expect in operations, that the intestine increases in breadth forwards and outwards, or overlaps the outer border of this muscle (Pirogoff). Consequently the incision which is to be directed along the border of the great extensors of the trunk from the ilium to the twelfth rib, would divide the strong tendon of the transversalis until the quadratus is exposed, and subsequently the fibres of this muscle, when the extra-peritoneal fat and cellular tissue would be met with. When the surgeon has carefully arrived at the cellulo-fatty tissue through the fascia beneath the quadratus lumborum, making the incision of an equal length with the primary one, so as to avoid a funnel-shaped wound, the main point is to fix the colon at its free surface, and open it. In doing so he must avoid the kidney, which from its deep position can easily obstruct the field of operation, and which must be carefully pushed on one side. From the impossibility of recognizing the peritoneum from its posterior aspect, success can only be calculated on by measuring the distance of the point of reflection of the peritoneum, and how far from the colon this position is constant. In the first place, as regards the descending colon which is here particularly referred to, after measurements on frozen bodies of full-grown men, it would seem that this distance, in a straight line (therefore not corresponding with the curvature of the wall of the intestine) is from four-fifths of an inch to one inch, supposing the intestine empty and contracted (at a level between the third and fourth lumbar vertebræ;) further, that the free side of the intestine, as in the accompanying cut, does not look posteriorly but somewhat inwards, exactly towards the angle which the psoas and quadratus lumborum make with each other. If on the other hand, the small intestines are much distended, the peritoneum

between the psoas and the colon would be pushed further downwards, and the colon, by means of the traction of the parietal portion of the peritoneum, would be rotated in its axis, so that its free surface would be dissected more outwardly. Should the

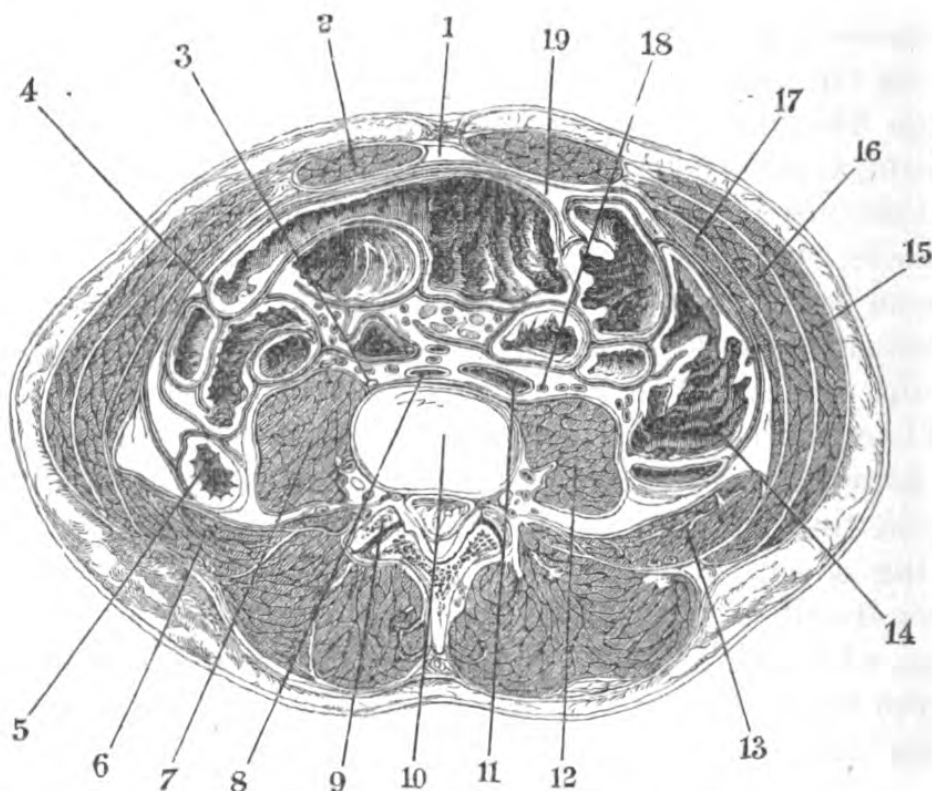


Fig. 51.—Section of Abdomen between the third and fourth lumbar vertebræ.

1, umbilicus; 2, rectus; 3, sympathetic (note); 4, great membrane; 5, descending colon; 6, quadratus lumborum; 7, psoas; 8, aorta; 9, articular process of third lumbar vertebra; 10, inter-articular cartilage; 11, vena cava; 12, psoas; 13, quadratus; 14, ascending colon; 15, external oblique; 16, internal oblique; 17, transversalis; 18, ureter; 19, great omentum.

colon itself be distended, its surface free of peritoneum becomes considerably larger, and may assume a breadth of from 2 to 2½ inches. Tympanitis of the smaller intestine appears to have a rotatory influence on the distended colon.”*

* I have transcribed this passage from my own translation of Braune's "Topographical Anatomy," on account of its great practical value.—E. B.

Lumbar colotomy.—The colon may be reached either by a transverse incision (Amussat), by a longitudinal one (Hilton, Callisen), or, better still, by an oblique one.

Structures divided in Amussat's operation by transverse incision.—The incision is made from a point taken midway between the crest of the ilium and the last rib at the outer edge of the erector spinæ, varying in length according to the development of the individual, and is directed outwards, at first dividing the integuments, the aponeurotic origin of the latissimus dorsi, and some few fibres of the external oblique; next the origin of the internal oblique and transversalis, and a portion of the quadratus lumborum and its fascial investment. After the transversalis fascia has been divided, a quantity of loose cellular tissue and fat is seen, which, being scratched through, exposes the colon. During life, however, the distension is generally so great that the bowel *bulges* into the wound.

In the vertical incision, which is made about four inches or so external to the spinous processes of the vertebræ, the structures divided would be, the integument, the aponeurotic origin of the latissimus dorsi, the origin of the internal oblique, tendon, transversalis and transversalis fascia.

That portion of the spinal column which is enclosed between these regions, has upon its anterior surface the crura of the diaphragm, covered by peritoneum and subperitoneal fat and fascia, the vena cava ascendens, abdominal aorta, and on either side the chain of the sympathetic, the thoracic duct, the receptaculum chyli, vena azygos major, and a large number of lymphatic glands.

Lumbar fascia.—The peculiar arrangement of the fasciæ in the lumbar region is of great importance surgically, from the control it has over the course taken by the pus in lumbar abscess. This fascia is the posterior aponeurotic portion of the transversalis,

and posteriorly gives attachment to the internal and external oblique and latissimus dorsi muscles. From its inner edge, two laminae, derived from it, are attached to the transverse processes of the lumbar vertebræ, and enclose the quadratus lumborum, the posterior lamina separating it from the erector spinæ, whilst the posterior portion of the erector spinæ is covered in by the aponeurosis of the latissimus dorsi.

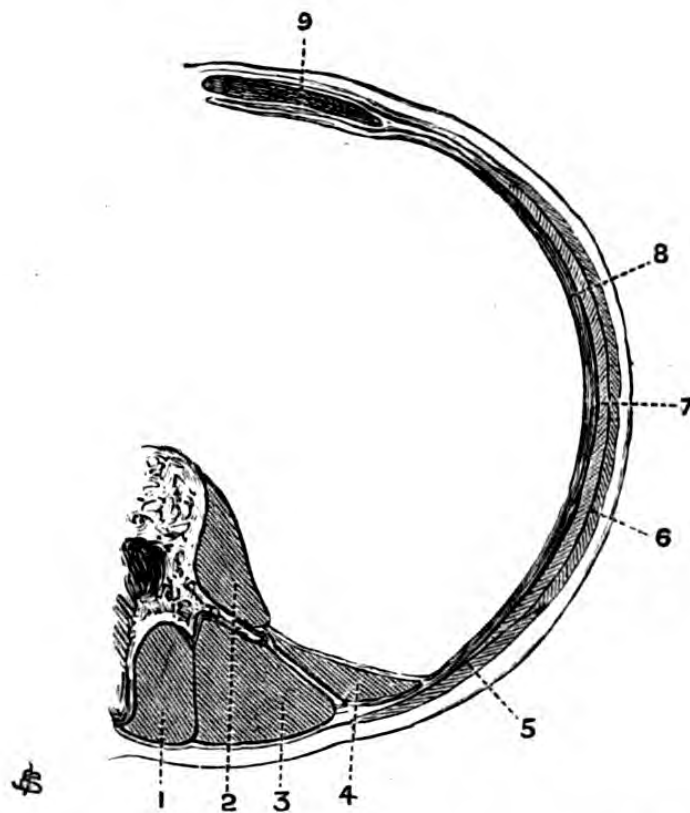


Fig. 52.—Arrangement of Lumbar Aponeurosis at level of third lumbar vertebra.

1, sacro-lumbalis; 2, psoas magnus; 3, longissimus dorsi; 4, quadratus lumborum; 5, latissimus dorsi; 6, external oblique; 7, internal oblique; 8, transversalis; 9, rectus.

In the condition known as “lumbar abscess,” the passage of pus is governed by the lumbar aponeurosis, and by such laminae of fasciæ as spring originally from it, and may extend anteriorly in the cellular interspaces between the abdominal muscles, or posteriorly

between those of the lumbar muscles and their derivatives.

In all cases such abscesses point *above* the level of Poupart's ligament anteriorly, *above* the iliac crest laterally, and *above* the lumbo-sacral sulcus posteriorly, although of course they may perforate the parietal peritoneum. This, however, is rare.

Collections of pus may originally form in the anterior compartment of the lumbar aponeurosis, and gravitate forwards and downwards, directed by the fascia transversalis to the edge of the rectus, on the level of the fold of Douglas. This lamina of fascia transversalis would separate the collection of pus from the space known as the *cavum præperitoneale*, the so-called fossa of Retzius.

The pus cannot pass to the opposite side, owing to the central concurrence of all these fasciæ, and its passage forwards is easily explained if we regard the transversalis fasciæ and the intermuscular cellular laminae as derivatives of the lumbar fascia anteriorly. Here the diagnosis of the locality of pus, whether in front of or behind the fascia transversalis, depends on the behaviour of the "respiration line," and the fact of it being confined to one side.

Abscesses developed in the posterior compartment of the lumbar aponeurosis may point anteriorly at first towards the peritoneal cavity, and subsequently make their way to the surface posteriorly, or when developed within the sheath of the quadratus point at its posterior and external border where the abdominal parietes are very weak (triangle of Petit).

Abscess simulating "lumbar" may be associated with a carious condition of the rib, the pus being limited posteriorly by the sheath of the sacro-lumbalis, and gravitating downwards in the posterior compartment of the lumbar fascia.

Although the psoas muscles essentially belong to the lumbar region, yet psoas abscesses do not necessarily *arise* in them, the course taken by the pus being

in a great measure governed by the fascial investment they obtain there; this investment is that of the fascia iliaca, which, as regards the muscles, is attached above to the ligamenta arcuata interna, internally to the sacrum, being continued over the muscles to the crural arches, beneath which the pus gravitates, and ultimately points *external* to the femoral vessels. Sometimes it passes through the sacro-sciatic notch to the nates.

The relation of the nerves to the spinal column, emerging as they do either through the intervertebral spaces or sacral foramina, readily accounts for the course taken by the pus in these abscesses.

Iliac abscess is a collection of matter either in the cellular tissue, between the iliac fascia and peritoneum, or between the fascia iliaca and iliacus muscle, and points above Poupart's ligament, near the anterior superior spinous process of the ilium.

The collections of pus met with beneath the peritoneum (peri- and retro-peritoneal) are usually dependent on inflammatory conditions of those viscera which are enveloped in that "atmosphere" of cellular tissue, the various spaces of which may be examined, at all events, theoretically, in the following manner, as originally suggested by Koenig. We may obtain a tolerably good idea of the behaviour of pus with regard to the fasciæ and pelvic peritoneum by *injecting* these cellular interspaces.

First, to demonstrate the probable course of the pus in a subserous (or *supra*-fascial) abscess of the iliac fossa. If an injection-tube be introduced at the edge of the true pelvis at the highest portion of the broad ligament, between the two layers, the peritoneum is immediately lifted off the iliacus and psoas, and then detaches itself from the anterior wall of the abdomen. Some of the fluid may pass into the inguinal canal, or along the sheath of the vessels. In the male, merely introducing the tube beneath the peritoneum will suffice, and the fluid often makes its way along the

course of the cord, as does pus in some forms of abscess. Again, with regard to *subfascial* abscesses, if the inner aspect of the psoas muscle be injected beneath Poupart's ligament, the fluid passes immediately into the region of the vessels and psoas itself; and on applying a little more pressure it passes into the sheath of this muscle, or between the bundles of muscular fibre, as high as the lumbar vertebræ, while a still greater amount causes it to extend as far as the quadratus, whilst it simultaneously fills the iliacus muscle and its fossa. If the injection be introduced on the outer aspect of the iliaco-psoas tendon, it fills up the entire space enclosed by the fascia iliaca and the ilium; a little more pressure will drive it into the psoas.

Next it rises up to the quadratus, and ultimately reaches the zone of cellular tissue surrounding the kidney. When the iliac fossa is full, the contents of the osseo-aponeurotic cavity drag up the peritoneum from Poupart's ligament, and may be felt bulging near the anterior superior spinous process.*

The "pointing" of these abscesses, however, is liable to variation. It may be detected (1) at the outer edge of the quadratus; (2) it may become associated with the psoas tendon, or pass through the ischiatic foramen; (3) it may involve the hip-joint through the bursa iliaca; (4) it most frequently passes beneath Poupart's ligament at the outer aspect of the iliaco-psoas tendon, reaching the surface by the cellular interspace between the rectus femoris and the tensor fasciæ, or it may follow the inner edge of the rectus, and point in the region of the sheath of the sartorius.

Owing to openings in the fascia, such as for the passage of nerves or blood-vessels, or irregularities in its application, the subserous abscess may become subfascial, or the converse, or they may be co-existent.

Sacro-iliac disease.—With regard to the passage of pus in this disease, it may either make its way to the surface at the superior portion of the articulation or on

* Koenig, "Lehrb. der Spec. Chirurg.," Bd. ii.

the outer aspect of the thigh, or a little behind the great trochanter, taking the course of the great sciatic nerve—the course depending on the relation the sacro-iliac joint bears to the lumbo-sacral cord, and the strong lamina of pelvic fascia which covers in the pyriformis muscle. Sacro-iliac abscesses may point on the inner side of the thigh at the edge of the obturator externus, following the course of the obturator vessels and nerve.

Unlike lumbar abscesses, which may be palpated in some cases both anteriorly and posteriorly, or the fluid made to pass from one fascial envelope to a communicating one, if two collections of matter exist, one cannot be emptied into the other, on account of the peculiar serrated shape of the articulation.*

SURGICAL ANATOMY OF THE PELVIS.

Those portions of the true pelvis and its contents which come within the province of the surgeon are, more particularly, the genito-urinary apparatus of both sexes, the rectum, and its inferior boundary, comprising the perineal and anal regions. Those details of its anatomy which more particularly concern gynæcology will be studied with greater advantage in special works upon the subject, and will be but briefly alluded to here.

Its walls present surgically two surfaces for examination, on either of which operative proceedings may be instituted—(1) An *external*, partly free, consisting inferiorly of the perineum, laterally of a region belonging partially to the lower limb, and posteriorly, of the sacral and coccygeal regions; and (2) an *internal*, consisting of the peritoneal surface of the perineum, and the soft parts lining its bony structure, which include the pelvic viscera and the great vessels.

The external genitals may be regarded as appendages to the pelvis, and will be conveniently treated of

* *Vide* Clin. Lect. by Author, *Med. Times and Gaz.*, July 12, 1879.

before entering upon its immediate anatomy, and such parts of its lateral boundaries as are evidently common to it and to the lower limb will be included in the description of the latter.

PELVI-PERINEAL REGION.

SCROTUM.

Structure.—The various tissues entering into the structure of the scrotum are met with in the following order:—The *skin*, very thin, lax, and rugose; the *superficial fascia*, with which it is closely associated, continuous with that covering the abdomen and perineum, and in this region entirely destitute of fat. The *dartos*, consisting of loose areolar tissue, in which is a considerable amount of unstriped muscular fibre, very vascular, is continuous with the superficial fascia of the crural region and perineum, and sends a septum inwards which divides the scrotal bag into two halves, thus separating the testes. The dartos is connected with the subjacent parts by delicate areolar tissue, allowing of the free movement of the scrotal structures over the testes, and owing to the corrugating power it has over the scrotal tissues, it is difficult to approximate the edges of incisions when made in its structure. A *fibro-cellular* coat has been described, which is the continuation of the external spermatic fascia, but it is very thin, and not easily followed beyond the cord. Beneath this layer is the *cremasteric fascia*, derived from the lower border of the internal oblique and gubernaculum during the descent of the testis, and the *fascia propria* or *infundibuliform*, a derivative of the fascia transversalis. All these structures are inter-united by a very lax cellular tissue, which not only allows of their free movement over each other, but over the cord and testes.

The scrotal tissues are not very sensitive, and have not much vitality; consequently, in erysipelatous inflammation or urinary extravasation they rapidly

become gangrenous. When the urethra gives way from unrelieved retention, or from ulceration of its walls, the urine is driven by the sudden contraction of the bladder into the cellular interval between the scrotal and abdominal fasciæ, and its direction is limited by the attachments of the fascia already named. Commencing at first in the scrotum, it ascends over the pubes and abdomen and cellular tissue of penis, but cannot descend down the thighs, owing to the attachment of the deep layer of superficial fascia along Poupart's ligament. In the case of wound of the urethra from without, such, for instance, as a blow in the perineum, not only is the urethral tube itself ruptured, but the fasciæ enveloping it, often to an unlimited extent; hence the urine may follow almost any course, and not restrict itself to anatomical relations.

The *spermatic cord* consists of the external spermatic fascia, cremaster, infundibuliform fascia, vessels, lymphatics, nerves, and the vas deferens, which can be

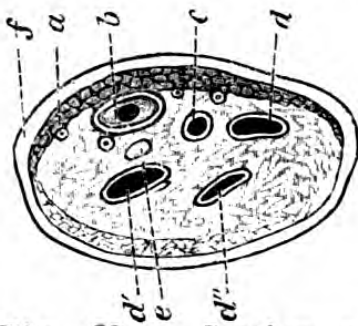


Fig. 53. — Section of Spermatic Cord.

a, cremaster; *b*, vas deferens; *c*, spermatic artery; *d*, spermatic veins; *e*, ilio-inguinal nerve; *f*, external spermatic fascia.

readily isolated from the other structures, being recognized by its whipcord-like texture. The *arteries* of the cord are the spermatic, deferential, and the cremasteric; of these the spermatic supplies the substance of the testis, passing into it

either through the tunica albuginea, or through the back of the mediastinum testis. The *veins*, passing from the testis, unite in forming the *pampiniform* plexus, which passes into a single trunk forming in the body of

the cord, and terminating, the right one in the vena cava, and the left in the left renal vein. The veins of the cord are very liable to a varicose condition (*varicocele*), which is due to several anatomical causes:—their tortuous arrangement and free

anastomoses at their emergence from the gland; their want of support, lying as they do in the loose areolar tissue, which allows of the weight of the contained column of blood obliterating their valves; the pressure they receive in their passage through the inguinal canal. It is a matter of fact that the left spermatic veins are almost exclusively liable to this condition, the causes assigned being, that the left testicle hangs lower, and that its upward current of blood meets at a right angle that proceeding from the kidney in the left renal vein, and that they are liable to constant pressure from the contents of the sigmoid flexure of the colon.

The *lymphatics* are numerous and large, and terminate in the lumbar glands, which become rapidly affected in malignant disease of the testis.

The immediate covering of the testis is the tunica vaginalis—a structure of great surgical importance. When the testis passes into the scrotum, towards the end of intra-uterine life, it carries with it a portion of the peritoneum, which envelopes it without completely enclosing it with its cavity. It presents a parietal and a visceral layer. The former being applied to the internal aspect of the scrotal tissues (the fibrous tissue), and the latter covering the testis and epididymis. The parietal layer is reflected over the last, forming a cul-de-sac, which bulges up higher externally than internally.

The visceral layer keeps the two extremities of the epididymis in contact with the gland and at about its centre, forming a sort of mesenteric fold, or *meso-testis*.

The tunica vaginalis presents three distinct prolongations, or pouches, which may be termed the funicular, epididymitic, and testicular, but in the normal condition they are not distended with fluid.

Between the parietal and visceral layers there is in intra-uterine life a canal, so that the tunica vaginalis

communicates with the peritoneal cavity, and it is not until after the completion of the descent of the testicle that this canal becomes obliterated; and the cicatrix of this obliteration is situated just behind the inguinal canal, giving rise to the external inguinal fossette.

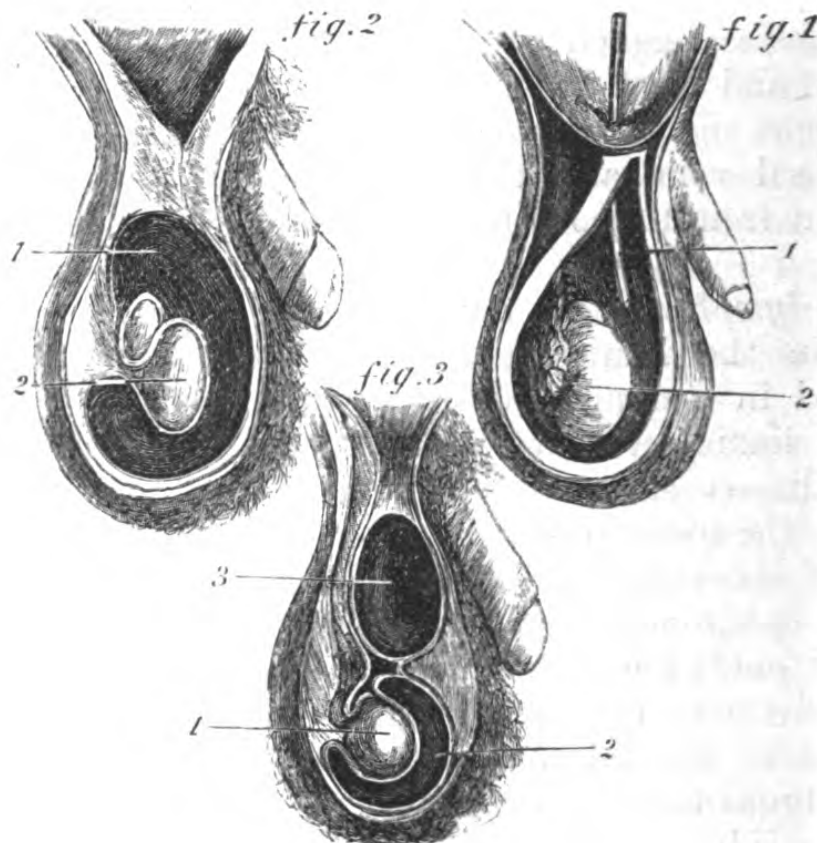


Fig. 54.

Fig. 1, Congenital Hydrocele:—(1), a probe passed through the patent processus vaginalis; (2), testis.

Fig. 2, Hydrocele:—(1), testis; (2), tunica vaginalis.

Fig. 3, Hydrocele of Cord:—(1), testis; (2), tunica vaginalis; (3), processus vaginalis.

Hydrocele.—This consists of a collection of fluid in the scrotum or cord, and is subject to a good many varieties. We may here mention the three following as the most common:—

Congenital hydrocele (Fig. 1), in which the fluid is in the patent canal (processus vaginalis), and is most common in children.

Should the opening of communication with the peritoneal cavity be large, the fluid sometimes passes back into this cavity, and a knuckle of small intestine may pass into the scrotum. (*Vide* "Congenital Hernia.")

Hydrocele of the tunica vaginalis (Fig. 2). This is the most common form met with in adults. In this condition the testicle is generally situated posteriorly and internally, for the reason that the tunica vaginalis is of greater capacity anteriorly and externally.

Hydrocele of the cord (Fig. 3). This signifies a collection of fluid in this portion of the processus vaginalis lying with the cord. There are several varieties of this form.

In the event of the hydrocele being of long standing, the epididymis becomes separated from the body of the testis.

The transparency of the hydrocele is not constant, as the tunica vaginalis becomes sometimes so thickened, or its contents are so altered, that they are quite opaque.

In *hæmatocele*, the anatomical relations of the testis and its covering are precisely similar.

In puncturing the tunica vaginalis and "tapping," the trocar should be pushed in at first vertically, with drawn, and the canula then directed upwards.

TESTIS.

As the structure of the testis will be found in all works on descriptive anatomy, it is proposed to make some few remarks, which may have a practical bearing. The testis is ovoid in shape and flattened transversely, and it hangs suspended by the cord, so that the major axis is oblique from above downwards, and from before backwards. The consistence is firm and equal in health, and any indurations or knots are indications of

a morbid condition. The peculiar pain produced by pressure is often of diagnostic value in determining the position of the organ.

The testis has a special fibrous covering, the tunica albuginea, very resistant, and forming the integral portion of the organ, its inner surface gives off trabeculae, which subdivide the testicular substance into distinct lobules. The greater number of degenerations of the testis commence within these interlobular trabeculae.

The fibrous envelope yields to gradual, but resists rapid distension, and this is a valuable fact in determining the nature of testicular tumours, as in the instance of sarcoma or encephaloma the distension is gradual, and, at last breaking through at one or more points, the growth protrudes, giving rise to the induration or knots referred to.

It is often difficult in disease to distinguish the testis from the epididymis, a point of importance in diagnosis. To do so, the scrotum should be held firmly grasped by the one hand, and the lateral surfaces of the enclosed testis gently traversed by the index finger of the other backwards and forwards, when the furrow which separates the testis from the epididymis may be made out, and the surgeon may detect whether it corresponds with the posterior or anterior border, or to either of the surfaces of the gland, according as the testis is normal or inverted.

In removal of the testis (*castration*), the retraction of the cord into the abdominal cavity, owing to the action of the cremaster muscle, is liable to give trouble through hæmorrhage, unless it be firmly secured.

The *structures divided in the operation of castration* would be as follows:—The scrotal tissues, with the vascular and nervous supply — viz., the superficial perineal vessels and nerves, inferior pudendal nerve, superficial external pudic vessels; the structures entering into the formation of the cord.

THE MALE PERINEUM.*

This region is best studied when the body is placed in what is known as the lithotomy position—that is, with the legs flexed on the thighs, and the thighs on the pelvis, in order that the parts to be examined be on the stretch.

In the erect position of the body the superficial aspect of the region becomes a mere fold, but it must be borne in mind that the same relations exist.

There is considerable difference in the descriptions given by authors as to what the limits of the perineum really are: some including all those structures which close in the inferior outlet of the pelvis, its entire floor in fact; others dividing this lozenge-shaped space into two triangles, by a line passing from one tuberosity of the ischium to the other, in front of the anus, and calling all in front of it the perineum, and all behind it, the anal, or ischio-rectal region. It is proposed to adopt the latter method in this description, and it will be seen that, although it may appear arbitrary as far as the superficial layer of fascia is concerned, as the examination proceeds deeper towards the inner aspect of the pelvis, the arrangement is a natural one, as adapting itself to the special contents of each triangular space. The boundaries of the anterior portion, which is convex in the middle, owing to the position of the bulb of the urethra, are—below, a line passing horizontally in front of the anus from one tuberosity of the ischium to the other; and laterally, the pubic rami, meeting at the symphysis; thus forming a triangular interspace, which is itself divided by the median raphe

* It has been considered advisable, instead of devoting a special chapter to the surgical anatomy of the female genito-urinary apparatus, to incorporate any facts of surgical importance relating to it in the description of those of the male, and the student is referred to special works on obstetrics for detailed descriptions of these organs, *e.g.*, uterus, ovary, etc.

into two equal parts, in either of which the lateral operation of lithotomy may be performed. This raphé indicates the course taken by the urethra, and is a most valuable landmark in all operations about the perineum. The sides of this triangular space are about three inches and a half long, its base about three inches, and a line drawn from the apex of the triangle to its base, about three inches.

Topography.—Anterior perineal region.—The integument is here moderately thick, becoming thinner as the fold of the scrotum is approached, and is very distensible and resilient. Beneath is the subcutaneous cellular tissue, which is very adherent to the integument along the middle line. The superficial fascia may be conveniently divided into two layers: the upper containing a good deal of fat (which considerably augments the depth of the perineum in some cases) is continuous with that of the scrotum and thighs, and in it, or immediately beneath it, lie the superficial perineal vessels and nerves, whilst the deeper layer has important attachments and is more membranous in texture. Externally, it is attached to the rami of the pubes and ischium, outside the crura and erectores penis; behind, it is continuous with the deep perineal fascia, or triangular ligament of the perineum, after turning round the transversus perinei; and in front it is continuous with the dartos and fasciæ at the root of the penis; a septum derived from it passes inwards, dividing the posterior part of the space beneath this layer of fascia into two, but is, however, ill defined in front. This cellulo-fatty layer is a favourite seat of abscess from urinary or other infiltrations.

The attachments of this fascia are very important as directing the course of the urine in extravasation, from rupture of the urethra anterior to the triangular ligament, into the cellular tissue of the scrotum and penis.

Along the mesial line this fascia is intimately attached to the bulb of the urethra, and in cases where

the bulb has been injured, the urine, after extravasation, readily finds its way along the spongy portion of the urethra to the glans, with which it is continuous. Beneath this layer of fascia, in the middle of the space, are the *acceleratores urinæ* muscles, enveloping the bulb, and on either side are the *erectores penis*, passing from the inner aspect of the ascending ramus, and covering the lower portions of the crura. Lying somewhat obliquely to the central tendon are the transverse muscles of the perineum. This central tendon is a white fibrous knot, and acts as a *point d'appui* for the accelerator urinæ and external sphincter muscles; it is situated in the median line between the urethra and the anus. Lying between, and upon the *erectores penis* and the accelerator urinæ, are the trunks of the superficial perineal vessels and nerve, and some inosculating branches of the inferior pudendal, and on or below the posterior border of the *transversus perinei* muscle, lie the transverse perineal vessels and nerve. The accelerator urinæ is separated from the deep layer of superficial fascia by a thin aponeurotic layer. This muscle, which compresses the bulb, and empties the bulbous urethra, is generally described as consisting of three portions, commencing from the median raphe—an anterior, which passes round the penis to be inserted on its upper aspect, sending an expansion which compresses the dorsal vein; a middle, which encloses the inferior portion of the urethra, and passes between it and the body of the penis; and a posterior, which is attached to the anterior surface of the triangular ligament.

It will be observed that the perineal muscles of one side form a triangular space, having the triangular ligament as its floor, while from its outer angle emerge the superficial perineal vessels, and the transverse perineal vessels and nerves coming to the surface; the relations of the space are of importance, as in the lateral operation of lithotomy the first incision traverses it.

Below the accelerator urinæ muscle is the bulb of the urethra, small in childhood, and large in advanced age, and closely bordering on the margin of the anus ; this fact is of importance, as there is a greater danger of wounding the bulb in the lateral operation of lithotomy in old persons. Next is met with the anterior surface of the *triangular ligament*, a tough bluish-white structure—the fibres of which are nearly all transverse—allowing of the structures between the two layers being readily seen through it in favourable subjects ; its base is directed towards the rectum, it is attached in the middle line to the central tendon of the perineum, and laterally to the rami of the ischium and pubes, having a free margin on either side of the central tendon, which is continuous with the deep layer of superficial fascia ; its apex is directed upwards, and is connected with the periosteum in front of the symphysis pubis. It is perforated at about an inch below the symphysis by the urethra, with which it is intimately connected, and which here changes its direction, and between the urethra and the symphysis lie the vessels and nerves of the penis, the dorsal vein or veins in the centre, on either side the dorsal arteries, and most externally the dorsal nerves. Beneath the triangular ligament is a considerable plexus of veins.

Structures between the layers of the triangular ligament.—These consist of the following :—a plane of muscular fibres, variously described by different authors, as the levator and compressor urethræ, surrounding the membranous portion of the urethra, which lies between these layers of fascia, and receives a prolongation from each ; the deep transversus perinei ; the internal pudic artery and nerve, the former giving off the artery to the bulb and to Cowper's gland ; the artery to the corpus cavernosum, and the dorsal artery of the penis ; and just below the urethra, Cowper's glands, their ducts, and the sub-pubic ligament. Beneath this layer of muscular fibres and vessels is the posterior layer

of the triangular ligament, derived from the pelvic fascia.

The posterior layer of the triangular ligament is derived from the pelvic fascia, and covers the hinder part of the membranous urethra, and outer surface of the prostate gland ; it is attached below to the anterior layer, forming a pouch on either side of and below the urethra, in which lie Cowper's glands.

Beneath it are the anterior fibres of the levator ani, passing by the sides of the prostate, and uniting on its perineal surface with the muscle of the opposite side, and blending at the central tendon with the fibres of the external sphincter and transverse perineal muscles. The central fibres are inserted into the side of the rectum, interlacing with the sphincters, and the posterior are attached to the coccyx and median raphé behind the rectum. These muscles and the triangular ligament shut in the inferior outlet of the pelvis.

The anal or ischio-rectal region.—The integument is here thick, particularly where it is continuous with that of the gluteal region, whilst at the margin of the anus it becomes very thin, and is continuous with the mucous membrane. The muco-cutaneous layer is thrown into a series of folds by the external sphincter with which it is incorporated, and the skin of the whole of the perineum posteriorly is interwoven with muscular fibres.

In the middle line of this space lies the anus, the mucous membrane of which does not protrude, in the normal state, during life. If, however, the anus be gently opened at the junction of the mucous membrane with the skin, a pale line is to be seen, marking the position of the internal sphincter, a thickening of the muscular fibres of the lower portion of the rectum. This band of muscular fibres plays an important part in preventing the healing of ulcers and fissures of the rectum, by keeping the tissues on the stretch. These ulcers are generally situated about a quarter of an inch or so from the verge, just within the sphincter, and

generally either in front of, or at the side of the coccyx. The treatment consists in dividing the fibres with a view to relieve the tension. In operating on the female, care must be taken in making the incision, if on the anterior wall of the bowel, on account of the proximity of the vagina. If the verge of the anus be carefully examined it will be seen to contain a large number of follicles, in which suppuration often occurs leading to a condition which might be mistaken for fistula—a disease which is frequently difficult to diagnose correctly without a good view of the interior of the gut, of which an inch or an inch and a half must be exposed for the purpose; and it is a fact of great surgical importance that the internal opening of a fistula is always within this distance of the orifice.

The external opening of the rectum is occasionally wanting (atresia ani).

The *perineal portion of the rectum* is not much more than an inch in length, it curves back below the prostate, and is uncovered by peritoneum. Just above the anus the rectum is considerably dilated, a condition increased by age and constipation. The folds of mucous membrane, in the empty state of the rectum, so overlap, that considerable difficulty may be experienced in passing the finger or a bougie through them; one fold in particular often obstructs the finger, at about an inch and a half above the aperture. The mucous membrane of the lower end of the bowel is very loose, and readily admits of the burrowing of matter. It must be borne in mind that the curve of the bowel above mentioned necessitates caution in the introduction of an enema tube or other instrument, which should be directed obliquely *from below upwards and forwards*, and afterwards, *upwards and backwards*. (*Vide* "Cavity of Pelvis.")

A dilated condition of the inferior hæmorrhoidal veins at the lower part of the anus constitutes *external piles*.

The superficial fascia, tough and strong, and containing a great deal of fat, has cutaneous vessels and nerves passing through it. The external sphincter muscle is attached posteriorly to the tip of the coccyx, and enclosing the margin of the anus, is inserted into the central tendon before mentioned. This circular band of fibres is about one inch in breadth. Between the bowel and the tuberosities of the ischium is the *ischio-rectal fossa*, which contains a quantity of loose fat and cellular tissue, and lying across it, and passing to the margin of the anus, are the superficial hæmorrhoidal vessels and nerves, which are liable to give a good deal of trouble from hæmorrhage, when cut in operations for fistula, etc. In shape this fossa is somewhat triangular, about an inch in width, and about two inches deep; inferiorly its base is formed by the integuments of the region, and its apex, directed upwards, corresponds to the interval between the lower border of the obturator internus, covered by the obturator fascia, and the outer surface of the levator ani, covered by the anal fascia. Its boundaries are—externally, the tuberosity of the ischium and obturator fascia; internally, the sphincter ani, levator ani, covered by anal fascia, and coccygeus; anteriorly, the triangular ligament; and posteriorly, the gluteus maximus and great sacro-sciatic ligament.

Lying in a fold derived from the obturator fascia, on the outer wall of the fossa, the trunks of the internal pudic vessels and nerve can be easily felt, grooving the inner aspect of the tuberosity of the ischium.

In the external incision for lateral lithotomy the knife sinks into the ischio-rectal fossa, and will divide the superficial hæmorrhoidal vessels and nerves. Abscesses have a great partiality for the ischio-rectal fossæ, and often burrow to a most remarkable extent.

Fistula in ano is the sinus left on the contraction of the cavity of such an abscess. True fistulæ exist external to the sphincter, and always extend as far

up as its upper border. They are called complete or incomplete, according as their openings are situated ; thus, in the former case, one opening is in the rectum and the other on the surface of the body, generally near the anus ; in the latter, there is an opening into the bowel and none external, or the converse.

The operation for its cure consists in passing a knife through the fistulous track into the bowel, and cutting through all the tissues between the edge of the knife and the interior of the gut. These tissues are—the pseudo-mucous membrane of the fistula, the external sphincter, some few fibres of the levator ani, the branches of the inferior hæmorrhoidal vessels and nerves, the internal sphincter, and the mucous membrane of the inner bowel and its vessels.

The *relations of the bladder and the rectum*, within the reach of the finger, are of great importance ; thus, in cases of retention of the urine, when it is necessary to perform the operation of *puncture per rectum*, the distended bladder is felt overlapping the posterior margin of the prostate at a point where, if the puncture be made in the mesial line, no injury to surrounding parts could take place, as the instrument would pass between the vesiculæ seminales, and perforate a space (*trigone vesicæ*) where these structures are neither covered by pelvic fascia nor by peritoneum. The digital examination of the bladder *per rectum* assists the surgeon in the detection or dislodgment of vesical calculi, in guiding the point of a catheter or sound in cases of difficulty, and in the detection of prostatic abscesses, or growths.

Parts concerned in lateral lithotomy in the adult.—The object to be attained is that of opening the bladder at one particular spot, its neck, and for the reason that if opened at any other, urinary infiltration into the areolar tissue of the pelvis will take place. The incisions then must be made in the most direct way, to allow of (1), the position of the staff, which has been introduced into the bladder, being felt ; (2), the neck

of the bladder being opened, and room obtained for the extraction of the stone.

The perineum having been shaved, the skin and integuments are to be steadied and rendered tense with the fingers of the left hand, and the point of the knife is to be entered about an inch and three-quarters in front of the anus, a little to the left of the middle line, and carried through the skin, in a direction downwards and outwards, midway between the anus and the tuberosity of the ischium. The left forefinger is next to be pushed into this external wound, with the double purpose of feeling for the position of the groove of the staff in the urethra, and for the purpose of pushing the rectum downwards out of the way. When the groove is recognized, the knife, lying flat under the introduced finger, is pushed into the urethra just in front of the prostate, and when the point is felt to be in the groove, it is made to slide along it towards the bladder, dividing in its course the membranous urethra and left lobe of the prostate to the extent of an inch. The forefinger is now to be pushed along the groove, through the edges of the deep wound, and insinuated into the incision through the prostate; the staff is then withdrawn by the assistant in charge of it, whilst the finger passes into the cavity of the bladder. The forceps are next guided by the under surface of the finger into the bladder. When the stone is felt, the blades must be opened, the finger gradually withdrawn, and an attempt made to catch it in its long axis if possible. When caught, it is to be slowly and firmly drawn out, without hurry, with a slight to-and-fro motion in a direction *downwards*, towards the floor, and not horizontally towards the pubic arch. After the operation a searcher or sound is to be introduced, to find out whether the bladder is free.

Structures divided in the lateral operation, of lithotomy.—The superficial incision divides the skin and superficial fascia, inferior hæmorrhoidal vessels and nerves, which lie superficially in the anterior part of

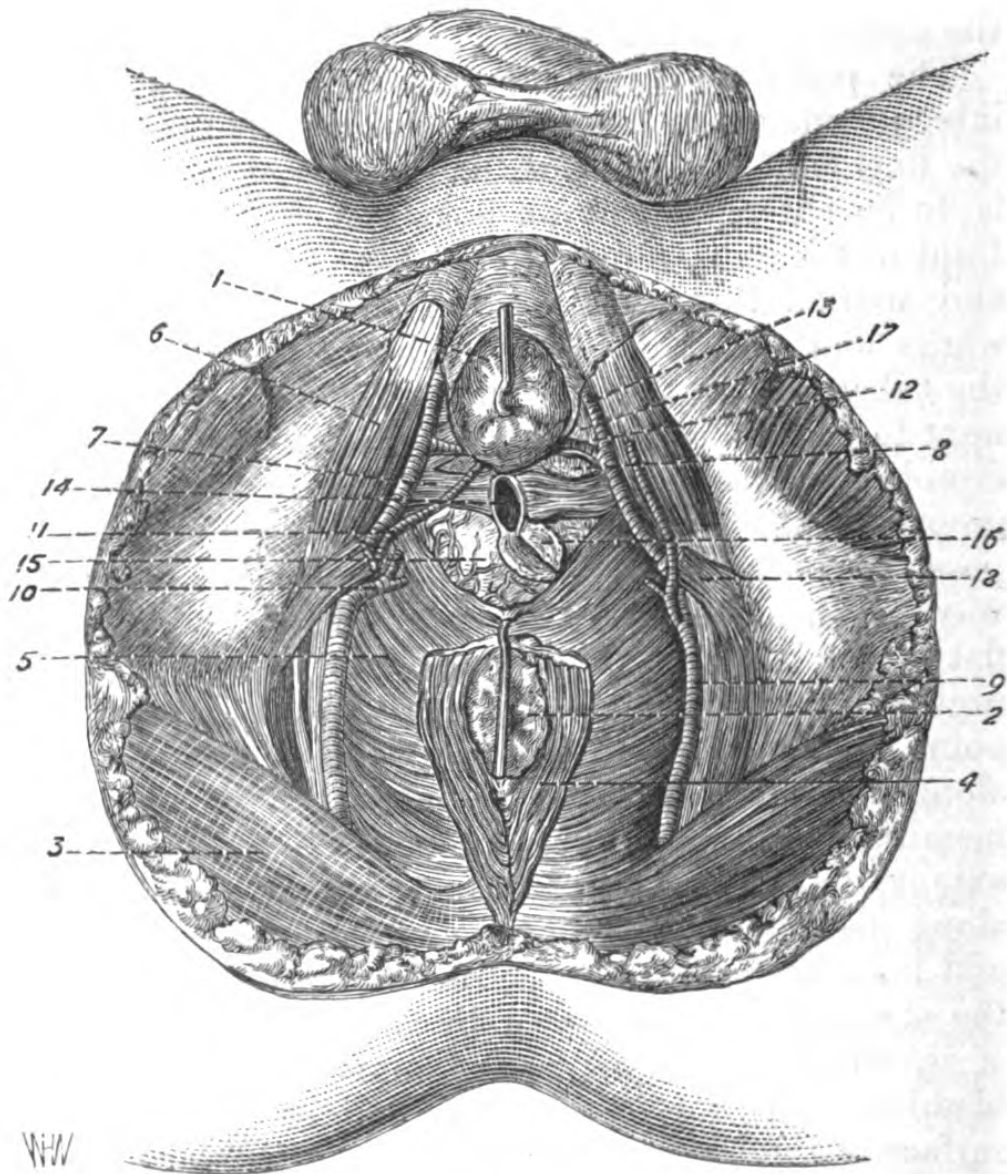


Fig. 55.—Male Perineum. The bulb is slightly raised and the rectum drawn backwards, in order to make clear the membranous urethra and prostate, which are shown incised as in the lateral operation of lithotomy.

- 1, bulb; 2, rectum; 3, gluteus maximus; 4, external sphincter; 5, levator ani, its anterior fibres raised to show the prostate; 6, erector penis; 7, Wilson's muscle; 8, Cowper's gland; 9, trunk of internal pudic; 10, superficial perineal artery; 11, artery to bulb (abnormal); 12, artery to bulb; 13, continuation of internal pudic artery; 14, urethra divided as in the lateral incision; 15, prostate gland, with its plexus of vessels; 16, incision in the prostate gland as in the lateral operation; 17, anterior layer of triangular ligament; 18, transversus perinei muscle.

the ischio-rectal fossa, transverse perineal muscles and vessels, and superficial perineal vessels and nerves. The structures divided *on* the staff are the lower part of the triangular ligament, deep transversus urethræ muscle; the *deep* part of the incision divides the membranous urethra, the substance of the prostate, and vessels around it.

Structures to be avoided.—The *bulb*, or the *rectum*, either of which stands a risk of being wounded, if the first incision be too near the middle line; the internal pudic artery, if on the other hand the deep incision be made too far externally; the *artery* to the bulb, if it be made too far forward; and the *ejaculatory* ducts, if it be carried too far backwards or downwards.

If the entire breadth of the gland and its capsule were divided, the urine would be infiltrated beneath the peritoneum probably.

The depth of the perineum between the neck of the bladder and the integument varies from rather more than an inch to four inches, and between the tuberosities of the ischium from two inches or less, to four.

In the child, the pelvis being narrow, the perineum is narrow also; and the neck of the bladder comparatively high up, whilst the peritoneum descends very low between the bladder and the rectum. The bladder itself is more conical in shape, and is rather an abdominal than a pelvic viscus, and its connexions with the surrounding parts are very loose. Hence the difficulty experienced in getting into the bladder in lateral lithotomy in children, and the danger of pushing the prostate before the finger and tearing it from the membranous portion of the urethra. There is also a danger of cutting the urethra considerably anterior to the point indicated as the exact position for entering the bladder, therefore always, in children, the external incision should be made as large as possible, that the relative position of the parts be clearly made out.

SURGICAL ANATOMY OF THE PENIS.

The integument of the penis consists, externally, of very loose skin, destitute of fat, which at the corona glandis is reflected over the glans, and has an internal mucous surface continuous with that of the glans; immediately below the meatus urinarius this membrane is gathered into a fold, the *frænum preputii*. Behind the corona, and in the sulcus, are a number of glands which secrete the smegma. Beneath the skin is a layer of loose muscular fibres, analogous to the dartos, arranged circularly and lying in loose cellular tissue. Beneath this is a tough, elastic fascia, enveloping the entire body of the organ, sending in a process beneath the urethra and corpora cavernosa, continuous with the superficial fascia of the perineum, incorporated at its root with the suspensory ligament; between the two laminae of which lie the dorsal vessels and nerves. The upper portion of the body of the penis is composed of the corpora cavernosa, which, arising from the inner aspect of the horizontal rami of the pubes, unite along the mesial line, this union being marked by a septum, called the *septum pectiniforme*, which, however, is wanting in front. The corpora cavernosa terminate in the front by a rounded margin, which projects into the base of the glans. The inferior portion of the body of the glans is formed by the corpus spongiosum, containing the urethra. It commences in front of the triangular ligament at the bulb, and lying between and below the united crura, terminates at the glans.

The *arteries* of the penis are the dorsal, which lie in the dorsal furrow, supplying the integument, and afterwards pierce its fibrous investment, near the corona; the arteries to the corpora cavernosa, and the arteries to the bulb. The *veins* are very numerous, and are superficial and deep, the former passing into the dorsal vein, which lies between the two dorsal

arteries, and generally terminates in the internal saphena; and the deep, after piercing the triangular ligament, terminate in the prostatic plexus.

The *lymphatics*, with which the organ is richly furnished, accompany the dorsal vessels and pass into the ganglia of the fold of the groin.

The *nerves* lie external to the arteries on the dorsum, and are freely distributed to the body and glans.

The penis is often the seat of an arrest of development, one form of which, where the inferior wall of the urethra is wanting, is termed *hypospadias*; and where the superior wall is wanting, and generally associated with extroversion of the bladder, *epispadias*. Occasionally the prepuce completely encloses the glans, excepting a minute orifice through which the urine passes (*congenital phimosis*).

SURGICAL ANATOMY OF THE MALE URETHRA.

The urethra may be described as extending from the neck of the bladder to the meatus urinarius, and for general division consists of one portion belonging to the penis, and of another belonging to the perineum; with the former is included the spongy portions, and with the latter the membranous and prostatic. It must be examined as regards direction, length, and calibre.

The penile urethra may be considered as the *mobile*, and the perineal, separated from it by the triangular ligament, as the *fixed* portion of the canal, and upon the change in the direction of this fixed portion depends all the difficulty of catheterism.

Spongy portion.—Commencing from the orifice of the urethra, a vertical slit provided with two lip-like margins, the urethral tube is seen at its most constricted portion. On examining the floor of the canal within the meatus, a considerable dilatation is found, termed the *fossa navicularis*, and on the roof of this part of the urethra is the orifice of a large mucous pouch, the

lacuna magna. Behind this dilatation the canal averages about a quarter of an inch in diameter, and is throughout studded, particularly on its floor, with the orifices of glands (glands of *Littre*), opening forwards. About five inches behind the orifice is another pouch-like dilatation contained within the bulb, into the floor of which open the ducts of Cowper's glands.

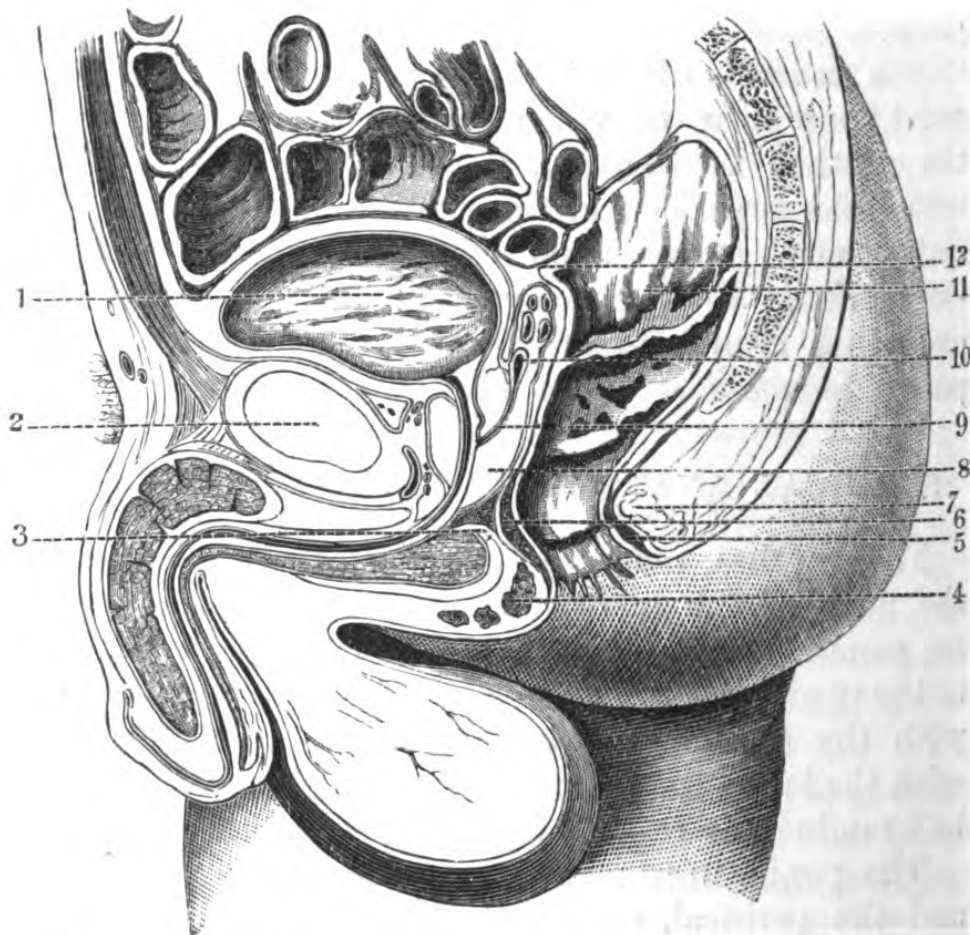


Fig. 56.—Sagittal Section of Male Pelvis in the mesial line (one-third).

1, bladder; 2, symphysis pubis; 3, bulb; 4, external sphincter; 5, internal sphincter; 6, internal sphincter; 7, external sphincter; 8, prostate; 9, ductus ejaculatorius; 10, vesicula seminalis; 11, rectum; 12, pouch of Douglas.

Membranous portion.—This is the narrowest portion of the tube throughout its length, excepting the sphincter-like orifice, and is contained between the layers of the triangular ligament; it measures about

three-fourths of an inch along its upper, and half an inch along its lower surface, and consists of mucous membrane, elastic, erectile, and muscular tissue.

The prostatic portion is the widest and most dilatable portion of the urethra; it is about an inch and a quarter long, and lies nearer the upper than the lower portions of the gland, and its tube is of greater calibre in the middle than at either entrance or exit; on its floor, at the neck of the bladder, is the uvula vesicæ, in front of which is a ridge of mucous membrane, rather deeper behind than before, called the *veru montanum* or *caput gallinaginis*, having on either side of it a pouch or sinus, into which open the prostatic ducts. At the fore part of the *veru montanum* is a cul-de-sac, running upwards and backwards beneath the middle lobe, containing on its floor the openings of the ejaculatory ducts; it is called the *sinus pocularis*.

Next, let the urethra be examined as existing during life, as it would present itself to the surgeon.

The urethra may be thus divided into a penile and a perineal portion, and the individual lying on his back, the usual position for catheterism, its direction can be conveniently described as an ascending portion, terminating at the root of the penis, the bulbous portion, and a descending, comprising the membranous and prostatic. Thus the points where the urethra changes direction are at the root of the penis and bulb, and it is in this portion of the canal that false passages are most frequently made. These curves disappear on catheterism; the first by merely raising the penis, and the second on the depression of the handle of the instrument between the thighs. So resilient are the urethral walls that a perfectly straight instrument can be readily introduced into the bladder. The urethral canal is distant from the under border of the symphysis about half an inch or a little more, and is consequently about half an inch or a little more below the vesical aperture, which corresponds with the lower border of the symphysis, and is about an inch

and a quarter behind it. When not in use the walls of the urethra touch each other, excepting at the orifice of the meatus urinarius and in the bulb, where they are separated by a narrow interspace.

Catheterism of the male urethra.—If the urethra be healthy, the sound or catheter will pass almost by its own weight, and require scarcely any urging. The instrument is to be introduced into the orifice of the urethra, and pressed gently onwards until it has traversed the canal for four or five inches, when the handle is to be brought to the middle line close to the abdomen, in order that the point may traverse the curve below the symphysis; the handle is then to be brought gently down between the legs of the patient, when it should glide into the bladder. The great point is to keep the extremity of the instrument traversing the *upper* wall of the urethra. Besides, being less moveable, experience shows that in cases of stricture, the upper wall is less liable to be affected than the base and sides. In introducing a small instrument, the position of the lacunæ must be borne in mind, particularly that of the lacuna magna, on the upper wall of the navicular fossa, as it is liable to intercept its point; and if force be employed, it might pass *beneath* the mucous coat. In cases of difficulty, by passing the finger into the rectum the point of the instrument can be directed into the bladder, on account of the close relation of the membranous portion of the urethra and the rectum, and the readiness with which the catheter or sound can be felt through it.

Catheterism in the female is a very easy proceeding generally, and the little papillar orifice which is situated about an inch below the clitoris, in the back part of the vestibule, being detected, a straight instrument is readily slipped in without exposing the patient. When any difficulty is experienced, it is owing to some deviation of the canal or of the neck of the bladder, caused by some tumour pressing upon the parts, which are very mobile.

In *lithotomy in the female* the vesico-vaginal operation is the best, providing the resulting fistula be properly treated. There is, however, a chance of permanent incontinence of urine, on account of the function of the urethral sphincter being destroyed by the incision into the neck of the bladder having been made too freely. It must be borne in mind that when the bladder is fully contracted, the septum between the bladder and vagina is very limited; moreover, in this condition the openings of the ureters are brought very low down, and might be implicated in the incision, which is on no account to be transverse. The length of the female urethra is about an inch and a half, curving slightly below the symphysis, with its concavity upwards, and having an average diameter of about a quarter of an inch, and being highly distensible, very frequently calculi can be extracted through it. There is a good deal of difficulty experienced generally in using a lithotrite in the female bladder, owing to the fact of its muscular coat being so thick and strong and its urethral sphincter so weak, that the urine, or water injected for the purpose of operation, escapes past the instrument, leaving no cavity; moreover, the bladder forms a fossa on both sides of the neck of the uterus.

The arrangement of the *perineal aponeuroses* in the female is as follows:—The superficial layer of superficial fascia is continuous with that of the nates, thigh, and abdomen; whilst the deeper layer is firmly attached to Poupert's ligament, the ischio-pubic rami, and to the lower border of the perineal septum. These fasciæ are met with in the labia majora, which are very analogous to the scrotum in the male, and being attached above to the external abdominal ring, herniæ pass in them, known as pudendal or labial herniæ. This deeper layer of fascia is continuous over the ischio-rectal fossæ. Where the two layers of superficial fasciæ unite with the lower borders of the perineal septum to form the perineal body, they are

joined by the ischio-perineal ligament, and it forms a support, or *point d'appui*, for the perineal muscles.

Abscesses in the female perineum are of two kinds, diffuse, in the superficial perineal fascia, which readily spread in all directions; and circumscribed abscess of the vulvo-vaginal gland, which would be seen as an oval projection on the side of the vestibule.

The sacro-coccygeal region offers for surgical consideration a common arrest of development of the neural arches of the sacrum, constituting *spina bifida*, and resulting in the formation of a large cystic swelling; and the nerves (*cauda equina*) are in this region usually connected with the sac. Hence, if the operation of puncture be deemed advisable, it should always be made on one side of the sac, and at its lowest part.

SURGICAL ANATOMY OF THE CAVITY OF THE PELVIS.

The pelvic cavity contains those viscera, the inferior relations and apertures of which have been described in the preceding section—viz., the bladder, rectum, and vagina, with the uterus and ovaries, the superior surface of the perineum forming its inferior boundary. The soft parts lining its bony walls, the obturatores interni, pyriformes, and levatores ani muscles, are invested with the reflexion of the pelvic fascia, upon which lie the peritoneum and subperitoneal cellular tissue, the arrangements of which are of considerable importance surgically.*

The *pelvic fascia*, which is continuous with the fascia iliaca, is itself a continuation of the transversalis fascia. It is attached to the brim of the true pelvis, and round the margin of the obturator internus muscle. At a curved line between the spine of the ischium and the pubes, this fascia splits to enclose part

* The surgical anatomy of the uterus and ovaries will be better studied in special works on obstetrics.

of the origin of the levator ani muscle, the external lamina of which (obturator fascia) is applied to the inner surface of the obturator internus muscle, and passing beneath the obturator vessels and nerve, completes the obturator canal; it is attached below to the pubic rami, where it forms an investment for the internal pudic vessels and nerve. It afterwards sends a thin fascia, the anal, over the lower surface of the levator ani, which is to be seen covering it in the ischio-rectal fossa. The internal lamina (the recto-vesical), is continued over the upper surface of the levator ani, over the bladder and sides of prostate, and lower end of rectum. The pubo-prostatic ligaments are formed by two short rounded bands extending from the capsule of the prostate to the posterior aspect of the symphysis; the capsule of the prostate is formed from the lateral attachment to it of this fascia, which also encloses the vesico-prostatic plexus of veins. It is this portion of the pelvic fascia which it is so important to avoid dividing posteriorly in the operation of lateral lithotomy, for by so doing the urine would find its way into the loose areolar tissue, between the rectum and the bladder. The presence of the prostatic plexus of veins is often a serious source of danger. Posteriorly, the pelvic fascia is continuous over the pyriformis muscle and sacral plexus, being perforated by the internal iliac artery and vein.

The inlet of the pelvis is somewhat heart-shaped, well padded along its upper border by the psoas and iliacus muscles, while posteriorly, in the middle line, is the promontory of the sacrum, or sacro-vertebral angle, which can be readily felt through the abdominal parietes in thin persons. Between the bladder and rectum is the *recto-vesical pouch*, formed by the pelvic fascia, which corresponds posteriorly where it is broad to the interval between the iliac arteries; it is narrow in front between the rectum and the bladder, and extends as far as the vesiculæ seminales and, in front and behind, to the tip of the coccyx. Its relation to

the orifice of the anus is important, and must be referred to the condition of the bladder, which, if distended, will raise the pouch further into the pelvic cavity than its usual level, which is about three inches above the anal aperture. Some coils of the ileum and sigmoid flexure of the colon fill in the space. The peritoneum affording no investment to the lower end of the rectum, the neck, base, and anterior surface of the bladder, or the front and inferior portion of the posterior wall of the vagina, permits of operative proceedings upon these viscera, without danger of wounding it. The space beneath the membrane varies considerably in different parts of the floor of the pelvis: thus, in front and at the sides it is tolerably closely applied to the underlying pelvic fascia, leaving, however, a considerable interspace in front of the bladder, the point selected for puncturing that viscera above the pubis. Behind, and above the anal region, there is a considerable interval, containing a great deal of loose cellular tissue, which allows of the distension of the rectum, and of the internal iliac vessels and their branches, the ureters, sacral, sympathetic and hypogastric plexuses, and the origin of the pyriformis muscle. (*Vide* "Rectum.")

SURGICAL ANATOMY OF THE BLADDER.

The bladder is situated in the mesial plane, beneath the pelvic fascia and peritoneum, and lies obliquely from above downwards. Being attached to the pelvic floor by its body and base only, it is freely moveable, but the urachus and anterior reflexion of the peritoneum limit its mobility posteriorly. When empty, the bladder lies deep in the pelvis as a flattened sac, with its apex reaching up to the symphysis pubis, but when distended, its relations are considerably altered, and are of great surgical importance. When moderately full, it is round and partially fills the true pelvis,

but when greatly distended it rises up into the abdomen, perhaps even reaching to the umbilicus, and becomes curved forwards.

In front of the bladder, between it and the pubes, is a quantity of lax cellular tissue, and the peritoneum being reflected from its anterior surface, forwards and upwards, allows of its dilatation, and is of great practical importance in percussing the bladder. It is here that puncture over the pubes and the "high" operation of lithotomy are practised, but the frequency of urinary infiltration is greatly against the latter proceeding. However much the bladder may be distended posteriorly, this peritoneal cul-de-sac undergoes no modification in its relation to that viscera, on account of the presence of the prostatico-peritoneal aponeurosis. Its posterior surface is entirely covered by peritoneum, and is contiguous in the male with the rectum, and in the female with the vagina, and is in relation with some convolutions of the small intestine, which lie in the recto-vesical pouch. Laterally, the peritoneum is applied to the bladder above and behind the crossing of the obliterated umbilical artery, around which it is reflected. The vasa deferentia pass along the side, cross the obliterated umbilical artery, and lie to the inner side of the ureter.

The base of the bladder lies upon the anterior surface of the rectum, from which it is separated merely by a thin layer of cellular tissue in the middle, and laterally by the vesiculæ seminales and vasa deferentia, the former of which are intimately adherent to it, and form two sides of a triangle, the base of which is directed upwards and backwards, and its apex towards the prostate. It is at this spot that puncture of the bladder by the rectum is performed. The neck of the bladder is surrounded by the prostate, and is directed obliquely forwards and downwards.

The general form of the normal *prostate* is that of a chestnut, with its base directed towards the bladder, and its apex towards the symphysis, having its longest

diameters antero-posteriorly, and at its base transversely. Its inferior surface rests on the triangular ligament; its upper surface, slightly concave, is intimately connected with the bladder and ejaculatory ducts, which lie together in the middle line immediately behind it. Its anterior surface corresponds to the deep layer of the triangular ligament (pubo-prostatic ligament); the posterior surface is separated from the rectum simply by a little cellular tissue and is applied to the neck of the bladder; and its sides are in relation with the levator ani and with the pelvic fascia. The prostate is invested by a fibrous capsule, derived from the pelvic fascia. The density of this capsule accounts for the intense pain of prostatic abscesses, and forces the pus to find its way, unless relieved, into the urethra. In opening these abscesses in the perineum, there is a possibility of urinary fistula, and in the event of their bursting in the perineum, such fistulæ are certain to form.

The *position of the prostate gland* with regard to the perineum is readily determined by passing the finger into the rectum, and the organ, if healthy, is generally felt about as far up as the second joint of the forefinger reaches, whilst in some forms of enlargement, the upper border of the gland will be far out of reach of the entire finger.

The cavity of the bladder presents at its base the *trigone vesicæ*, an equilateral triangle formed by the oblique openings of the ureters posteriorly, and by the urethra anteriorly. It is through this triangular space that the trocar enters in puncture per rectum. The trigone is perfectly smooth, and free from rugæ.

Immediately behind the trigone, is the deepest part of the bladder, the *bas fond*—not very much marked in children, but forming a considerable pouch in old persons if there is urethral or prostatic obstruction, in which the urine settles, causing considerable irritation. It is in this pouch that calculi lodge generally.

In the female the bladder is rather larger and rounder than in the male. It has no *bas fond*. The

neck is lower, and it and the posterior portion of the bladder lies on the vagina; hence it does not descend as low as in the male, and its posterior surface is entirely covered by the peritoneum. Fistulous openings occasionally occur between the bladder and vagina.

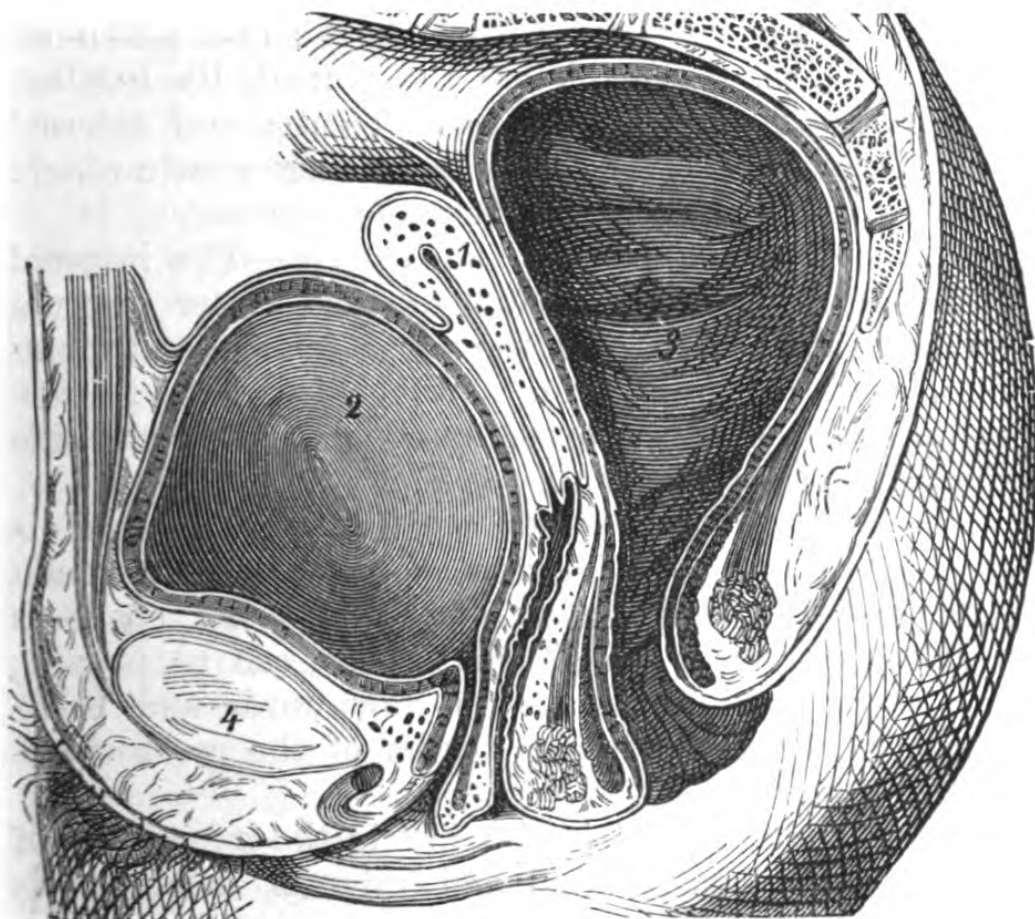


Fig. 57.—Sagittal Section of Female Pelvis (one-half).

1, uterus; 2, bladder; 3, rectum; 4, symphysis.

In *children*, the bladder is rather an abdominal than a pelvic viscus, and is conical in shape, owing to the position of the but recently obliterated urachus.

Vessels.—The vascular supply of the walls, soft parts, and viscera of the pelvis is derived from the branches of the internal iliac and from the middle sacral artery.

After birth the internal iliac consists of two trunks, an anterior and a posterior—a subdivision which takes

place opposite the great sacro-sciatic notch. The branches given off from the *anterior* are those to the bladder and prostate; superior vesical (the pervious portion of the foetal hypogastric artery), middle and inferior vesical, the middle hæmorrhoidal to the rectum, the obturator, the internal pudic and ischiatic, and the uterine and vaginal in the female. Those given off from the posterior trunk are the gluteal, ilio-lumbar, and lateral sacral. The gluteal, ischiatic, and internal pudic leave the pelvis by the great sacro-sciatic notch, passing between the sacral plexus of nerves.

Relations of the internal iliac artery.—The internal iliac has, in front, the peritoneum and ureter (rectum on left side); *externally*, the psoas muscle, and obturator nerve; *behind*, the internal iliac vein, lumbosacral nerve, and pyriformis muscle; on the right side the vein is more external.

Ligature of internal iliac artery.—This vessel is reached by the same incision as that for the common iliac, and the bifurcation being found, the space is very limited upon which the ligature can be placed; the short thick trunk passes downwards and backwards as far as the upper border of the great sacro-sciatic notch.

The *external* iliac vein lies just in the bifurcation of the common into external and internal iliac, and is liable to be in the way of the needle in passing the ligature. The lumbar and sacral arteries chiefly carry on the circulation after its ligature.

RECTUM.

The rectum is a direct continuation of the sigmoid flexure, and commences at the level of the left sacro-iliac synchondrosis, and terminates at the anus.

Lateral curvatures.—From the sacro-iliac synchondrosis the rectum at first inclines a little to the right, across the median line, then it reverts again to the left.

Antero-posterior curvatures.—After its commencement, the rectum corresponds with the curve of the sacrum, and follows it to the apex of the coccyx, adapting itself to the posterior wall of the pelvis, so that its concavity looks directly forwards. In the male the anterior concavity corresponds with the convexity of the bladder, and its lower corresponds with the apex of the prostate, at which point the gut passes abruptly forwards, and after a course of between one and two inches terminates at the anus.

It is very important to recollect this in introducing instruments, such as specula or sounds, or indeed the finger into the rectum.

Calibre.—This is not uniform. The straight portion that is enclosed by the sphincters is closely approximated, and offers some resistance to the introduction of the finger. Immediately above this the rectum dilates, forming a kind of pouch or ampulla; the gut then becomes regularly cylindrical. With care and patience, the entire hand and part of forearm may be introduced into the rectum, a fact of importance in the diagnosis of abdominal tumours, etc. By passing the entire hand into the rectum in a case of intestinal obstruction, the author detected a rare form of hernia, in which the small intestine had passed between the bands of muscular tissue of the rectum, and protruded into it, completely blocking up its canal, and which was operated on successfully.* (The curves of the rectum, considered from below upwards, have been already described.)

Relation of the rectum to the peritoneum.—This is of great surgical importance. The rectum may be readily divided into an intra- and extra-peritoneal portion. The peritoneum descends lower on its anterior than its posterior surface. It is attached by a small mesentery to the anterior surface of the sacrum, which allows of its free movement in the pelvis, when empty, and as distension occurs its laminae separate, and

* *Vide* "Trans. Clin. Soc." 1879.

afford room for this distension. At the base of the vesiculæ in the male, or the upper fourth of the vagina in the female, it is reflected so as to form a cul-de-sac, which is distant from the anus about two and a-half inches when the bladder is empty, and about three when full.

From the anterior surface the membrane is reflected very obliquely upwards and backwards, and the point where it covers the posterior wall of the rectum is from four to five inches from the anus. These measurements are of great importance in conducting operations for the removal or partial removal of the rectum, or of operations on the bladder or prostate.

CHAPTER VI.

SURGICAL ANATOMY OF THE LOWER EXTREMITY.

THE region of the hip includes, anteriorly, the superior femoral region, or the upper third of the front of the thigh, immediately below Poupart's ligament; posteriorly, the gluteal; and internally, the ischio-pubic or obturator. These several regions cover in the articulation of the hip-joint. The region of the hip-joint may be described as having for its limits, the iliac crest and sacral groove, Poupart's ligament, and below, a line encircling the limb, just below the fold of the nates.

Surface markings.—*Anteriorly* and *externally*, are the muscular prominences formed by the tensor vaginae femoris; and *internally*, by the adductors and gracilis.—this surface is crossed obliquely below by the sartorius. *Posteriorly*, is the swell of the gluteus maximus; and *internally*, the tuberosity of the ischium, and the rami of the pubes and ischium covered by their muscles.

SURGICAL ANATOMY OF THE SUPERIOR FEMORAL REGION.

The more superficial structures met with in this region have been already described in the chapter on inguinal and crural herniæ, as it was considered convenient to associate them with the region of the abdomen (*vide* "Abdomen"); but the deeper surgical

relations comprise those of the common femoral and upper portion of the superficial femoral vessels, or *Scarpa's* space.

The structures which concern femoral hernia have already been described, with the arrangement of the *fascia lata*, in its superficial aspect. From the inner surface of this fascia spring two strong prolongations, one an external starting from the junction of the external and posterior aspects of the thigh, and becomes attached to the external edge of the *linea aspera*, the other internal commences at the junction of the internal and posterior aspects of the thigh, and becomes attached to the posterior surface of the preceding lamina, thus dividing the thigh into two distinct aponeurotic sheaths, which become more developed in the middle femoral region, where they will be described.

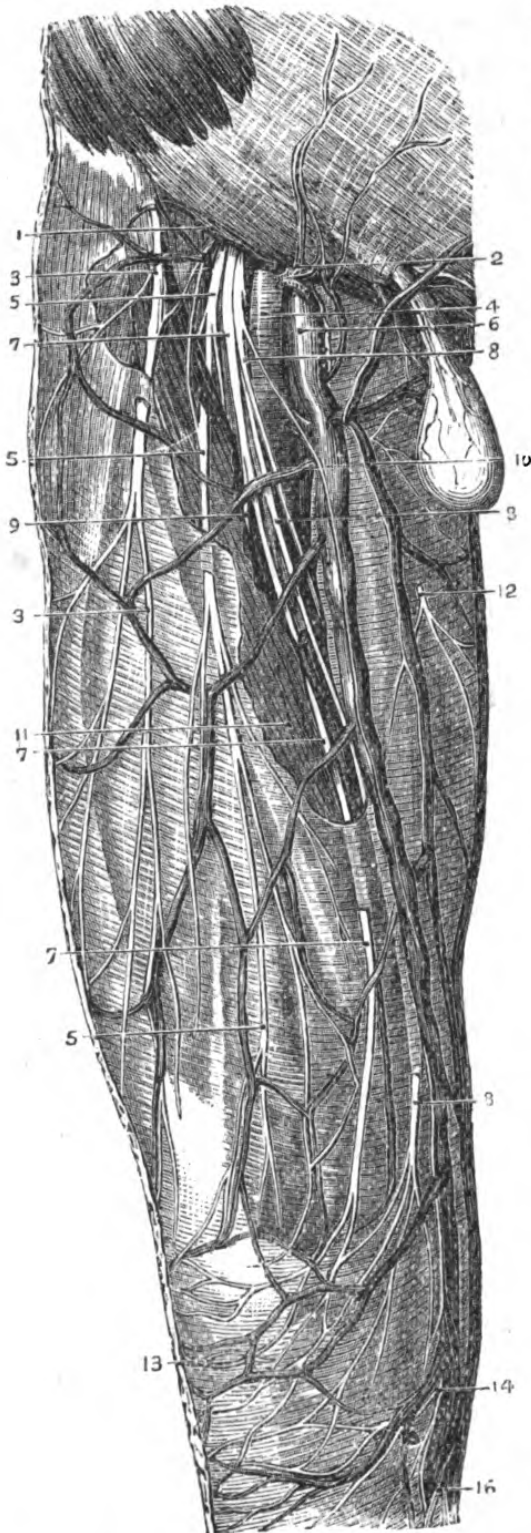
Scarpa's triangle.—This space has for its limits the following:—its *base*, the crural arch; its *external* boundary, the sartorius; its *internal*, the adductor longus. In the centre of the triangle so formed, passing from the middle of its base to the apex (the meeting of the sartorius and adductor longus), lie the femoral vessels. The floor upon which they rest is formed from without inwards by the iliacus, psoas, pectineus, adductor longus, and part of the adductor brevis muscles. The anterior crural nerve lies in the furrow between the iliacus and psoas muscles. The femoral artery lies external to, and a little superficial to its vein. The sheath of the femoral vessels, which has been before described (*vide* “Crural Hernia”), ceases at the division of the common femoral into superficial and deep, and is formed anteriorly by a prolongation of the *fascia transversalis*, and posteriorly by the *fascia iliaca*, which furnish septa between the common femoral vessels. The inner margin of the psoas separates the artery from the hip-joint, and passing behind the sheath is the branch of the anterior crural nerve to the pectineus. Lying on

the pectineus, and outer surface of the adductor longus, are the deep external pudic vessels, branches of the common femoral, beneath the pubic portion of the fascia lata.

On the outer side of the sartorius is the tensor vaginæ femoris, passing obliquely downwards and backwards, to be inserted into the fascia lata ; and between it and the sartorius is the upper portion of the rectus femoris, with some branches of the external circumflex vessels passing outwards into its substance. Passing inwards towards the articulation, will be met with, from without inwards, beneath the sartorius and vessels, the lower portion of the combined tendons of the psoas and iliacus in their sheath ; a cellular interspace between them and the outer border of the pectineus, in which lie the internal circumflex vessels, the pectineus, and the adductor brevis, also separated by a slight interval. Beneath, the upper portion of the rectus and the external circumflex vessels, the upper part of the vasti, the neck of the femur, and the anterior portion of the articulation. Immediately behind the psoas and iliacus tendon and the pectineus, are large bursæ separating them from the joint. Beneath the pectineus and adductor brevis are the obturator vessels and nerve, the obturator externus, and portion of the adductor magnus muscles.

Femoral artery in Scarpa's space.—The common femoral is a continuation of the external iliac, and enters the space below Poupart's ligament, at a point midway between the anterior superior spine of the ilium and the symphysis pubis, and it lies in the crural sheath for about an inch and a half or two inches, which sheath separates it from the fascia lata and inguinal glands.

The common femoral vein lies to its inner side above, but gets behind it lower down. The anterior crural nerve lies about half an inch external to it. It lies at first on the psoas and afterwards on the pectineus, but separated from it by the femoral vein and



profunda vessels. It usually gives off four superficial branches — the superficial epigastric, circumflex iliac, and the superficial and deep external pudic. (By the *superficial* femoral is meant that portion of the vessel between the giving off of the profunda and the point where it becomes popliteal.) The *profunda* or *deep* femoral generally arises from the outer and back part of the common trunk, about an inch and a half or two inches below the crural arch; at its commencement this vessel is on the outside of the superficial femoral vessels; but it soon passes behind, and finally reaching the inside, courses downwards and backwards among the adductor muscles. It rests on the iliacus,

Fig. 58.—Superficial Dissection of the Front of the Thigh.

1, Poupart's ligament; 2, superficial branches of femoral artery; 3, external cutaneous nerve; 4, femoral artery; 5, 5, 5, middle cutaneous nerve; 6, femoral vein; 7, 7, 7, outer division of internal cutaneous nerve; 8, 8, 8, inner division of internal cutaneous nerve; 9, branch to sartorius; 10, saphena vein; 11, sartorius plexus; 12, cutaneous branch of obturator nerve; 13, patella; 14, patellar branch of long saphena; 16, long or internal saphenous nerve.

pectineus and adductor brevis, and passing between the adductor longus and magnus, terminates in a small twig that pierces the magnus. The profunda gives off the *external circumflex*, which, arising from its outer side, passes outwards between the branches of distribution of the anterior crural nerve, below the sartorius and rectus, and divides into three series of branches—ascending, descending, and transverse. The *internal circumflex* is given off from the inner and back part of the profunda, passes between the pectineus and psoas muscles, and opposite the tendon of the obturator externus, it gives off two branches: one an ascending, inosculating with the obturator, and a descending, muscular; and the vessel itself passes into the gluteal region between the quadratus femoris and adductor magnus, inosculating with the ischiatic, external circumflex, and superior perforating vessels. The *perforating* arteries.—The first is generally given off from the profunda, just above the tendon of the adductor brevis, between it and the pectineus, and pierces the adductor magnus; the second pierces the adductor brevis and magnus; and the third is given off below the adductor brevis, and pierces the adductor magnus. The inosculations of these vessels will be considered in the description of the thigh and buttock.

Compression of the femoral artery in the upper third is easily effected, either just as it passes over the pubes, where the pressure should be made obliquely backwards, on account of the surface of the bone being inclined slightly forwards, or just below Poupert's ligament, at a point where it is very superficial, being separated from the acetabulum and neck of femur by the psoas in extension of the thigh.

Ligature of the femoral artery in Scarpa's space.—Except in the case of a wound of the vessel, the *common* femoral is rarely tied, owing to the number of small superficial and muscular branches, affording but little chance of a good coagulum being made. For popliteal aneurism, etc., the superficial femoral is tied just at the point before it passes beneath the sartorius.

The knee being slightly bent, an incision of about two or three inches in length is to be made over the course of the artery, dividing the skin, superficial fascia, and fat. Next the fascia lata is to be divided, when the oblique fibres at the edge of the sartorius will be seen, and which are to be drawn aside in order to give room. Some branches of the anterior crural nerve are generally spread out over the course of the vessel, and occasionally the internal saphena nerve crosses it at this point. The sheath is next to be opened, only so much so as to allow of the easy passage of the aneurism needle round the vessel, and the needle should be passed *from within outwards*.

Collateral circulation after ligature of the superficial femoral artery in Scarpa's space.—The external circumflex from the profunda anastomoses with the gluteal and circumflex iliac, the internal circumflex with the obturator ischiatic, and superior perforating, and the vessels in the popliteal space with the comes nervi ischiadici.

The *tumours* in Scarpa's space, which might be mistaken for aneurisms, are enlarged glands, cysts, * psoas abscess, enlargement of the bursa below the psoas, and hernia. Femoral herniæ lie to the inner and upper side of the vessels; psoas abscesses point external to them. Inguinal herniæ may be mistaken for crural, owing to the circumstance that adhesions taking place from any cause between the aponeuroses may divert their course; it is far more common for crural herniæ to resemble inguinal (*vide* "Crural Hernia").

SURGICAL ANATOMY OF THE GLUTEAL REGION.

This region is of great surgical importance from its intimate relations with the hip-joint, and the control the muscles have over its several movements; it has for its limits, in *front*, the anterior superior spine of the ilium, and the margin of the tensor vaginae femoris;

superiorly the crest; *posteriorly* the posterior superior spine of the ilium, the sacrum, and the middle line of the body; *below* the tuberosity of the ischium, and fold of the nates.

Topography.—Beneath the skin there is a considerable amount of fat, particularly over the tuberosity of the ischium, in which lie a number of cutaneous nerves, supplying the integument; the fascia lata, which is thin over the gluteus maximus, and very thick in front over the gluteus medius, to which it gives origin; next, the gluteus maximus, and the anterior and superior portion of the medius.

Beneath the gluteus maximus lie, first of all, a fibro-cellular layer, continuous with the subperitoneal cellular tissue through the great sacro-sciatic notch, a portion of the gluteus medius, sacro-sciatic ligaments, pyriformis muscle, with the sciatic vessels and nerves emerging below its inferior border; the obturator internus, with its satellite muscles, the gemelli; the internal pudic vessels and nerve with the nerve to the obturator internus, the quadratus femoris, the tuberosity of the ischium with the origin of the hamstring muscles, the great trochanter covered by a large bursa mucosa, which separates it from the gluteus maximus, and part of the origin of the vastus internus, the superficial gluteal vessels, and the anastomoses of the external circumflex with the gluteal vessels, the gluteus minimus muscle, the posterior part of the articulation of the hip-joint; and beneath the quadratus femoris, the obturator externus and the anastomosing branch of the internal circumflex.

The gluteal artery, generally the larger terminal branch of the posterior division of the internal iliac, passes out of the pelvis, at the upper part of the great sacro-sciatic notch, and lies between the gluteus minimus and pyriformis. It may be the seat of aneurism, either idiopathic or traumatic, and the vessel in either case may be readily reached in actual practice, without attendance to the somewhat com-

plicated directions given for finding it; in the former case the swelling caused by the position of the sac, and in the latter the direction of the already existing external wound, would guide the surgeon.

The internal pudic artery lies very deep in the gluteal region, and having escaped between the pyriformis and levator ani, emerges from the pelvis at the great sacro-sciatic notch, and winds round the spine of the ischium accompanied by its nerve; again reaching the pelvis at the lesser sacro-sciatic notch, it lies on the inner surface of the ischium, and is there covered by a process of the obturator fascia (*vide* "Perineum").

The great sciatic nerve emerges from the greater notch at its lower portion, and lies exactly between the tuberosity of the ischium and the great trochanter.

The inter-muscular, cellulo-fatty membranes, which are so extensive in the gluteal region, freely inter-communicate with those within the pelvis, and readily explain the passage of pus either from or into its cavity.

Sciatic herniæ occasionally exist, a portion of intestine passing down through the greater sacro-sciatic foramen, and having the vessels posterior to its sac.

The bursa over the great trochanter is sometimes the seat of abscess, which has been mistaken for disease of the hip-joint.

OBTURATOR OF ISCHIO-PUBIC REGION.

This forms the inner boundary of the region of the hip, and comprises the obturator foramen, the structures covering it on either surface, and the parts immediately adjacent. The bony prominences are easily felt; they are the pubic space and horizontal ramus of the pubes anteriorly, and the descending ramus and tuberosity of the ischium, internally and behind. The anterior surface consists of the gracilis, pectineus and adductors, beneath which is the obturator internus. The obturator foramen is not entirely filled in by the membrane,

which is wanting just below the groove through which the obturator artery and nerve pass. Attached to the inner or pelvic surface of the membrane and to the bone around, is the obturator internus, having the obturator fascia below, between it and the levator ani, and the peritoneum above; it is intimately connected with the margins of the obturator membrane, and assists in forming the *obturator canal*. This obturator canal is about three-quarters of an inch in length, and directed obliquely from above downwards, and from without inwards.

Obturator hernia.—Occasionally a hernia protrudes through the canal, and forms a swelling in the adductor or pubic region, emerging upon the thigh, below the horizontal ramus of the pubes, to the inner side of the capsule of the hip-joint, having the femoral vessels in front, and a little to the outer side, the tendon of the adductor longus to the inner side, and behind, the pectineus muscle. The obturator vessels and nerve also pass through it to the thigh, and the pressure exerted by the hernia upon the nerve induces pain in those regions to which it is supplied, and is a fact of importance in diagnosis.

SURGICAL ANATOMY OF THE HIP-JOINT.

The hip-joint itself lies enclosed in the foregoing regions, which have been described from the surface inwards; and before entering upon a description of this joint, it is important to examine the relations of the muscles to the articulation, and their control over its movements, in order to understand the exact position of the head of the femur in the several dislocations to which the joint is liable, and their action upon the upper portion of the thigh bone in fractures.

Immediately in *front* of the joint is the tendon of the psoas and iliacus (separated from the capsular ligament by a bursa); *above* is the reflected tendon of the rectus femoris and the gluteus minimus, closely interwoven with the capsule; *internally* the obturator externus

and pectineus; *posteriorly* the pyriformis, obturator internus, and gemelli, tendon of obturator externus, and quadratus femoris. All these muscles are in absolute relation with the capsular ligament, and are covered in by the superficial muscles already described. As masses, however, the musculature of the hip-joint is, on account of the relation of the great trochanter to the upper portion of the diaphysis of the femur, somewhat irregularly distributed, so that, externally, it is covered only by the fascia, the tendon of the gluteus maximus, and the skin. Below the great trochanter is a thin muscular layer from the vastus externus; whereas internally is the largest amount of muscles, the adductors, pectineus, gracilis, sartorius, and posteriorly, the joint is completely covered in by the gluteus maximus. It is worth recollecting that the joint is nearer to the anterior iliac spine than to the pubic spine.

Being an enarthrodial joint, the movements of which it is capable are very extensive:—*Flexion*, which is produced by the psoas and iliacus, sartorius and rectus femoris. *Extension*, by the hamstrings and some fibres of the gluteus maximus. In both these movements the neck of the femur rotates on its axis, whilst the inferior extremity of the thigh bone describes an arc of a circle, directly backwards and forwards. *Adduction* is performed by the pectineus, adductors, and gracilis. In this movement the shaft of the femur is adducted to the middle line of the body, and its neck is lowered. *Abduction*, by the gluteus medius and minimus, and the tensor vaginæ femoris. The neck of the femur is raised. *Rotation outwards*, in which the trochanter major is thrown backwards and the foot outwards, by the gluteus maximus and medius, pyriformis, obturators, and quadratus femoris. *Internal rotation*, when the great trochanter is thrown forwards and the foot inwards, by the anterior fibres of the gluteus medius and the gluteus minimus.

It will be seen that the greater part of these muscles

are external rotators, and it has been considered that this fact explains the corresponding rotation of the thigh in fracture of the neck of that bone, but it is much more probable that the eversion of the limb is due simply to its own weight. External rotation, however, is of no diagnostic value in fracture of the neck, unless accompanied by actual shortening of the limb.

The *trochanter major* is the great lever into which are inserted the rotator muscles of the hip-joint, and is separated from the integuments by the anterior edge of the tendon of the gluteus maximus, beneath which is a large bursa. Its variable position is readily seen in the several movements of the hip, describing the arc of a circle, owing to its continuity with the neck of the femur. When the neck of the femur is fractured, the trochanter major rotates in the axis of the bone, and in case of dislocation, or suspected dislocation, measurements of its distance from the anterior superior iliac spine must be carefully compared with similar measurements taken on the opposite side of the body.

The position of the *trochanter major*, with regard to the several bony projections of the region should be carefully studied in every position of the limb. Its situation is marked by a deep depression, when the individual is standing upright with the heels together, and its differences of relation in flexion, extension, adduction, and abduction, should be compared. These relations are obviously of the utmost importance in the diagnosis of dislocation or fracture connected with the hip-joint.

If the exact relations of the great trochanter with the several osseous prominences observable on the pelvis in a normal state be examined, it will be noticed that if the femur is flexed at a right angle, and at the same time slightly adducted, the apex of the great trochanter corresponds with a line drawn from the anterior superior iliac spine to the tuberosity of the ischium, and that this line divides the cotyloid cavity

(which, with respect to the surface, may be regarded as occupying the central position between the anterior superior spine of the ilium, the spine of the pubis, and the tuberosity of the ischium) into two equal parts. This line corresponding to the centre of the cavity, will serve as a guide to an appreciation of the extent of displacement in dislocation. Thus supposing the head of the femur be placed behind the cotyloid cavity, this line, instead of corresponding with the apex of the trochanter major, would correspond with a point nearer its base. The extent of the displacement, then, will be measured by the prominence of the great trochanter behind this line. (Nélaton.)

The *triangle* Bryant* describes as the *ilio-femoral*, is formed between the ilium and the great trochanter of the femur. *One* side of it is drawn from the anterior superior spinous process of the ilium to the top of the major trochanter.

The *second* is drawn from the anterior superior spinous process of the ilium directly downwards to the horizontal plane of the recumbent body; and the *third*, which would be the base of the triangle, is drawn at right angles to the second, and falls upon the first line, where it touches the great trochanter.

Mr. Bryant says that first the line corresponds in the normal position of the hip-joint to Nélaton's test line for dislocation of the head of the thigh-bone backwards; and he claims the base of the triangle to be the test line for fracture or shortening of the neck of the thigh bone; and he asserts that whilst in a healthy subject the ilio-femoral triangles of the two sides are exactly similar, in all cases of injury to the hip, in which shortening of the neck of the thigh-bone exists, the amount of shortening can readily and accurately be made out, on comparing the bases of the triangles of the two sides. Again, in impacted fracture, where on the sound side the base of the triangle

* Proceedings of Royal Medical and Chirurgical Society, vol. vii. No. 7.

will in the adult measure its average normal length of two and a half inches, on the affected or impaired side

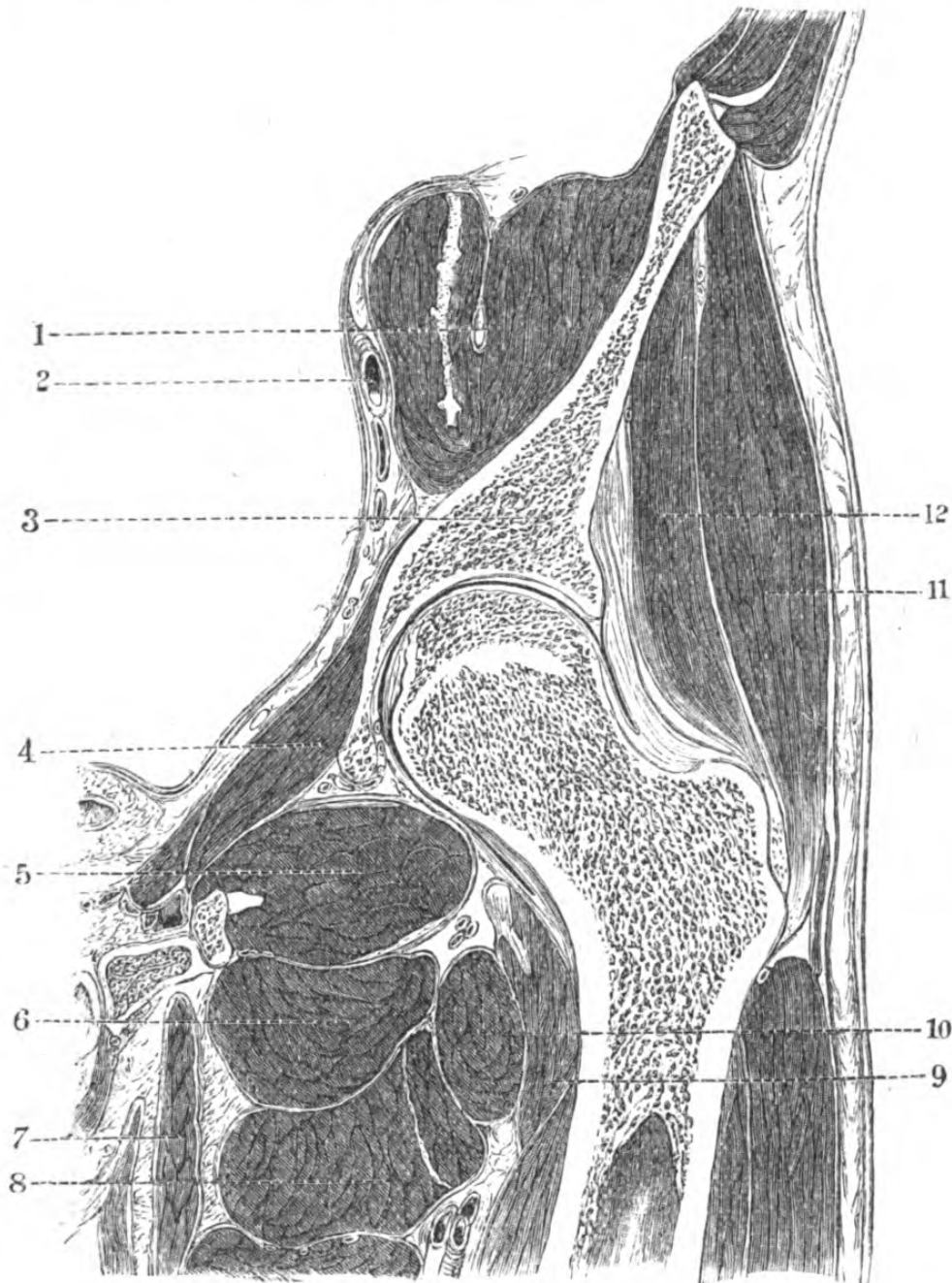


Fig. 59.—Transverse Section of Hip-Joint and its relations.
(One-fifth.)

1, anterior crural nerve in substance of iliacus internus; 2, external iliac artery; 3, ilium; 4, obturator internus; 5, adductor magnus; 6, obturator externus; 7 adductor longus; 8, adductor brevis; 9, ilio-psoas; 10, pectineus; 11, gluteus medius; 12, gluteus minimus.

must be either
or its anatomic
clavicle, the acr
neck of the scap
examined in tur
positions, ther
in the event
determined whe
level in the b
scapulo-humeral




Fig 25.—Section thro
the arm being r

1, tendon of supra-spi
coul. process; 5, lo
7, subscapularis; 8,

landmarks
construction of th
in the per
should

the
the
the

more than to
taken with the
the pelvis strai
which lies
inferior aspect
the surgeon in
as the knife
can be taken pass

the thickest and strongest
that anterior portion
the acromioclavicular band, or the
of Bevier, of which the
to the anterior inferior
and the fork to the root
of the inter-trochanteric line. It
has been shown by Bevier that this thickened por
tion of the capsule is the chief agent in producing the
varieties of luxation. When
a luxation is dislocated, it is almost always at
the level of the inter-trochanteric line. In some instances, tho
the capsule is torn, it has been given way
inwards as regards its obliquity
of the individual. Before
it is almost in a continuous
line with the shaft of the humerus, it is at an
angle directed upwards, inwards,
and at persons it becomes hori

smooth ball
hemispherical
forward, for
has a separate
the shaft of
the portion of
the humerus
the

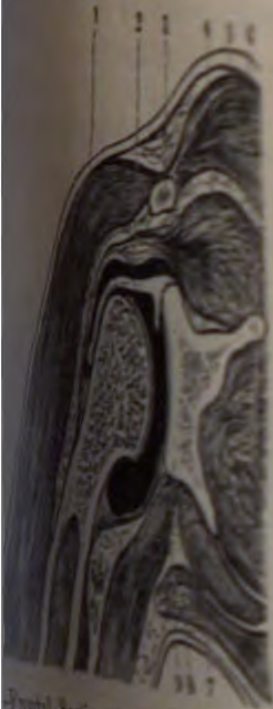
communicating anteriorly with the psoas and iliacus. But it is the length of the neck of the femur as far as the insertion of the ligament is cut off about two-thirds of an inch owing to the fact that the capsular ligament are folded back and become continuous with the synovial membrane which explains why it is that in fractures this membrane is

deepened by the cotyloid ligament below by the transverse acetabular ligament the nutrient vessels pass to

is attached by its apex into a shallow groove below the centre of the globular head of the femur by its base to the margins of the acetabulum, and its function is to assist in rotation and adduction when assisting in the prevention of dislocation forwards and outwards. The capsule is very thin, and is liable to rupture in which case the pus invades the joint which may be opened by the point of the needle through the hip-joint, or in the case of dislocation after resection, unless care be taken to prevent a remarkable fact that after dislocation, or in the case of old dislocation the cavity contracts.

Supply the articulation are the external circumflex, and gluteal; the great sciatic, obturator, and they enter it either by the foramen through the ligamentum teres. *of the femur.*—With regard to the head of the femur in dislocation the muscles of the gluteal region are of no assistance excepting the obturator

head, less major, and less minor; the internal capsule, long head of biceps, external capsule, minor fibres of deltoid, pectoralis major, and nerves, and integuments.



Frontal section of the hip-joint, during the dislocation of the femur, showing the capsule dissected with force. (See text.)
1, 1, triceps; 2, deltoid; 3, capsular; 4, long head of biceps; 5, external capsule; 6, minor fibres of deltoid; 7, pectoralis major; 8, nerves; 9, integuments; 10, femoral head; 11, acetabulum.

URGICAL ANATOMY OF THE ANKLE.

the markings and external form.—The ankle is situated at the base of the foot, and is formed by the articulation of the distal end of the tibia with the proximal end of the talus. The space between the tibia and talus is the ankle-joint, which is a synovial joint, and is bounded by the articular surface of the tibia, the articular surface of the talus, and the articular capsule. The articular capsule is formed by the union of the anterior and posterior ligaments of the ankle, and is lined by the synovial membrane. The articular capsule is situated in the depth of the hollow of the ankle, and is bounded by the articular surface of the tibia, the articular surface of the talus, and the articular capsule. The articular capsule is situated in the depth of the hollow of the ankle, and is bounded by the articular surface of the tibia, the articular surface of the talus, and the articular capsule.

it will measure from half an inch to more than one inch less, these measurements being taken with the patient in the horizontal position, the pelvis straight, and the two femora parallel."

The position of the *trochanter minor*, which lies just below the neck, at the superior and inferior aspect of the femur, is of importance to the surgeon in performing amputation at the articulation, as the knife is liable to be locked in it unless care be taken to pass it well behind.

The capsular ligament is the thickest and strongest in the body, and particularly that anterior portion known variously as the ilio-femoral band, or the inverted **A**-shaped ligament of Bigelow, of which the tail of the **Y** is attached to the anterior inferior spinous process of the ilium, and the fork to the root of the great trochanter and inter-trochanteric line. It has been shown by Bigelow that this thickened portion of the capsule is the chief agent in producing the characters of the *regular* varieties of luxation. When it is ruptured in dislocation, it is almost always at its base, and so strong is it in some instances, that the margins of the cotyloid cavity have given way.

The neck of the femur varies as regards its obliquity to the shaft with the age of the individual. Before puberty it is very oblique, and almost in a continuous axis with the shaft; in the adult male it is at an obtuse angle with it, and directed upwards, inwards, and forwards, whilst in old persons it becomes horizontal.

The head of the femur presents a smooth ball, of very regular form, somewhat more than hemispherical, directed upward, inward, and a little forward, for articulation with the acetabulum. It has a separate point of ossification, becoming united to the shaft at the eighteenth year.

The *synovial membrane* covers all that portion of the neck within the joint, and is reflected on to the internal surface of the capsule, ensheathing the liga-

mentum teres, and often communicating anteriorly with the bursa beneath the psoas and iliacus. But it does not envelope the entire length of the neck of the femur, it does not extend as far as the insertion of the capsule, but is reflected off about two-thirds of an inch above it. This is owing to the fact that the anterior fibres of the capsular ligament are folded back to the surface of the neck, and become continuous with its periosteum—a fact which explains why it is that in certain intra-capsular fractures this membrane is preserved.

The cotyloid cavity is deepened by the cotyloid ligament, rendered continuous below by the transverse ligament, beneath which the nutrient vessels pass to the joint.

The *ligamentum teres* is attached by its apex into a fossa just behind and below the centre of the globular head of the bone, and by its base to the margins of the notch at the bottom of the acetabulum, and its office is to check external rotation and adduction when the thigh is flexed, thus assisting in the prevention of dislocation of the head forwards and outwards. The bottom of the cotyloid cavity is very thin, and is liable to perforation in caries, in which case the pus invades the pelvic cavity. It may be opened by the point of the knife in amputation through the hip-joint, or in the subsequent gouging after resection, unless care be taken. It is a somewhat remarkable fact that after the operation of disarticulation, or in the case of old unreduced dislocation, the cavity contracts.

The *vessels which supply the articulation* are the obturator, ischiatic, internal circumflex, and gluteal; and the *nerves* are from the great sciatic, obturator, and accessory obturator, and they enter it either by means of the notch, or through the ligamentum teres.

Dislocation of the head of the femur.—With regard to the displacements of the head of the femur in dislocation, none of the muscles of the gluteal region probably exert any influence excepting the obturator

internus, the muscular substance of which is so mixed with tendinous structure as to give it great strength; and when in a state of contraction, it may be regarded as an accessory ligament to the joint.

The *regular dislocations* of the head of the thigh bone are—(1) upwards, on to the dorsum ilii; (2) backwards, into the great sciatic arch; (3) downwards, into the obturator foramen, and (4) forwards, on to the pubes. In the *first* form the limb is shortened from one to two and a half inches, and slightly bent, the knee resting on the opposite thigh, and the great toe upon the opposite instep, the head of the femur being felt beneath the glutei. In the *second* form the limb is shortened for about half an inch, and the thigh turned inwards and slightly flexed, the ball of the great toe lying on the base of the metacarpal bone of the opposite foot, and the head of the thigh bone protruding below and behind the tendon of the obturator internus. In the *third* form, the limb is lengthened for about one or two inches, the thigh is flexed, and abducted and advanced in front of the opposite one, the toes pointing downwards and forwards, and the trunk flexed on account of the tension on the psoas and iliacus muscle. In the *fourth* form the limb is shortened, rotated outwards, and the head of the bone felt on the pubes, just below Poupart's ligament. The limb, moreover, is abducted, and the foot points directly outwards.

The action of the muscles is well marked in cases of *fracture*, either of the neck of the femur internal to the capsule, or just below the trochanter, as far as the upper fragment is concerned. In the former case, which is *the* fracture of old age, and is a result of the slightest mishap, there is eversion of the limb, produced, according to some authorities, by the action of the external rotators, but far more likely by the weight of the foot alone, and shortening, which is produced by the action of the glutei, rectus, and hamstrings. In the case of fracture below the trochanters,

a result of direct violence, the upper fragment is pulled forwards by the psoas and iliacus, everted and drawn outwards by the external rotators. There is shortening of the limb beyond the point of fracture, owing to the action of the rectus in front and the hamstrings

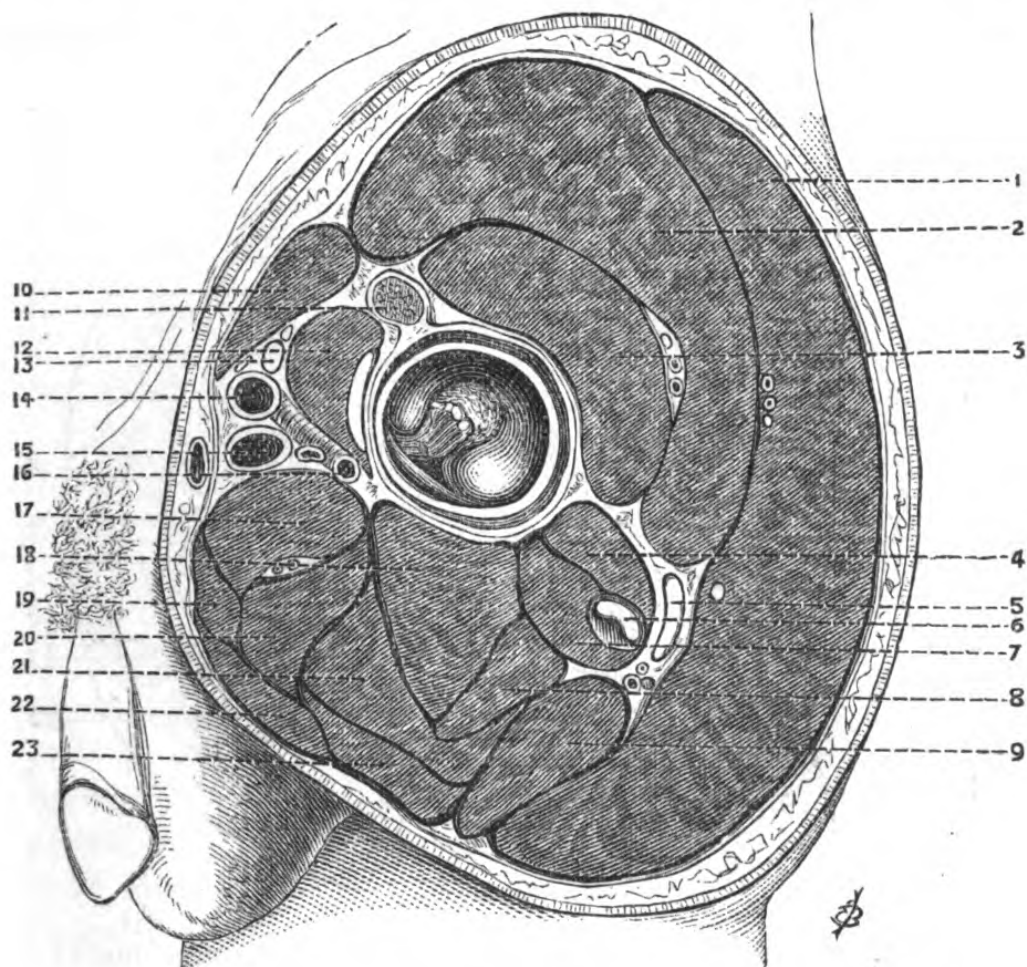


Fig. 60.—Section through the Hip and Gluteal Region (one-third).

1, gluteus maximus; 2, gluteus medius; 3, gluteus minimus; 4, pyriformis; 5, great sciatic nerve and ischiatic vessels; 6, obturator internus; 7, gemelli; 8, biceps; 9, quadratus femoris; 10, sartorius; 11, reflect-d tendon rectus; 12, psoas and iliacus and bursa; 13, anterior crural nerve; 14, common femoral artery; 15, common femoral vein; 16, profunda vessels; 17, gracilis; 18, semi-membranosis; 19, adductor brevis; 20, semi-tendinosus; 21, obturator externus; 22, adductor longus; 23, adductor magnus.

behind, and the upper end is thrown outwards and the lower inwards, and everted by the adductors.

The most important operations in this region are *amputation through the hip-joint*, and *excision of the head of the femur*. In the operation of amputation, supposing the most rapid method—namely, that by anterior and posterior flaps—be performed, the anterior flap can be cut, and the articulation opened by the first thrust of the knife, if a point midway between

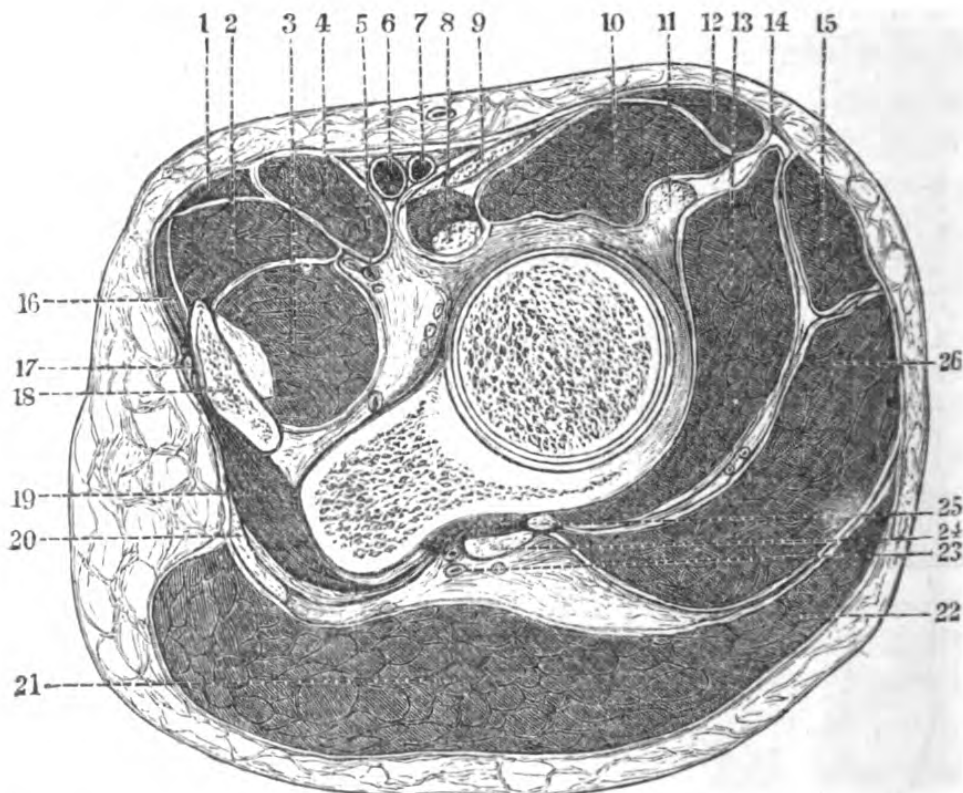


Fig. 61.—Horizontal Section through Hip-Joint (one-fourth).

- 1, adductor longus; 2, adductor brevis; 3, obturator externus; 4, pectineus; 5, obturator vessels; 6, femoral vein; 7, femoral artery; 8, ilio-psoas tendon; 9, anterior crural nerve; 10, iliacus muscles; 11, reflected tendon of rectus; 12, sartorius; 13, gluteus minimus; 14, external cutaneous nerve; 15, tensor fasciæ; 16, gracilis; 17, corpus cavernosum penis; 18, ascending ramus; 19, obturator internus; 20, great sacro-sciatic ligament; 21, gluteus maximus; 22, gluteus maximus; 23, ischiatic artery and veins; 24, great sciatic nerve; 25, tendon of pyriformis; 26, gluteus medius.

the anterior superior spinous process of the ilium and the trochanter major be taken for entering the instrument, and its point be insinuated onwards towards the

capsule, transfixing it, and directed downwards, forwards, and inwards, to a point just in front of the tuberosity of the ischium; the knife is then to cut the anterior flap from the front of the thigh, and an assistant is to help the operator by rotating the limb forcibly *outwards*, so as to bring the globular head of the femur and its attached ligamentum teres towards the surface; the ligament and capsule being divided, the assistant rotates the limb *inwards*, at the same time drawing it towards himself, so that the operator's knife, after cutting through the posterior portion of the capsule, may clear the trochanter major, and fashion the hinder flap.

Structures divided in amputation, through the hip-joint by the antero-posterior flaps.—In the *anterior*, integument, fasciæ, and superficial vessels, sartorius, anterior crural nerve, femoral vessels, rectus, tensor fasciæ, iliacus and psoas, portion of gracilis, adductor longus, adductor brevis, pectineus, and profunda vessels, and part of obturator externus and glutei, with superior gluteal and external circumflex vessels and nerves, capsular ligament, and ligamentum teres. In the *posterior*, part of the gracilis, adductor longus and brevis, and the adductor magnus and pectineus, internal circumflex artery, obturator nerve, quadratus femoris, part of obturator externus, obturator internus and gemelli, the hamstring muscles, sciatic vessels and nerves, part of gluteus minimus and medius, and the gluteus maximus, with its vessels, and the integuments of the buttock.

Excision of the hip-joint.—The joint may be exposed either by a straight, curved, or T-incision, according to circumstances; the straight portion should commence just below the anterior superior spinous process of the ilium, and be carried vertically over the trochanter major, and the following structures divided:—the gluteus medius and minimus, obturator internus and gemelli, obturator externus, pyriformis muscles, and the capsular ligament. The head of the bone is pro-

truded through the wound by bringing the knee of the affected side forcibly across the opposite thigh, with the toes everted. The bone is to be divided below the level of the trochanter major. A more scientific proceeding is to separate the periosteum entire from the trochanter, leaving the attachment of the muscles; by this means they retain in a great measure their proper action, and, moreover, new bone is thrown out.

SURGICAL ANATOMY OF THE MIDDLE FEMORAL REGION.

The limits of this region may be indicated *superiorly* by a line drawn round the thigh at the fold of the nates, and *inferiorly* by one drawn round the lower portion of the thigh at about an inch above the patella; it has the form of a truncated cone, with the base directed upwards.

Surface markings.—*Anteriorly*, the prominences of the oblique crossing of the sartorius, extending from the anterior iliac spine to the inner side of the knee, and of the tensor fasciæ femoris, enclosing a triangular interval, in which is the commencement of the quadriceps extensor, which forms two curved muscular masses, fuller inferiorly, and enclosing a small triangular interval immediately above the patella, corresponding to its tendon of insertion. *Posteriorly*, the surface is convex, and inferiorly is seen the divergence of the muscular masses which form the popliteal space. *Externally*, the surface is convex, and separated from the posterior by a deep furrow, marking the position of the external intermuscular aponeurosis. *Internally* and superiorly is the superior femoral region and Scarpa's space; the middle of this surface is flat, and indicates the position of the crossing of the sartorius; inferiorly is a large oval eminence, due to the vastus internus.

The *course of the femoral artery*, which is seen pulsating in Scarpa's space, is indicated by a line

drawn from the centre of Poupart's ligament to a point just behind the internal condyle of the femur.

Topography.—The *skin* of this region is very thick posteriorly, thinner in front and internally, and freely supplied with sebaceous glands in the upper and inner portion near the groin.

The *subcutaneous cellular tissue* generally contains a good deal of fat, and the superficial veins, nerves, and lymphatics lie in it. The most important superficial vessel is the *internal saphena vein*; its course in the thigh commences just behind the posterior part of the internal condyle, and passing obliquely upwards perforates the fascia lata at the saphenous opening, being there invested by the cribriform fascia, and terminates in the common femoral vein. It is very subject to a varicose condition, and may become enormously dilated.

The course of the *lymphatics* is pretty much that of the vein, and they terminate in those lymphatic ganglia, situate in Scarpa's space, which lie in the axis of the thigh.

The *superficial nerves* are derived from the anterior crural, ilio-inguinal, and crural branch of genito-crural nerves; and posteriorly the integument is supplied by the lesser sciatic.

Beneath the subcutaneous cellular tissue is the *fascia lata*, forming an envelope for the muscles, the arrangement of which in the upper portion of the thigh has been described with those regions. A very strong dense process, into which the tensor fasciæ is inserted, is attached to the head of the fibula and to the outer surface of the knee-joint. This fascia invests the muscles so closely and firmly that its rupture allows of the bulging of the fibres of the subjacent muscles to an extent which would hardly be credited unless seen. Processes of this enveloping fascia form special sheaths for the muscles.

The fascia lata is attached deeply, on the outer side, to the line leading from the trochanter major to the

linea aspera, and extends downwards to the tip of the external condyle, and on the inner side to the line leading from the lesser trochanter to the linea aspera, and downwards to the tip of the internal condyle. Hence it will be seen that the intermuscular septa thus formed divide the thigh into two distinct compartments—an anterior and a posterior.

An intercommunication, however, does take place, owing to the passage of the femoral vessels through the adductor opening, of the perforating branches superiorly, and of the upper articulating branches of the popliteal vessels inferiorly.

The *anterior* of these compartments, beneath the fascia lata, contains externally and above the tensor fasciæ, which is inserted obliquely into its substance; the sartorius, in its own sheath, which passes obliquely from the anterior superior iliac spine, and wraps round the thigh, being throughout its extent from the apex of Scarpa's space, a satellite to the femoral artery and vein; between these muscles lie the rectus femoris, becoming associated in the inferior third with the underlying muscles, the vasti and crureus, which envelope the femur from the great trochanter to the patella. Beneath the crureus is the subcrureus, inserted into the synovial membrane of the knee-joint, which extends upwards beneath the extensors and the periosteum of the femur for about three to four inches. Its office is to draw up the membrane, so that in extreme and sudden extension of the articulation it may not be pinched between the femur and the patella.

The femoral artery in the middle of the thigh—Hunter's canal.—Commencing at the apex of Scarpa's space, the artery describes an oblique course, lying covered over by the sartorius in its sheath, immediately beneath which is a strong fibrous aponeurosis, derived from the vastus internus externally, and the tendons of insertion of the adductor longus and magnus internally. This aponeurosis is very thin in the upper part of the middle femoral region, but becomes

very dense lower down, terminating in a sharp margin, beneath which the internal saphena nerve leaves the vessel. External to the femoral vessels is the vastus internus muscle; and internal to them are the tendons of adductor longus and magnus, and behind them are the conjoined tendons of the vastus internus and adductors; and in the middle third, the fibres of the

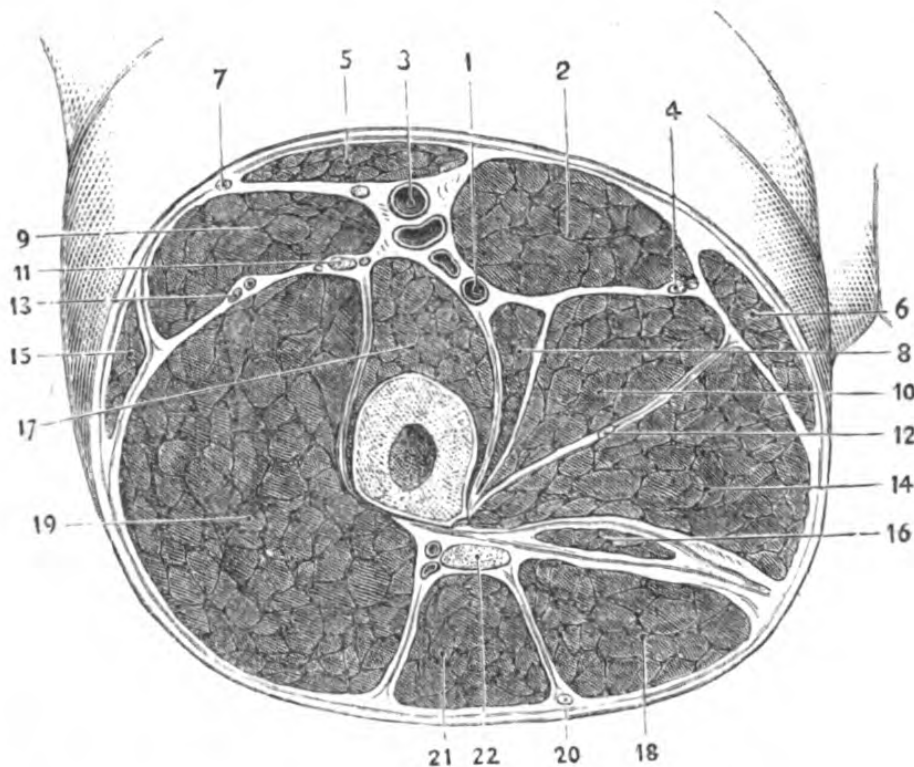


Fig. 62.—Section of the Right Thigh at the apex of Scarpa's Triangle.

1, profunda vessels; 2, adductor longus; 3, femoral vessels; 4, superficial obturator nerve; 5, sartorius; 6, gracilis; 7, external cutaneous nerve; 8, pectineus; 9, rectus femoris; 10, adductor brevis; 11, anterior crural nerve; 12, deep obturator nerve; 13, external circumflex vessels; 14, adductor magnus; 15, tensor fasciæ femoris; 16, semi-membranosus; 17, vastus internus and crureus; 18, semi-tendinosus; 19, vastus externus; 20, small sciatic nerve; 21, biceps femoris; 22, great sciatic nerve.

vastus internus alone, separate the vessels from the femur. In this canal, which is triangular in section, with its apex at the femur, lie the femoral artery and vein posterior to and very intimately united with it;

the long saphena nerve enters it with the vessels, above and externally, and after crossing the artery, leaves the canal at the point above indicated, and is distributed to the skin of the knee and inner side of the leg. The *anastomotica magna* artery is generally given off from the trunk, just before the vessel becomes popliteal, that is, before it passes through the adductor opening.

The superficial femoral is easily *compressed* against the femur, at about the middle of the inner third of the thigh.

Ligature of the femoral artery in Hunter's canal.— This operation is rarely performed now-a-days, unless it be for a wound in this portion of its course, the ligature of the femoral for popliteal aneurism being applied in Scarpa's space.

An incision is to be made in the course of the vessel about three inches in length, through the integument and fascia lata, until the oblique fibres of the sartorius are recognized. Its edge reached, the muscle is to be pulled upwards, when the aponeurotic fibres bridging over the vessels will be seen. These are to be pinched up and divided on a director, when the artery (and perhaps the internal saphena nerve) will be seen with its vein, which is either behind it, or a little to its outer side, and closely united to it by a dense fibrous investment. Occasionally the *anastomotica magna* is very large and superficial, and may be mistaken for the main trunk.

The posterior compartment of the thigh, as formed by the fascia lata, contains—the hamstring muscles, the great sciatic nerve, a great deal of fat and cellular tissue, and the terminations of the perforating branches of the deep femoral vessels; it presents but few points of surgical interest.

If amputation through the middle third were performed by means of antero-posterior flaps (the operation to be preferred), the *anterior* would contain the integuments of the thigh, with the cutaneous nerves

and internal saphena vein, the rectus, sartorius, adductor longus, brevis, and gracilis muscles, obturator nerve, femoral vessels, and branches of anterior crural nerve, a portion of the vastus externus, internus, and adductor magnus muscles. The *posterior*, portion of vastus externus and internus, adductor longus, brevis, and magnus muscles, deep femoral and perforating vessels, the hamstring muscles, great sciatic nerve, lesser sciatic nerve, and integuments of back of thigh. If the amputation be performed near the knee, the muscles are liable to great contraction, since they take their fixed points at the pelvis superiorly. Hence the flaps, which should be lateral, external and internal, must be cut as long as possible. The strong fibrous sheaths of the muscles favour the bagging of pus in amputations through the thigh.

In cases of *wounds* of the thigh, in which either the superficial or deep femoral is implicated, an approximate diagnosis of the site of the escape of blood may be made by examining the posterior tibial artery at the inner ankle. If it pulsates, in all probability the superficial femoral is intact, and the profunda wounded; on the other hand, if the superficial femoral be the seat of injury, the blood, instead of continuing its course along it, and causing pulsation in the posterior tibial, is escaping into the surrounding tissues, and forming a false aneurism. In enlarging the wound to find the bleeding point, it must be remembered that the profunda is external to the superficial femoral, and that the veins of either will be most likely involved.

In *fractures* of the shaft of the femur, the lower fragment is always drawn to the inner side of the upper one, and usually rotated outwards, although in some instances inwards: in the former case, owing to the contraction of the psoas and iliacus, and external rotators; in the latter, to the internal rotators.

SURGICAL ANATOMY OF THE REGION OF THE
KNEE.

This region is limited below by a line drawn round the leg just below the internal tuberosity of the tibia; it will be thus seen that the popliteal space, which partly belongs to the lower third of the thigh, the knee-joint, and the upper portion of the leg, is conveniently associated with the surgical anatomy of the knee.

Surface markings.—If the leg be *extended* on the thigh, from above downwards, in front is the tendon of the quadriceps extensor, in which lies just under the skin the patella, from the lower border of which descends the ligamentum patellæ passing to its insertion in the tubercle of the tibia; on either side of the quadriceps extensor tendon is a deep furrow, between it and the vasti muscles. In cases of synovitis, this furrow is obliterated owing to the collection of fluid causing the synovial membrane to bulge beneath the tendon. If the leg be *flexed*, the condyles of the femur, and the interspace between them, are very evident, and the patella fills up the interval between the femur and the tibia, the tuberosities of which are readily seen. In front of the patella and ligamentum patellæ the integument is slightly raised at a spot corresponding with the bursa patellæ.

Posteriorly, during complete extension the surface of the popliteal space is convex, and the position of the muscles which bound it, although evident, is not so pronounced as when flexion commences; the most salient tendon is that of the semi-tendinosus. The position of the external and internal popliteal nerves lying in the middle of the space is easily seen during *extension*, as, being put on the stretch, they lie immediately beneath the integument, and resemble tendons. *Externally*, the knee presents a depression,

formed by the obliquity of the axes of the femur and tibia, the deepest part of which corresponds with the position of the outer interarticular fibro-cartilage. Above this is the external condyle of the femur, below the external tuberosity of the tibia, whilst posterior to it is the head of the fibula and tendon of biceps; just behind the tendon of the biceps, and below the head of the fibula, can be felt the external popliteal nerve. *Internally* can be felt the internal condyle and internal tuberosity of the tibia, separated by the position of the interarticular fibro-cartilage. The internal saphena vein is seen beneath the integument just behind the inner condyle.

The skin of the region is very thick and dense, and the subcutaneous cellular tissue contains the internal saphena vein and nerve; on the inner side and in front of the patellæ, the bursa patellæ, effusion into which constitutes the affection known as "*housemaid's knee*." In the early stage, inflammation of this bursa is to be distinguished from *synovitis* by the fact of the patella being hidden by the distended sac, whilst the cavities on either side of it remain; the fibrous tissue, however, along the edge of the patella being thin, pus may find its way into the synovial cavity. The aponeurosis is a continuation of the fascia lata, and is attached firmly to the tubercle of the tibia and its tuberosities, to the head of the fibula, afterwards blending with the fascia lata of the leg. Beneath this aponeurosis lie the muscles, which have the following relations:—

Internally are the sartorius, gracilis, and semitendinosus, the tendons of which muscles strengthen the aponeurosis by their fibrous expansions, and are separated from the tibia by a large bursa, and the semimembranosus; *externally*, the tendon of the biceps; *anteriorly*, are the tendon of the quadriceps extensor and the ligamentum patellæ, between which and the tibia is a bursa (*bursa of Cloquet*). The articular branches of the popliteal, anterior tibial recurrent, and anastomotica magna ramify on the capsule.

The popliteal space forms the posterior aspect of the knee.

Topography.—The skin is thin, and has beneath it a considerable amount of fat. It contains a number of lymphatic glands which are liable to suppuration, or to enlargement after injuries to the foot or leg; they are divided into two series—a superficial, which accompany the saphena veins, and a deeper which lie with the popliteal vessels; suppuration in these glands has been mistaken for aneurism.

The external saphena vein lies in this tissue before it perforates the popliteal aponeurosis to join the popliteal vein; here also are some branches of the small sciatic nerve. The popliteal aponeurosis is continuous with the fascia lata above and fascia of leg below, is attached to the bony prominences and ligaments, and forms sheaths for the muscles and vessels of the space; strong transverse bands stretch across the space, and by connecting the tendons of the ham-strings, the fascia is rendered very tense. This fascia, from its strength and power of resistance, complicates the diagnosis of tumours in the space.

The boundaries of the popliteal space are, *externally*, the biceps above, the external head of gastrocnemius and origin of plantaris below. *Internally*, the tendons of the semi-tendinosus, semi-membranosus, gracilis, and sartorius above, and the inner head of the gastrocnemius below.

These muscles are very subject to contraction after strumous disease of the knee-joint, and to cause subsequent dislocation of the leg upon the thigh, in cases where the disease has not been combated by treatment. Connected with the tendons of these muscles are bursal sacs, which are of surgical importance, as if enlarged or inflamed they may offer some difficulties in diagnosis. Thus, one exists between the inner head of the gastrocnemius and the condyle of the femur, and often communicates with the joint, another exists between the tendon of the semi-membranosus and the

tibia; the bursa beneath the outer head of the gastrocnemius is generally a prolongation of the synovial membrane of the joint, and between the popliteal tendon and the posterior and external lateral ligaments there often are found separate bursæ.

The muscles above mentioned enclose a lozenge-shaped space, containing a large quantity of fat and cellular tissue, in which lie the popliteal vessels, nerves, and some lymphatics; as this fat and cellular tissue is continuous with that surrounding the muscles of the back of the thigh and calf, any collections of pus in the space are liable to extend up the limb or downwards amongst the muscles of the back of the leg. Most superficial in the space, on the outer side, is the external popliteal nerve, which lies on the inner margin of the biceps tendon, and must be carefully avoided in tenotomy; the external saphena vein lies to its inner side, after having perforated the popliteal aponeurosis. More internal still is the internal popliteal nerve, which is the continuation directly downwards of the sciatic nerve, in the inferior portion of the space; this nerve gives off a leash of branches which supply the muscles of the calf, and a filament, the *communicans poplitei*, which joins a corresponding one from the external popliteal, the *communicans peronei*, forming a loop which generally lies in the sulcus, between the two heads of the gastrocnemius (*external saphena*). The sheath of the popliteal vessels is very dense, and encloses the *popliteal artery and vein*, which latter lies internal to the internal popliteal nerve, and superficial to the artery.

The popliteal artery.—The course of this vessel in the space is indicated by a line which, commencing at the centre of Poupart's ligament, and wrapping round the thigh, would fall immediately between the two condyles of the femur behind; commencing at the opening in the adductor magnus, it extends to the lower border of the popliteus muscle; it lies close to the surface of the bone, and gives off its articular branches nearly at

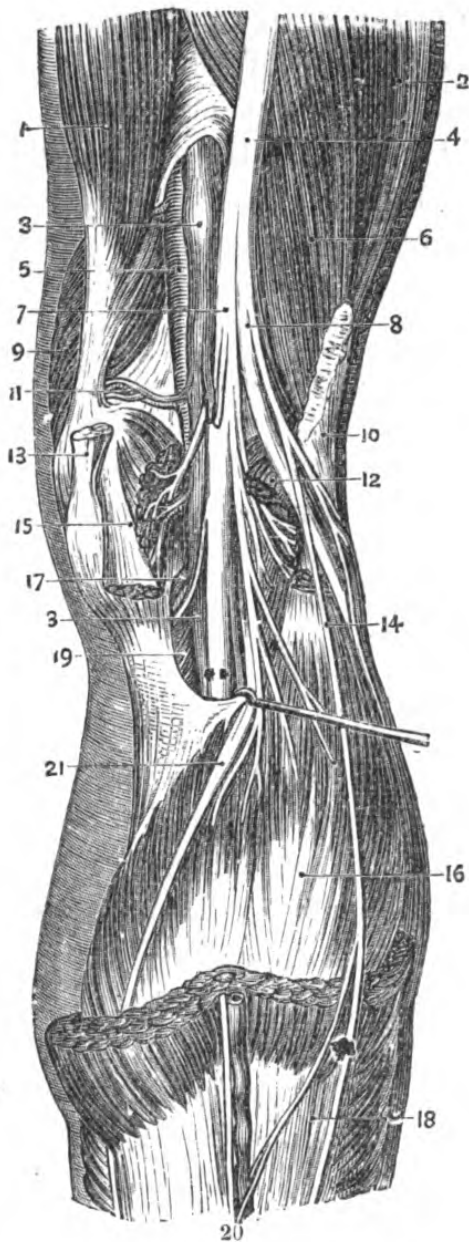


Fig. 63.—Deep View of the Popliteal Space.

- 1, adductor magnus; 2, vastus externus; 3, popliteal vein; 4, great sciatic nerve; 5, popliteal artery; 6, short head of biceps; 7, internal popliteal nerve; 8, external popliteal nerve; 9, vastus internus; 10, long head of biceps (cut); 11, superior internal articular artery; 12, outer head of gastrocnemius; 13, tendon of semi-membranosus; 14, communicans peronei nerve; 15, inner head of gastrocnemius; 16, soleus; 17, inferior internal articular artery; 18, gastrocnemius. 19, popliteus; 20, external saphenous vein and nerve; 21, tendon of plantaris.

right angles to its course. Between the artery and the vein is the articular branch of the obturator nerve, which supplies the knee-joint. The artery and vein are in such intimate relation that it would be almost impossible for a punctured wound of the ham which entered the artery not to involve the vein also.

Relations of the popliteal artery.—*In front*, just beneath the tendinous arch in the adductor magnus tendon, is the inner side of the femur; having wound round that bone, it has that portion of it between the bifurcation of the linea aspera in front of it, in the middle of its course the posterior ligament of the articulation, and below, the popliteal fascia. *Behind*, is the popliteal vein, internal popliteal nerve, aponeurosis; *externally*, biceps; *internally*, semi-membranosus.

The branches of the vessel are the muscular,

the superior and inferior external and internal articular, and the azygos, which pierces the posterior ligament. These vessels maintain a very free anastomosis round the joint amongst themselves, the anastomotica magna, anterior tibial recurrent, and muscular branches.

Ligature of the popliteal, for spontaneous aneurism, as a definite operation is never practised in modern surgery, for reasons which will be found discussed in works on aneurism.

The popliteal vein is intimately united with the popliteal artery. It is a matter of considerable importance that, in the peculiarity of its relation with its artery and its appearance and existence, it resembles no other vein in the body. It is very thick, resembling an artery, both in appearance and structure, hence (in the dead body at least) the difficulty so often experienced in applying a ligature.

The *diagnosis of tumours* in the popliteal space may, in most instances, be reduced to anatomical principles, thus: such tumours must be either aneurism (circumscribed or diffused), abscess, enlarged glands, cysts, or growths, &c. In the event of an aneurism, compression of the femoral would empty its sac, and the sound communicated to the ear by a stethoscope would be of a prolonged, blowing nature. Cysts, such as those alluded to as connected with the tendons, even if they have a communicated pulsation from being so closely packed together with the vessel, could be dragged away from it, and then these seeming pulsations would cease, and moreover they are always lateral. In the diagnosis between an abscess and an aneurism the sac of which had suppurated, or between an abscess and ruptured popliteal artery, forming a diffuse aneurism, difficulty might be expected; but here the condition of the pulse below will generally determine the case.

SURGICAL ANATOMY OF THE KNEE-JOINT.

Three bones enter into the articulation of the knee-joint, viz., the femur, the patella, and the tibia. The

structure of the bones entering into the formation of the joint is the same in each instance—cancellated tissue, enclosed in a layer of compact tissue. The articular extremities of the bones are well supplied with blood-vessels; these enter the patella on its anterior, and the femur on its posterior surface.

The articular surface of the patella is divided vertically by a crest into two facets, the rounder of which corresponds with the outer, and the longer and flatter with the inner articular portion of the trochlea.

The lower articular end of the femur is convex in front and concave posteriorly, and the internal condyle is lower than, and a little posterior to, the external, presenting on its inner side the inner tuberosity for the attachment of the internal lateral ligament, and a well-marked tubercle, very plainly felt beneath the integument, for the attachment of the tendon of the adductor magnus. The tuberosity of the outer condyle is less prominent than that of the inner, and gives attachment to the external lateral ligament. The articular surface extends higher on the outer side than on the inner, and is moreover in advance of it and broader. During complete flexion only, the patella occupies the centre of the trochlea, but in extension it overlaps the outer portion of the articular surface, and rises, if the extension be extreme, half its diameter above it.

The femur and the patella are united by the fibrous capsule and by the tendon of the quadriceps extensor. The great power exerted by the action of the rectus on the patella above, and its strong attachment to the tibia by the ligamentum patellæ below, explain how this bone may be fractured transversely by muscular action. The action of the vasti is rather to drag on the patella transversely.

Dislocations of the patella.—This bone is most frequently dislocated *outwards*. The bone lying above and external to the external articular surface of the trochlea, the outward traction of the extensor muscles

favours this form of displacement. Dislocation inwards is very rare. Dislocation with the bone lying vertically either on the outer or the inner condyle is also very rare.*

The articulation between the femur and the tibia.—The inner articular surface of the condyle of the femur is less prominent anteriorly than the external, but is set lower and extends a little further backwards, and is more oblique laterally. These surfaces are separated posteriorly by the intercondyloid notch. The head of the tibia presents two concave articular surfaces, the external of which is the rounder, separated by the spine, in front and behind which are rough depressions to which are attached the crucial ligaments.

The femur and tibia are united by the capsular ligament, posteriorly by the posterior ligament, which is a prolongation upwards of the tendon of the semi-membranosus, an internal and external lateral ligament, two crucial, the anterior or external and the internal or posterior, and the two interarticular semi-lunar fibro-cartilages.

The synovial membrane of the knee-joint ascends upwards beneath the extensor muscles, as a pouch, for about three inches, and is reflected from the articular surfaces of the femur, to the crucial ligaments and articular surface of the tibia, enveloping the semi-lunar cartilages, and at the back of the external forms a pouch between its surface and that portion of the tendon of the popliteus which is within the capsule; it then lines the capsular ligament.

The lower epiphysis of the femur presents an ossified nodule at the ninth month of foetal life, a fact of considerable value medico-legally in determining the age of the child. The entire epiphysis, however, does not unite with the shaft until the twentieth year; the upper epiphysis of the tibia at the twenty-fifth year.

* *Vide* case in practice of author, "British Medical Journal, December, 1872.

Movements of the knee joint.—*Flexion* is performed by the biceps, semi-tendinosus, semi-membranosus, popliteus, and accessorially by the gastrocnemius. *Extension* by the quadriceps extensor, and tensor vaginæ femoris. When the leg is semiflexed, the joint can be internally *rotated* by the sartorius, semi-tendinosus, and gracilis; *externally* by the biceps.

Relations of the knee-joint, externally.—The tendon of the biceps and the strong process of fascia lata into

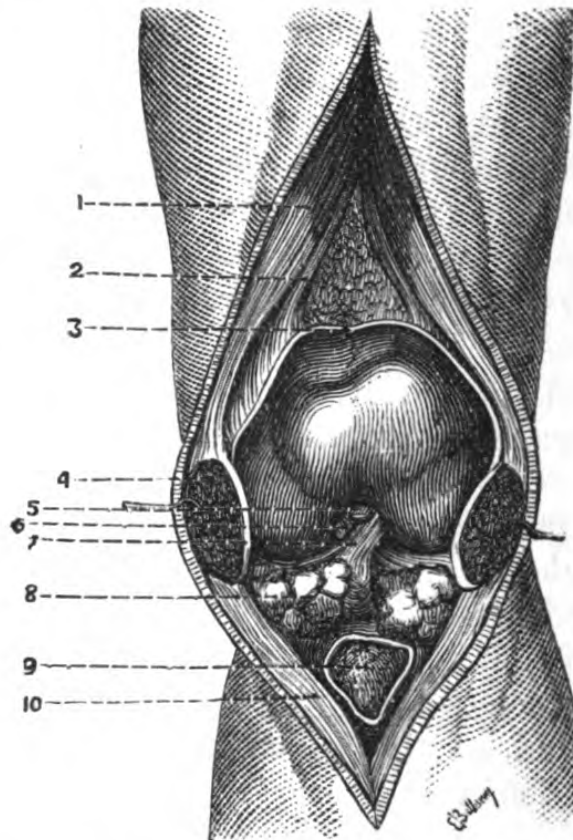


Fig. 64.—Knee-joint Opened Vertically. (One-half.)

1, tendon of quadriceps extensor; 2, sub-crureus; 3, cut edge of synovial membrane; 4, patella divided vertically; 5, ligamentum mucosum; 6, posterior crucial ligament; 7, anterior crucial ligament; 8, adipose tissue; 9, bursa beneath ligamentum patellæ; 10, ligamentum patellæ.

which is inserted the tensor fasciæ; *internally* and a little *posteriorly*, the sartorius, semi-tendinosus, gracilis, and semi-membranosus, all these tendons are enclosed in bursal sheaths; *posteriorly*, the tendon of

the popliteus and the tendon of the muscles forming the popliteal space, with the contents of the space itself.

Fracture of the patella when due to muscular action is always transverse, and the separation of the fragments is caused through the upward traction of the rectus acting on the upper one, whilst the lower is retained in position by the ligamentum patellæ. With a view to treatment, the tension should be relaxed, by extending the leg on the femur, and by slightly flexing the thigh on the pelvis so as to relax the rectus muscle.

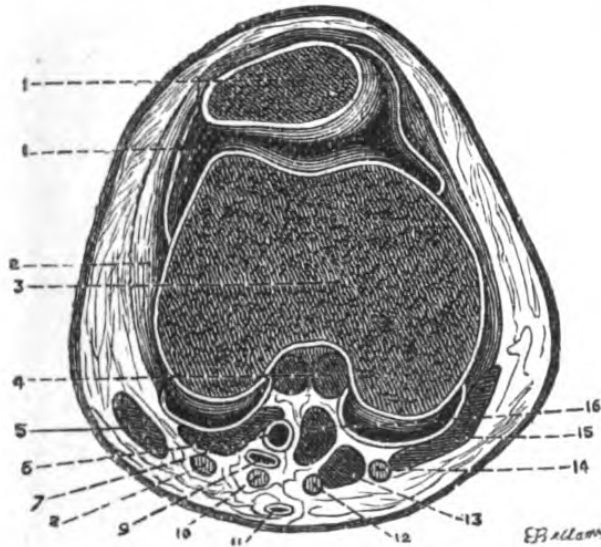


Fig. 65.—Horizontal Section of Knee-joint. (One-half.)

1, patella; 1', synovial membrane; 2, capsule; 3, femur; 4, crucial ligaments; 5, biceps; 6, outer head of gastrocnemius; 7, popliteal artery; 8, external popliteal nerve; 9, popliteal vein; 10, internal popliteal nerve; 11, external saphena vein; 12, semi-tendinosus; 13, semi-membranosus; 14, gracilis; 15, sartorius; 16, inner head of gastrocnemius.

The almost constant failure of osseous union is sometimes owing to the bulging of the synovial membrane between the opposed fragments.

The articulation between the upper extremities of the tibia and fibula is an arthrodial joint, consisting of two opposed articular spaces, united by two ligaments, an anterior and posterior, with a synovial membrane between, occasionally communicating with that of the

knee-joint ; a circumstance explaining the implication of the synovial membrane of the head of the fibula becoming involved in effusions into the knee-joint.

The *operations* which concern the knee-joint are its excision, entire or partial, and amputation through it.

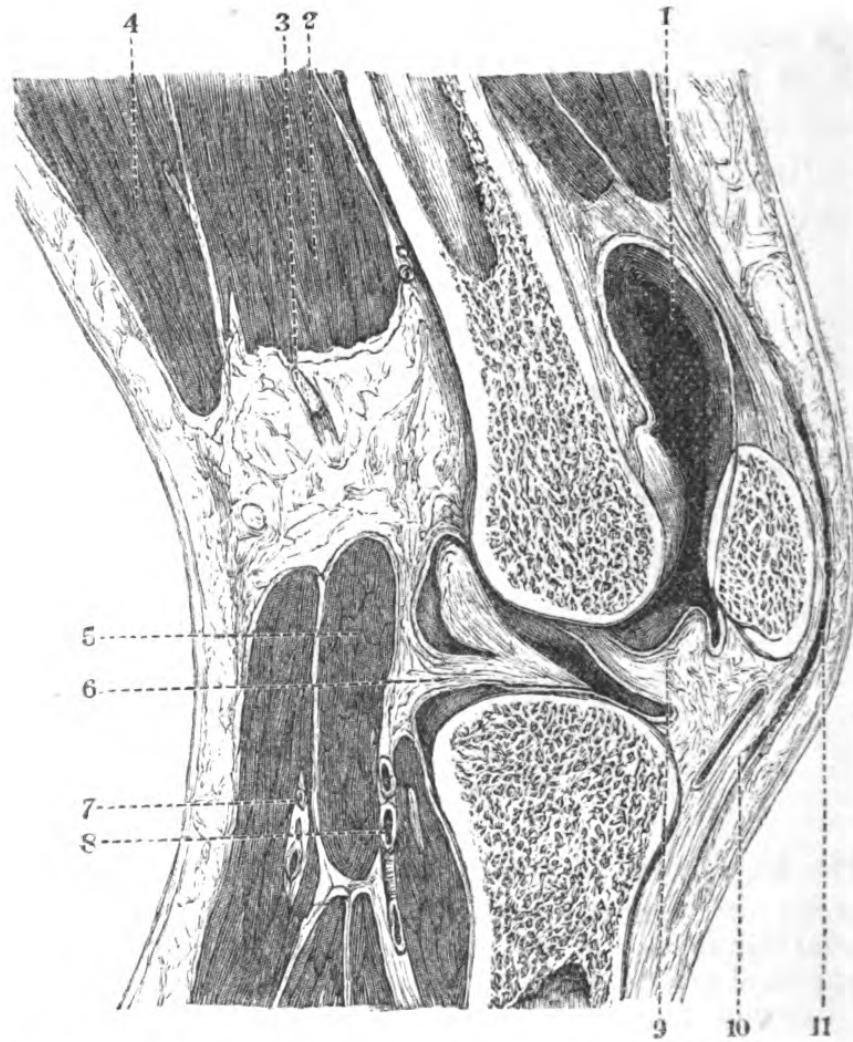


Fig. 66.—Vertical Section of Knee-joint. (One-half.)

1, synovial membrane; 2, short head of biceps; 3, peroneal nerve; 4, long head of biceps; 5, plantaris; 6, external semi-lunar cartilage; 7, sural vessels; 8, popliteal vessels; 9, anterior cruciate ligament; 10, ligamentum patellæ; 11, bursa præpatellaris.

Excision of the knee-joint.—The articular surfaces which require removal may be exposed in several ways, the simplest being by a semilunar incision, extending

from the inner side of the inner condyle to the outer side of the external, the convexity of the incision lying midway between the lower border of the patella and the tubercle of the tibia; the joint is thus opened at once. The articular extremities of the femur and tibia, or patella, are to be removed according to circumstances; but in the instance of performing the operation on children, it is of great importance to avoid removing the entire epiphyses, as there would then be no further growth in the limb.

Structures divided in excision of knee-joint.—Integument and aponeurosis, patellar plexus of nerves, bursa patellæ, ligamentum patellæ, anterior part of capsular ligament, synovial membrane, crucial ligaments, lateral ligaments, articular vessels, and articular extremities of femur and tibia. The popliteal vessels are separated from the opened joint by the posterior ligament and popliteus muscle.

SURGICAL ANATOMY OF THE LEG.

The surgical region of the leg commences just below the knee, and extends to an imaginary line drawn round the lower part of the limb, just above the malleoli.

Surface markings.—Its general form is that of an inverted cone, rendering the reflection of the skin difficult in amputation in the lower third. *Anteriorly* is the crest of the tibia, internal to which is the flat plane surface of the shaft of the bone, which being subcutaneous throughout permits of ready examination, and external to it is the mass of the tibialis anticus, and extensors of the toes. *Externally* are the peronei, separated by a well-marked groove corresponding to the interspace between them and the external edge of the soleus. *Posteriorly* is the swell of the calf, due to the gastrocnemius and soleus, the division between the two heads of the former being marked by a furrow

continuous with the lower portion of the popliteal space. As the muscular fibres cease, the tendo-Achillis becomes more evident.

The leg can be readily divided into two regions, an anterior and a posterior, limited by the inner border of the tibia internally and the outer border of the fibula externally.

Anterior region.—The skin is freely moveable over the subjacent tissues, and in the subcutaneous cellular tissue and fat lies the internal saphena vein, which crossing the inner malleolus, passes upwards towards the posterior border of the inner condyle of the femur, and is accompanied by the internal saphena nerve. The *aponeurosis* is the continuation downwards of the fascia lata, strengthened superiorly and internally by the expansion of the sartorius tendon, and thickened inferiorly where it forms the annular ligament of the ankle. It is adherent to the anterior surface of the tibia and external border of the fibula, and sends septa between and gives attachment to the anterior muscles of the limb; it is perforated in several places for the passage of the cutaneous nerves. Enclosed in the space between the aponeurosis the tibia, fibula, and interosseous membrane, lie, the tibialis anticus and the extensor communis digitorum, united superiorly by an intermuscular septum; lower down they separate, and enclose the origin of the extensor proprius pollicis, external to and below which is the peroneus tertius. The space between these muscles and the interosseous membrane is occupied by the anterior tibial vessels and nerve; the nerve, pursuing the same course as the artery, lies at first external to, then upon, and then again outside the vessels.

External region.—The aponeurosis forms an investment for the peronei muscles; the compartment corresponding to the external surface of the fibula. To the upper and middle thirds of this surface the peroneus longus is attached; the upper fibres are pierced by the external popliteal nerve which at this

point divides into anterior tibial and musculo-cutaneous; the latter perforating the fascia about the middle third of the leg. Arising from the middle third of the fibula the peroneus brevis is enclosed in the same compartment.

The anterior tibial artery.—The course of this vessel

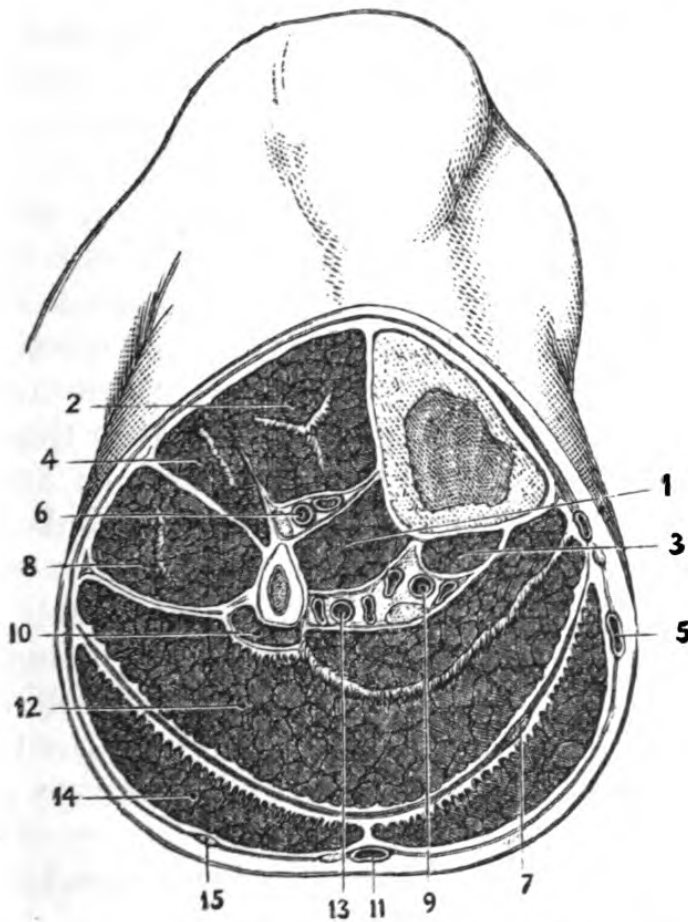


Fig. 67.—Section of the Right Leg in the Upper Third.

- 1, tibialis posticus; 2, tibialis anticus; 3, flexor longus digitorum; 4, extensor longus digitorum; 5, internal saphenous vein; 6, anterior tibial vessels and nerve; 7, tendon of plantaris; 8, peroneus longus; 9, posterior tibial vessels and nerve; 10, flexor longus pollicis; 11, external saphenous vein and nerve; 12, soleus with fibrous intersection; 13, peroneal vessels; 14, gastrocnemius; 15, communicans peronei nerve.

is indicated by a line drawn from the inner side of the head of the fibula to midway between the malleoli. It enters the region at a point below the popliteus muscle, and passes between the upper portion of the

two heads of origin of the tibialis posticus, and comes off from the popliteal almost at a right angle. Its relations are, *anteriorly*, integument and fasciæ, tibialis anticus (above), extensor longus digitorum and extensor proprius pollicis, and the anterior tibial nerve; *internally*, tibialis anticus, extensor proprius pollicis (which crosses it at the instep); *externally*, the anterior tibial nerve, extensor longus digitorum, and extensor proprius pollicis; *posteriorly*, the interosseous membrane, the tibia, and anterior ligament of ankle-joint.

Ligature of this vessel is rarely required, unless it be for a wound, which would be enlarged, and the bleeding points sought for. To tie it an incision should be made in the upper third, in the interspace between the tibialis anticus and the extensor communis digitorum; the intermuscular septum between them looked for, the muscular fibres detached from it, and pulled on one side, when the vessel, surrounded by venæ comites, and having its nerve to the outer side, will be seen lying on the interosseous membrane.

In the *lower* third an incision should be made along the outer border of the tibialis anticus tendon, when the vessel will be found between it and the tendon of the extensor proprius pollicis, and the nerve generally lying on it.

Posterior region. — Beneath the integument and superficial fascia are the external saphena vein and nerve, and some branches of the musculo-cutaneous and internal saphena nerves. The aponeurotic sheath, enclosing that portion of the leg posteriorly between its attachments to the tibia and fibula, is subdivided by an expansion separating the superficial from the deep flexors, vessels, and nerves. The most posterior contains the gastrocnemius and soleus, uniting to form the tendo-Achillis, and the plantaris, with a good deal of fat and bursal tissue. The second, anterior to the former, contains the flexor longus digitorum internally, the flexor longus pollicis externally, and tibialis pos-

ticus muscles between them, closely united by intermuscular septa. The posterior tibial vessels on the tibial side, having the posterior tibial nerve external to them, and the peroneal vessels on the fibula, lying at first beneath the intermuscular aponeuroses, next between the flexor longus pollicis and tibialis posticus, and lower down the limb, between the tibialis posticus and the fibula.

The posterior tibial artery would rarely require ligature in its upper third, unless for injury, in which case the wound should be enlarged, and the bleeding point secured. If the vessel be divided by a punctured wound from the front of the leg, or in the case of traumatic aneurism of the vessel, low down, it is necessary to place a ligature upon it in this situation.

Ligature of the posterior tibial artery in the upper third.—This vessel is reached most scientifically by an incision made along the posterior border of the subcutaneous surface of the tibia, about four inches in length, dividing the integument and aponeurosis, taking care to avoid the internal saphena vein and nerve. The inner border of the gastrocnemius is to be drawn aside; when the tibial head of the soleus is reached, its fibres are to be divided, until the intermuscular septum (the position of which is variable) is come upon. This is next to be cut through, and the fibres of this muscle divided until freedom of access is obtained. The cut edges of the soleus are to be separated, the smooth intermuscular aponeurosis which separates the superficial from the deep flexors is to be divided on a director, and the posterior tibial nerve drawn on one side; the posterior tibial artery, surrounded by venæ comites, is seen lying on the flexor longus digitorum.*

The nutritious artery is a branch of considerable importance. Directed upwards towards the knee, it enters the shaft of the tibia in a deep canal in the posterior aspect, about four fingers' breadth from the

knee, and may give rise to troublesome hæmorrhage in amputation of the leg at this part.

The peroneal artery, generally regarded as a branch of the posterior tibial, is very often of larger size. It is very deep, and lying along the fibular surface of the leg, has the following relations:—*In front*, the tibialis posticus and flexor longus pollicis; *externally*, the fibula; and *behind*, the soleus, deep aponeurosis, and flexor longus pollicis. This vessel is occasionally wounded in compound comminuted fractures of the fibula.

In fractures of the tibia, which take place *obliquely* from above, downwards, and forwards, the muscles of the calf cause the lower fragments to be drawn upwards and backwards, and frequently the upper one to protrude through the integument. With a view of bringing the surfaces into apposition, the knee should be bent to relax the opposing muscles, and extension made from the knee and ankle (*vide* "Ankle-Joint"). Occasionally, the **V** or screw fracture is met with—the result of a wrench.

Fracture of the lower end of the fibula is usually associated with fracture of the inner malleolus (Pott's fracture), or rupture of the internal lateral ligament of the ankle-joint, causing dislocation of the foot outwards. The eversion of the foot is due to the action of the peroneus longus, whilst the heel is drawn upwards by the gastrocnemius and soleus. The reduction is effected by flexing the leg at right angles with the thigh, and making extension from the knee and ankle.

The relation of the tibia and fibula to each other must be borne in mind in performing amputation through the leg. The fibula lies on a plane posterior to the tibia, and its external border, with about half of its external surface, is situated behind the interosseous ligament; hence, unless care be taken, the knife may be easily entered between the bones, instead of taking the necessary oblique course skirting their posterior surfaces.

Structures divided in the double flap amputation through the calf.—In the *anterior* flap: the integument, cutaneous nerves, aponeurosis, tibialis anticus, extensor communis digitorum, and extensor proprius pollicis, peroneus longus and brevis, musculo-cutaneous nerve, anterior tibial vessels and nerve. In the *posterior*, the flexor longus digitorum, flexor longus pollicis and tibialis posticus, posterior tibial vessels and nerve, peroneal vessels, intermuscular aponeurosis, soleus and plantaris, gastrocnemius, external saphena nerve and vein, internal saphena vein and nerve, aponeurosis and integuments.

SURGICAL ANATOMY OF THE TIBIO-TARSAL REGION.

Ankle or malleolar region.—It has been thought more convenient to postpone the description of the several articulations entering into the conformation of the foot and ankle until all those soft structures which enclose them have been explained; as all surgical reference to the skeleton must necessarily be made from the surface, it is of importance that all the intermediate parts be demonstrated from without inwards, and in the order they would be met with in an operation.

Surface markings.—This region includes the ankle-joint, and the structures immediately surrounding it, and offers for examination two surfaces, an anterior and a posterior.

Anterior surface.—The two malleoli, of which the internal is the shorter and broader, and the external set more backwards and longer, enclose a space through which pass the extensors of the foot and toes, which are rendered evident by their several movements. Beneath the integument and superficial fascia lie internally, just in front of the malleolus, the internal saphena vein, accompanied by its nerve; more externally the musculo-cutaneous nerve; whilst passing from behind the outer malleolus is the external saphena nerve. The aponeurosis is a strengthened continuation of that of the

leg, attached intimately to the malleoli, consisting of a superior fasciculus, which binds down the subjacent tendons, just in front of the extremities of the tibia and fibula, and an inferior, which retains them in connexion with the tarsus. It forms two distinct septa, commencing internally—1, for the tendon of the tibialis anticus; 2, for the tendon of the extensor longus digitorum, peroneus tertius, and extensor proprius pollicis, beneath which is the anterior tibial vessels and nerve. These sheaths are lined with separate synovial membranes. The hollows immediately in front of the malleoli correspond with the articulation, and disappear when the synovial membrane is distended.

The posterior surface, or that portion behind the malleoli, is separated by the tendo-Achillis into two hollows.

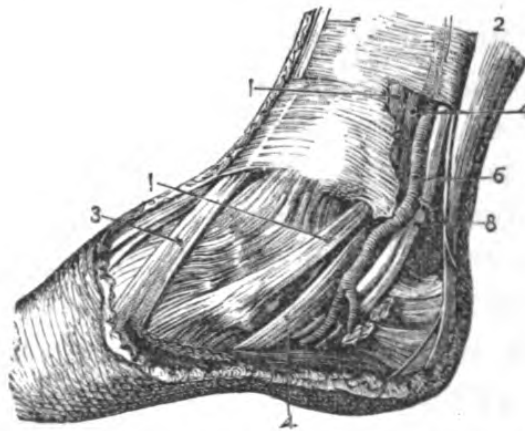


Fig. 68.—Relations of parts behind the Inner Malleolus.

1, 1, tibialis posticus; 2, tendo-Achillis; 3, tibialis anticus; 4, 4, flexor longus digitorum; 6, posterior tibial artery; 8, posterior tibial nerve. The tendon of the flexor longus pollicis is too deeply placed to be shown in this view.

In the *outer*, beneath the integuments, is the external saphena vein and nerve, lying upon the external annular ligament, which is attached to the outer malleolus and outer surface of the os calcis, binding down the peroneus longus and brevis, the former being the superior; they are contained in a common sheath (at first), and have a common synovial membrane. The

hollows immediately behind the malleoli, and separated by the tendo-Achillis, do not become obliterated by distension of the synovial membrane of the ankle-joint.

In the *inner*, the pulsations of the posterior tibial artery are plainly seen or felt, and beneath the integument are the internal saphena vein and nerve, which lie upon the internal annular ligament, which is attached to the inner malleolus and inner surface of the os calcis, and forms with the tibia, os calcis, and astragalus a series of separate canals, containing from before backwards the tendons of the tibialis posticus; the flexor longus digitorum; the posterior tibial vessels and nerve, running in a sheath of their own derived from the contiguous septa; the flexor longus pollicis, the canal of which is formed partly by the astragalus. Each of these canals has a separate synovial membrane. The tendo-Achillis has a separate sheath derived from this aponeurosis.

The posterior tibial artery at the ankle-joint lies between the flexor longus digitorum and the flexor longus pollicis tendons, having venæ comites on each side, and the posterior tibial nerve behind it.

Ligature of the posterior tibial artery at the inner malleolus.—This vessel is easily reached, but the incision must be made carefully, as there is a risk of dividing it in overcoming the resistance of the internal lateral ligament. An incision about two inches and a half in length is to be made through the integument, midway between the inner malleolus and the tuberosity of the os calcis. After the dense aponeurosis is exposed it should be cautiously divided, when the vessel will be seen surrounded by venæ comites, and in order to avoid the nerve, which lies *posteriorly*, the needle should be passed *from the heel towards the ankle*.

The *structures immediately in relation with the ankle-joint* are, *anteriorly*, the tendons of the extensor longus digitorum and peroneus tertius, the extensor proprius pollicis, anterior tibial vessels and nerve, the

tendon of the tibialis anticus; *posteriorly*, tendons of the peroneus longus and brevis, the flexor longus pollicis, the posterior tibial vessels and nerve, the tendons of the flexor longus digitorum and tibialis posticus.

The joint is formed by the articulation of the inferior articular extremities of the tibia and fibula with the astragalus.

The tibio-tarsal articulation.—The extremities of the tibia and fibula are hollowed out into a sort of mortice, concave from before backwards, open in front and behind, and shut in laterally by the malleoli.

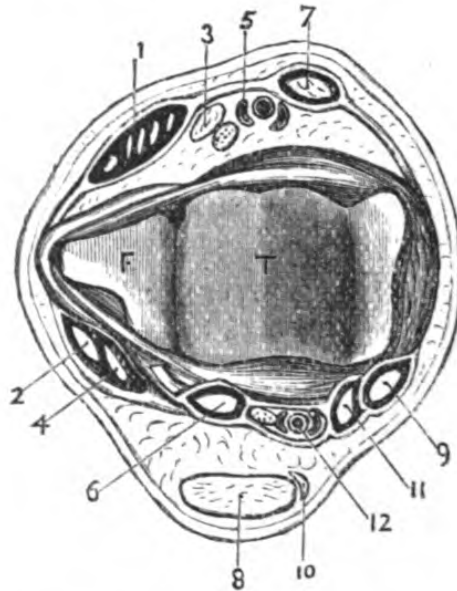


Fig. 69.—Transverse Section of the Right Ankle-joint.

1, extensor longus digitorum and peroneus tertius; 2, peroneus longus; 3, extensor proprius pollicis; 4, peroneus brevis; 5, anterior tibial vessels and nerve; 6, flexor longus pollicis; 7, tibialis anticus; 8, tendo-Achillis; 9, tibialis posticus; 10, plantaris; 11, flexor longus digitorum; 12, posterior tibial vessels and nerve.

The use of the malleoli is to prevent lateral movements, and to restrict the motions of the joint to flexion and extension. The articular surface of the astragalus presents superiorly a surface convex from before backwards for the corresponding articular surface of the tibia; laterally are two articular surfaces corresponding with those of the malleoli, the external

one being the larger. The *ligaments* are an external lateral, consisting of three fasciculi; an internal, or deltoid, radiating from the inner malleolus, to be attached to the scaphoid, os calcis, and astragalus; anteriorly are a few fibres closing in the articulation; posteriorly the joint is shut in by the transverse ligament of the inferior tibio-fibular articulation. The synovial membrane invests the inner surface of the ligaments and articular cartilages, and owing to the

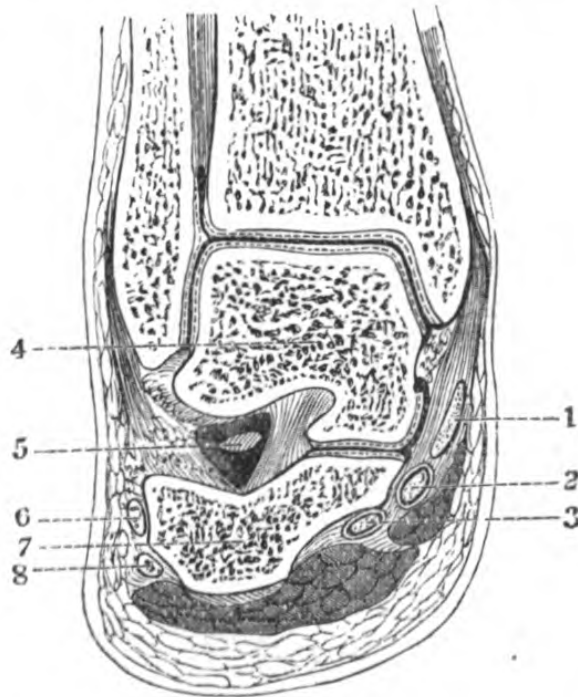


Fig. 70.— Vertical Section of Ankle-joint. (One-half.)

1, tibialis posticus; 2, flexor longus pollicis; 3, flexor longus digitorum; 4, astragalus; 5, astragalo-calcaneum ligament; 6, peroneus brevis; 7, os calcis; 8, peroneus longus.

great laxity of the anterior and posterior ligaments it readily bulges through them, consequently the joint is easily reached from either aspect, and in cases of synovitis the membrane usually protrudes in front between the malleoli and again behind the external malleolus.

Dislocation at the tibio-tarsal articulation—that is to say, dislocation of the entire foot from the bones of the leg—is almost invariably associated with fracture

of one or other malleoli, which can be readily understood from the shape and extent of motion allowed at the joint. It is a result of the foot being twisted in running or walking, and may either be *outwards*, when the lower end of the fibula is broken, the inner malleolus or internal lateral ligament torn; *inwards*, when there is no fracture of the fibula, but the lower end of the tibia broken; *backwards*, when both malleoli are broken, the heel projecting; and *forwards*, when the astragalus is thrown in front of the tibia.

Excision of the ankle-joint.—The seat of disease can be reached by a variety of incisions; but the object to be attained is to save the tendons, in order

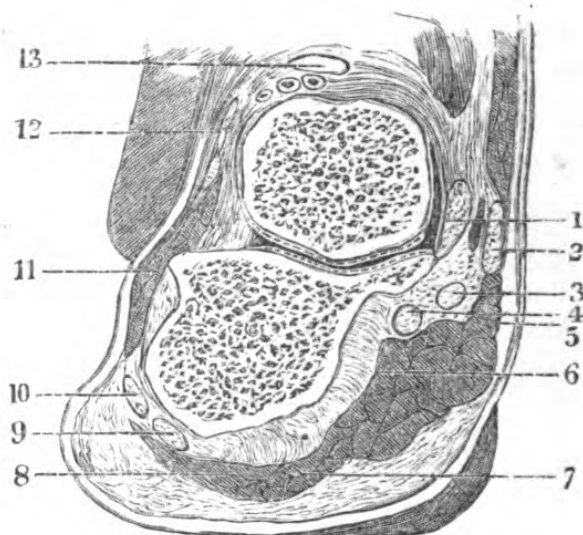


Fig. 71.—Vertical Section through the Anterior Astragalo-calcaneal Articulation. (One-half.)

1, internal lateral ligament; 2, tibialis posticus; 3, flexor carpus pollicis; 4, flexor carpus digitorum; 5, abductor pollicis; 6, flexor accessorius; 7, flexor brevis digitorum; 8, abductor minimus digiti; 9, peroneus longus; 10, peroneus brevis; 11, extensor brevis digitorum; 12, extensor communis digitorum; 13, extensor longus pollicis.

that they may still fulfil their functions as far as possible, for which purpose an accurate knowledge of the parts in contact with the articulation is necessary, and which may be gathered from a study of the accompanying sections.

The articulation of the astragalus with the os calcis is one of great strength, owing to the interosseous ligament which lies in the grooves of these bones; it is ruptured in cases of dislocation of the astragalus from the os calcis. This is by far the most important of the luxations of the tarsal bones, and may occur either forwards and inwards, or forwards and outwards.

Amputation at the ankle-joint.—The landmarks for the guidance of the knife are, in the first place, for the *anterior flap*, the two malleoli, which are to be united by a semilunar incision dissected forwards; and for the *posterior*, one cutting the sole transversely and a little obliquely forwards, and extending between the limits of the preceding incision; the articulation is next opened, the lateral ligaments divided, the posterior part of the capsule cut through, and the os calcis sawn through obliquely from behind forwards and downwards. The anterior flap is dissected off the malleoli, which are next sawn off, and the cut surfaces approximated, and the tendo-Achillis, if necessary, divided. (Pirogoff.) Syme's amputation consists in removing the os calcis, and sawing off the ends of the malleoli. In both these operations care must be taken not to wound the trunk of the posterior tibial artery, and to keep the external and internal plantar vessels as long as possible.

SURGICAL ANATOMY OF THE FOOT.

TARSO-METATARSAL REGION.

The dorsum of the foot.—The chief points to be observed in the surface markings of the dorsum of the foot are those connected with the prominent points of its skeleton. For the performance of the several amputations and disarticulations, certain landmarks are necessary to guide the operator in finding the articulation he desires to open. Thus, a line drawn from the depression on the inner side of the foot,

between the inner cuneiform bone and the great toe, to the posterior edge of the tuberosity of the fifth metatarsal bone, indicates the course of an incision, such as would expose the tarso-metatarsal articulation.

Again, the tubercle of the scaphoid on the inner side, and a point midway between the outer malleolus, and the tuberosity of the fifth metatarsal bone, which is the situation of the articulation between the cuboid and os calcis, indicates a line of incision which would open the medio-tarsal joint.

Topography.—First, the integument, and subcutaneous cellular tissue, which contains the dorsal venous arch, the terminal inosculation of the internal and external saphena, and the musculo-cutaneous nerves, beneath which is the dorsal aponeurosis of the foot, and from within outwards the tendons of the tibialis posticus, tibialis anticus, extensor proprius pollicis, extensor communis digitorum, peroneus tertius, and peroneus brevis, and in a plane beneath them the extensor brevis digitorum; externally, the dorsalis pedis vessels and anterior tibial nerve, the tarsal and metatarsal branches of the anterior tibial artery and external branch of the anterior tibial nerve, which latter lie beneath the lesser extensor muscle. All these structures lie close upon the tarsus and metatarsus, and between the metatarsal bones the dorsal interossei are seen bulging through.

The *dorsalis pedis artery* is the continuation of the anterior tibial, and passes forwards on the tibial side of the foot to the inner interosseous space, where it divides into the dorsalis hallucis and the perforating vessels which enter the sole between the heads of the first dorsal interosseous muscle. It is in *relation* in front with the integument and fascia, and inner tendon of the extensor brevis digitorum; internally with the extensor proprius pollicis; externally with the extensor longus digitorum and anterior tibial nerve; posteriorly with the astragalus, scaphoid, inner cuneiform, and with the ligaments attached to them.

Ligature of dorsalis pedis artery.—The course of this vessel is indicated by a line drawn from the middle of the inter-malleolar space to the first interosseous space. It is superficial, but is bound down by a very dense aponeurosis, which must be divided cautiously to avoid injuring the artery beneath. An incision is to be made over the instep along the outer border of the extensor proprius pollicis, when the vessel will be found lying in a triangular interspace formed by the outer border of the extensor proprius pollicis internally, by the inner tendon of the extensor brevis externally, and by the fleshy fibres of the extensor brevis digitorum, posteriorly. The nerve lies to its outer side.

PLANTAR REGION.

Topography.—Beneath the integument, which is very thick and strong, the first tissue met with is a dense layer of fat, in which are three bursæ, one beneath the os calcis, and two beneath the heads of the first and fifth metatarsal bones. Ramifying in the fat are some cutaneous branches of the cutaneous nerves of the foot, some perforating branches of the plantar vessels, and a great number of lymphatics. The next layer is formed by the plantar fascia, consisting of three portions, of which the central is the strongest, sending down processes which enclose the several muscles, separating the middle from the external and plantar internal groups. This fascia divides opposite the middle of the metatarsus into five processes, each one of which again divides opposite the metatarso-phalangeal joint into two slips, which by their deep attachments form arches for the passage of the flexor tendons to the toes; and the interspaces allow of the digital vessels and nerves, the tendons of the lumbricales and interossei becoming superficial. The mutual relations of the structures forming the sole of the foot can be conveniently referred to the partitions thus formed by the plantar fascia.

In the inner compartment, internally and posteriorly, lie the fleshy fibres of the abductor pollicis, the tendons of the flexor longus digitorum and flexor longus pollicis, the latter crossing and becoming internal anteriorly, the posterior tibial vessels and nerves becoming plantar, flexor brevis pollicis, the vessels and nerves of the great toe and inner side of the foot.

In the outer compartment lie the abductor minimi digiti and the flexor brevis minimi digiti.

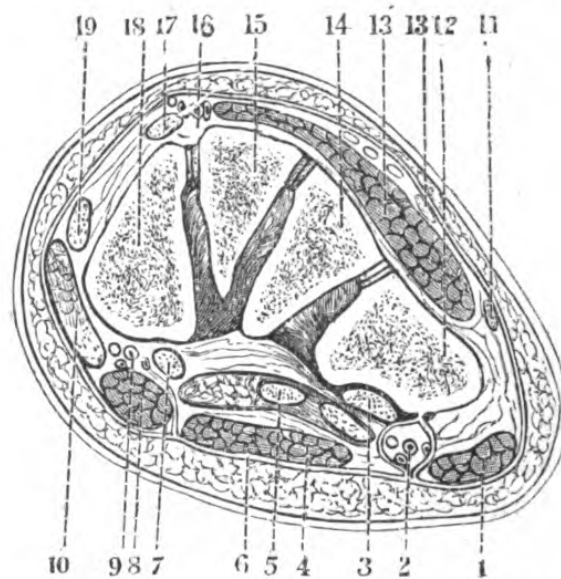


Fig. 72.—Vertical Section through the Cubiform and Cuboid Bones. (One-half.)

1, abductor minimi digiti; 2, external plantar vessels and nerve; 3, tendon of peroneus longus; 4, flexor brevis digitorum; 5, flexor longus digitorum; 6, plantar fascia; 7, flexor longus pollicis; 8, 10, abductor pollicis; 9, internal plantar vessels and nerve; 11, peroneus tertius; 12, cuboid; 13, dorsal aponeurosis; 14, external cuneiform; 15, middle cuneiform; 16, dorsalis pedis vessels and nerve; 17, exterior longus pollicis; 18, internal cuneiform; 19, tibialis anticus.

The middle compartment, which is by far the most important from its contents and size, is bounded by the plantar fascia below, laterally by the septa between the outer and inner compartments, and its roof is formed by the under surfaces of the bones forming the arch of the foot; it communicates posteriorly with the region of the leg by means of the sheaths for the tendons and vessels passing beneath the inner

malleolus. Beneath the middle fasciculus of the plantar fascia, lie the flexor brevis digitorum, the plantar vessels and nerves, the flexor accessorius, the tendons of the flexor longus digitorum, with which are associated the lumbricales, and flexor longus pollicis internally. Beneath these muscles lie posteriorly the tarsal bones and their ligaments; anteriorly, the adductor pollicis, the heads of the metacarpal bones and the ligaments uniting them, the transversus pedis, the plantar arch and external plantar nerve and their interosseal branches, the bodies of the metacarpal

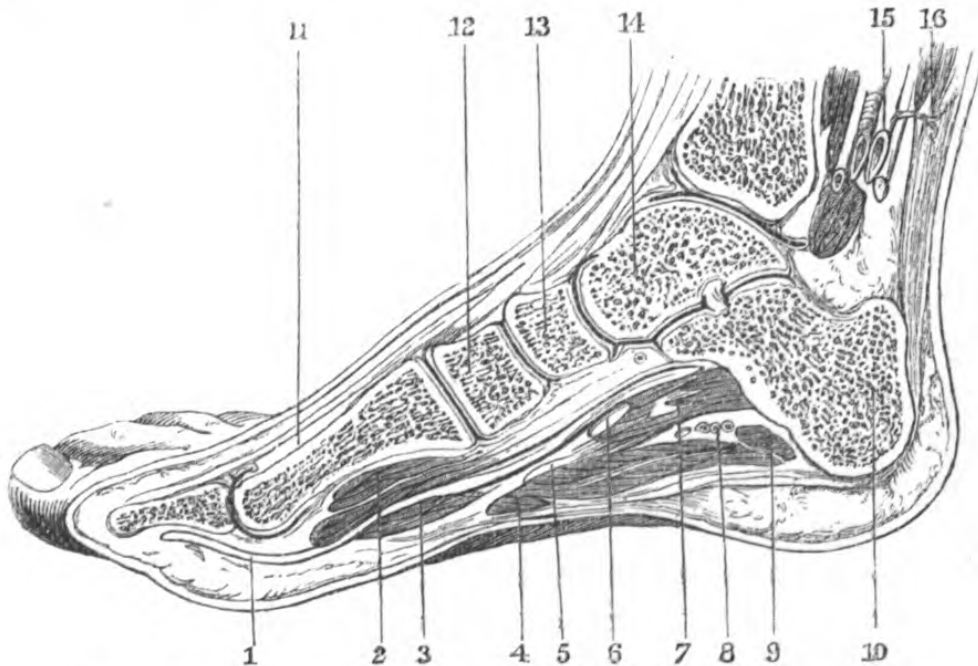


Fig. 73.—Longitudinal Section of Foot. (One-third.)

1, flexor longus pollicis; 2, flexor brevis pollicis; 3, lumbricalis; 4, flexor brevis digitorum; 5, internal plantar nerve; 6, flexor communis; 7, accessorius; 8, external plantar vessels and nerve; 9, adductor minimi digiti; 10, os calcis; 11, extensor proprius pollicis; 12, internal cuneiform; 13, scaphoid; 14, astragalus; 15, posterior tibial vessels and nerve; 16, tendo-Achillis.

bones, between which lie the plantar interossei, and lying deeply in the tarsus the tendon of the peroneus longus.

Club-foot (talipes.)—The various deformities of the foot, occurring at the tibio-tarsal or medio-tarsal arti-

culations, which are within the operative interference known as tenotomy, are—*talipes equinus*, in which the heel is raised so that the individual walks on the ball of the foot, in which case the tendo-Achillis requires division; *talipes varus*, or more precisely *talipes equino-varus*, where the heel is raised, the foot turned inwards for about the anterior two-thirds—this inversion taking place at the astragalo-scaphoid and calcaneo-cuboid articulations, its dorsal aspect outwards, and the inner edge drawn up; the tendons requiring division being—the tendo-Achillis, and the tendons of the tibialis posticus, anticus, and flexor longus digitorum; *talipes valgus*, where the inner ankle is towards the ground and the outer edge of the foot turned up; the tendons to be divided are—the peronei, and the extensor longus digitorum, and the plantar fascia; *talipes calcaneus*, where the patient walks on the heel—a case requiring division of the tendons of the tibialis anticus, extensor communis digitorum, extensor proprius pollicis, and peroneus tertius. There are several intermediate forms; and *talipes equinus* and *varus* are usually associated, on account of the extensor and peronei muscles being supplied by the anterior tibial and musculo-cutaneous nerve. *Talipes calcaneus* and *valgus* are generally associated.

The tibialis posticus tendon can be divided by *tenotomy*, either above or below the ankle. The point selected *above* the ankle is on the posterior margin of the tibia about an inch or so above the malleolus, where it lies in the groove in its own sheath and in contact with the bone; eversion of the foot raises the tendon *below* the ankle, at its insertion into the scaphoid. The point is just above the astragalo-scaphoid articulation, which is immediately behind the first tuberosity met with in passing the finger along the inner side of the foot, starting at the malleolus. The tibialis anticus not being so confined as the preceding can be more readily put on the stretch, as it passes over the lower end of the tibia in the innermost compartment of the

annular ligament. It may be also divided at its insertion into the inner cuneiform bone, the position of which attachment may be ascertained by passing the finger along the inner surface of the foot, when it is just in front of the articulation of the scaphoid with the inner cuneiform.

In performing the *tarso-metatarsal disarticulation*, known as Hey's or Lisfranc's, the line of the joints may be exposed, in the first place, by starting from the outer surface of the foot at a point immediately behind the tuberosity of the fifth metatarsal bone to a

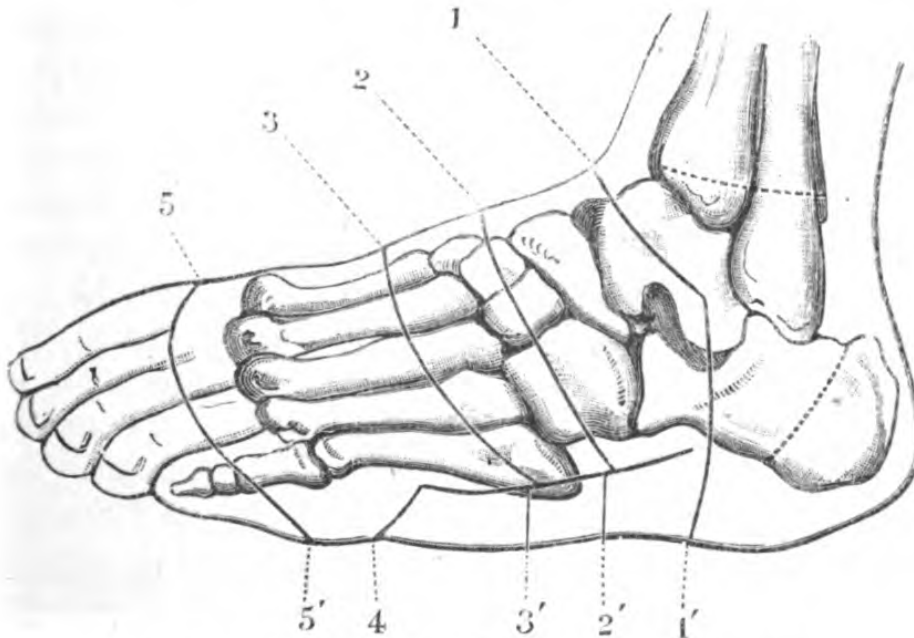


Fig. 74.—Diagram of the Lines of Incision in

1, 1', Pirogoff's amputation; 2, 2', Chopart's; 3, 3', Hey's; 4, limit of posterior flap in the two latter; 5, 5', dorsal flap in amputation of tarsal bones.

point which may be indicated in one of the following ways:—(1) If a transverse line be drawn across the foot from the tuberosity of the fifth metatarsal bone, it falls on the inside of the foot, two-thirds of an inch *behind* the required spot; (2) in following the inner edge of the foot from behind forwards, an inch in front of the malleolus is the projection of the scaphoid; the joint between the great toe and the tarsus is one

inch *in front* of this. The articulation of the first metatarsal bone with the inner cuneiform is oblique from within outwards, and about a quarter of an inch in front of the third. The line of the joint is rendered irregular by the jutting into the tarsus of the second metacarpal bone, which is wedged in between the inner and outer cuneiform bones, its line of articulation lying about half an inch behind the anterior articular surface of the inner cuneiform, and about a quarter of an inch behind the anterior articular surface of the outer cuneiform bone. The joint of

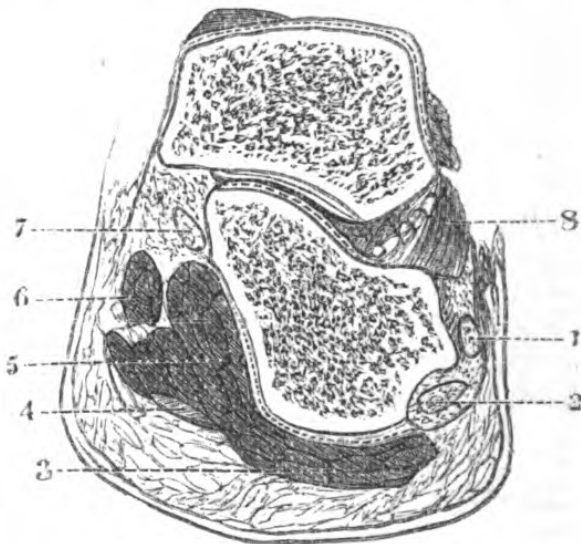


Fig. 75.—Vertical Section through the Posterior Astragalo-calcaneal Articulation. (One-half.)

1, peroneus brevis; 2, peroneus longus; 3, abductor minimi digiti; 4, plantar fascia; 5, flexor accessorius; 6, abductor pollicis; 7, flexor longus digitorum.

the third with the internal cuneiform is almost transverse; that of the fourth is curved; and that of the fifth with the cuboid is doubly oblique. After disarticulation, the posterior flap should extend as far as the web of the toes.

Structures divided in Hey's amputation.—In the anterior flap, the integument beginning from the outer side, the dorsal veins of the foot, the internal and external divisions of the musculo-cutaneous nerve, the internal and external cutaneous nerves, the dorsal

aponeurosis, extensor brevis digitorum, tendon of peroneus brevis, tendon of extensor communis digitorum, dorsalis pedis vessels and accompanying nerve, tendons of extensor proprius pollicis and tibialis anticus, dorsal ligaments, and the articulation.

In the *posterior* flap, plantar ligaments, tendon of peroneus longus, external and internal plantar vessels and nerves, interossei, the flexor brevis, abductor and adductor pollicis, transversus pedis, tendons of long and short flexors of toes, and flexor longus pollicis tendon, digital vessels and nerves, plantar fascia and integument.

Chopart's amputation, or the medio-tarsal, consists of opening the articulation by a semilunar incision, extending between the joint behind the tubercle of the scaphoid internally and a point midway between the external malleolus and the tuberosity of the fifth metatarsal bone; externally, the lower flap is to be brought well up to the web of the toes.

It is important to remember that the direction of the articulating surface is changed in flexion or extension: in flexion the astragalus and calcis are in the same line, in extension the calcis is at least a quarter of an inch in front; the head of the astragalus presents a large globular surface, whilst the anterior articulating surface of the calcis is concave.

The following directions for finding the articulation with readiness are useful. *To find its internal side*, follow the inner edge of the foot with the finger; the first tuberosity met with is the scaphoid; the joint is immediately behind it. For the *external side*, pass the finger along the outer edge of the foot from the external malleolus; the articulation is immediately in front of the first tuberosity met with, which belongs to the os calcis. To complete the line of the articulation extend the foot and abduct it; then, applying the finger on the union of the external with the middle third of the intermalleolar space, the first eminence met with in proceeding forwards is the head of

the astragalus ; immediately in front of this is the articulation.

Structures divided in Chopart's amputation.—Commencing from the inner side, the *anterior flap*, that is, up to the point of disarticulation, will contain integument, saphena vein, and musculo-cutaneous nerve,

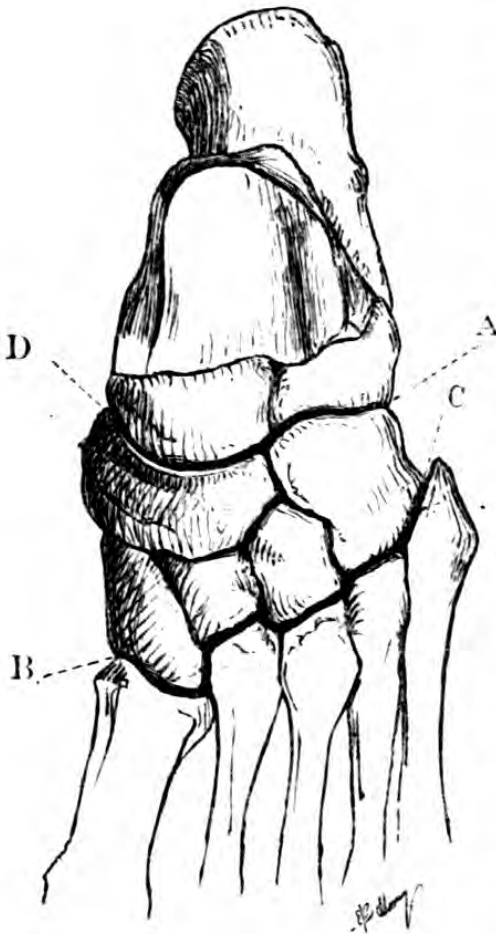


Fig. 76.

A, line of Chopart; B, line of Hey; c, tubercle of fifth metatarsal; D, tubercle of scaphoid.

anterior annular ligament, tendon of tibialis anticus, extensor proprius pollicis, anterior tibial nerve and vessels, tendons of common extensor and peroneus tertius, extensor brevis digitorum, peroneus brevis and anterior ligaments of the articulation ; the *posterior flap* should contain the posterior ligaments of the articulation, the tendon of the tibialis posticus, flexor longus digitorum and flexor longus pollicis, some branches of the internal plantar nerve and vessels, the abductor pollicis, the flexor accessorius, the tendon of the peroneus longus, the abductor minimum digiti, the flexor brevis digito-

rum, the external plantar nerve and vessels, and the integument of the sole.

Synovial membranes of the tarsus and metatarsus.—There are four synovial membranes in the articulations of the tarsus—namely, one for the posterior calcaneo-astragaloid articulation, a second for the anterior calcaneo-astragaloid and astragalo-scaphoid, a third for

the calcaneo-cuboid, and a fourth for the surfaces of the cuneiform with the scaphoid, the cuneiform with each other, the external cuneiform with the cuboid, and the middle and outer cuneiform with the second and third metatarsal bones. Between the internal cuneiform and the base of the metatarsal bone of the great toe there is a single synovial membrane, and there is another common to the anterior surface of the cuboid, and the bases of the fourth and fifth metatarsal bones.

The arteries of the sole of the foot are the internal and external plantar; the internal commences at about the centre of the inner aspect of the os calcis, and courses forwards between the muscles of the inner and middle groups, anastomosing with the malleolar and dorsalis pedis. The external is much larger, and forms the plantar arch. Commencing at the same spot as the internal, it passes obliquely forwards and outwards, lying at first between the os calcis and abductor pollicis, and then between the flexor accessorius and flexor brevis, and forming a curve, the convexity of which is forwards, it joins, at the interval between the first and second metatarsal bones, the perforating branch of the dorsalis pedis, thus completing the plantar arch. Its branches are muscular, perforating, which inosculate with those of the metatarsal artery, and digital, which supply the three outer toes and half the second.

The nerves are the internal and external plantar branches of the posterior tibial, of which the internal is considerably the larger.

Toes.—The description already given of the fingers will in almost every particular suffice for that of the toes.

I N D E X.



- A**BDOMEN, regions of, 176
 ,, tapping the, 180
Abdominal parietes, 179
 ,, ring, external, 181, 183
 ,, ,, internal, 186
 ,, viscera, relation of, to surface, 176
Abscess, abdominal parietes, of, 179
 ,, antrum, in, 42
 ,, axillary, 136
 ,, cervical, 67, 68
 ,, face, in, 18
 ,, groin, in, 191
 ,, iliac, 206
 ,, ischio-rectal, 221
 ,, lumbar, 204
 ,, mammary, 113
 ,, mastoid cells, in, 7
 ,, mediastinal, 117
 ,, nasal, 36
 ,, orbital, 28
 ,, palmar, 170
 ,, parotid, 51
 ,, pelvic, 206, 207
 ,, pericæcal, 196
 ,, perineal, 216, 221
 ,, perinephritic, 196, 199
 ,, popliteal, 271
 ,, prævertebral, 68
 ,, prostatic, 236
 ,, psoas, 207
 ,, retro-pharyngeal, 68
 ,, sacro-iliac, 208
 ,, thecal, 173
 ,, tongue, of, 56

- Abscess, tonsillar, 48
 " urinary, 236
 " vulval, 232
 Accelerator urinæ muscle, 217
 Acetabulum, 254, 255
 Acromion, 124
 Action of muscles in fracture of clavicle, 122
 " " " of femur, 256, 257, 265
 " " " of humerus, head of, 146
 " " " " lower extremity of, 146
 " " " " shaft of, 146
 " " " of patella, 275
 " " " of radius, 159, 164
 " " " of ulna, 159
 " " " of carpus, 161
 " " " dislocation of femur, 256
 " " " of humerus, 127
 " " " of patella, 272
 " " " of tarsus, 287
 Ampulla, rectal, 239
 Amputation (*vide* Arm, amput. of, etc.)
 Amussat's operation, 200, 203
 Anal region, 219
 Anastomotica magna, brachial artery of, 146
 " " " femoral artery of, 264
 Aneurism (*vide* the several arteries)
 Ankle-joint, amputation at, 289
 " excision of, 288
 Antrum, 42
 Anus, artificial, 194
 " fissure of, 219
 " fistula of, 221
 Aorta, abdominal, 196, 202
 Aortic orifice, 108
 Aponeurosis (*vide* Fasciæ)
 Appendages of eye, 20, 21, 23, 29
 Arch of aorta, 108
 " crural, 183
 " palmar, 167, 170, 171
 " plantar, 293
 Areola, 112
 Arm (fore) region of, 154
 " " amputation of, 155
 " " (upper) amputation of, 144
 " " dislocations of, 154
 " " fractures of, 159
 Arteries (*vide* Axillary, etc.)
 Astragalus, 286
 Auditory meatus, external, 13

Auditory meatus. inspection of, 13
 Auriculo-ventricular opening, right, 107
 " " left, 108
 Auscultation of chest, 105
 Axilla, region of, 131
 Axillary artery, 132, 137
 " " ligature of, 139

BASE of skull, fractures of, 12, 13
 Bend of elbow, 148, 149
 Bladder, female, 236
 " male, 234
 " of child, 225
 Brachial region, 141
 " artery, 144
 " " ligature of, above bend of elbow, 145
 " " " at " " 150
 Bronchi, 79, 119
 Bulb of urethra, 228, 230
 " " artery to, 225
 Bursa beneath deltoid, 124
 " " latissimus, 125
 " " scapula, 125
 " " gluteus maximus, 247
 " patellæ, 267
 " popliteal, 268

CALLISEN'S operation, 203
 Canal, crural, 192
 " inguinal, 186
 " nasal, 24, 25
 " obturator, 249
 Canaliculi, 24
 Capsular ligament of hip, 254
 Capsule of knee, 272
 " shoulder, 126
 Caries of vertebræ, 117
 Carotid region, 82, 86
 " common, 86, 87
 " " ligature of, 90, 91
 " external, 88
 " " ligature of, 92
 " internal, 89
 " tubercle, 91
 Carpus, 160
 Castration, 214

- Catheterism of male urethra, 230
 " female urethra, 230
 " Eustachian tube, 41
 " nasal duct, 37
 Cephalæmatoma, 3
 Cervical region, 61
 " fasciæ, 63
 Chopart's amputation, 297
 Chassaignac's tubercle, 91
 Chest, tapping the, 110
 Circumflex branch of axillary artery, 138
 " " of femoral artery, 245
 Clavicle, fracture of, 121, 122
 Club foot, 293
 Collateral circulation after ligature of axillary, 141
 " " brachial, 146
 " " carotid, common, 92
 " " " external, 92
 " " femoral, 246
 " " iliac, common, 198
 " " " external, 199
 " " innominata, 100
 " " subclavian, 98
 Colles's fracture, 164
 Colon, 200
 Colotomy, 203
 Condyles of femur, 272, 273
 " humerus, 147, 154
 Congenital hernia, 188
 " hydrocele, 188
 Conjoined tendon, 184
 Conjunctiva, 21
 Contre-coup, 12
 Convolutions of cerebrum, relations of to cranium, 9, 10, 11
 Coracoid process, 124, 127
 Coronoid process, 159
 Cord, spermatic, 210
 " umbilical, 180
 Coverings of herniæ, 188, 193
 " of testis, 214
 Cranium, 1
 " fractures of, 12, 13
 Cremaster muscle, 209
 Crural arch, 183
 " " deep, 193
 " canal, 192
 " hernia, 193
 " region, 190
 " ring, 193

- D**ARTOS, 209
 Deep palmar arch, 171
 Diaphragm, region of, 113
 Digital arteries of foot, 299
 „ „ hand, 174
 Diploë, 7, 13
 Direct inguinal hernia, 188
 Dislocation of ankle, 287
 „ carpus, 164
 „ femur, 256
 „ humerus, 127
 „ lower jaw, 55
 „ patella, 272
 „ thumb, 175
 „ ulna, 154
 „ vertebræ, 102
 Dorsal region, injuries to cord in, 117
 Dorsalis pedis artery, 290
 Dorsum of foot, 289
 „ hand, 162, 174
 Dura mater, 9, 15
- E**AR. external, 13
 Ecchymosis of conjunctiva, 13
 „ orbitar, 13
 „ subconjunctival, 28
 Elbow, amputation at, 152
 „ bend of, 148
 „ dislocation of, 159
 „ excision of, 151
 „ joint, 153
 „ region of, 147
 Empyema, 110
 Epididymis, 214
 Epigastric artery, deep, 179, 190
 „ „ irregularities of, 194
 „ „ superficial, 183
 Epiphora, 26
 Epiphyses of femur, 273, 277
 „ humerus, 128, 146, 148
 „ radius, 154, 159
 „ tibia, 277
 Eustachian tube, 15
 Excision (*vide* special subjects)
 Extravasation of urine, 209
 Eyeball, 28
 „ extirpation of, 31
 Eyelids, 20

- F**ACE, region of, 15
 Facial artery, 16
 Fascia, anal, 221
 ,, axillary, 135
 ,, bicipital, 149
 ,, brachial, 142
 ,, cervical, 63
 ,, cibriform, 191
 ,, epi-cranial, 2
 ,, iliaca, 195
 ,, infundibuliform, 184
 ,, intercolumnar, 184
 ,, lata, 183, 242, 261
 ,, lumbar, 203
 ,, obturator, 249
 ,, palmar, 168
 ,, pelvic, 232
 ,, perineal, male, 216
 ,, ,, female, 231
 ,, pharyngeal, 60
 ,, plantar, 291
 ,, popliteal, 268
 ,, recto-vesical, 233
 ,, temporal, 5
 ,, transversalis, 179, 180
 Fauces, 46
 Femoral artery, common, 243
 ,, ,, superficial, 244
 ,, ,, ,, ligature o', 246
 ,, ,, ,, in Hunter's canal, 262
 ,, ,, ,, ligature in, 264
 ,, region, superior, 241
 ,, ,, middle, 266
 Femur, dislocation of, 256
 ,, excision of head of, 259
 ,, fractures of, 255, 265
 Fibula, fractures of, 282
 Fingers, amputation of, 174
 ,, region of, 173
 Fissure of anus, 219
 ,, palate, 47, 49
 Fistula in ano, 221
 ,, lachrymal, 26
 ,, salivary, 51
 ,, urinary, 236
 Fontanelles, 12
 Foot, amputations of, 295
 ,, disarticulations of, 289, 295
 ,, excision of bones of, 288, 289
 ,, region of, 289

Forearm, region of, 154
 Fossa, ischio-rectal, 221
 „ nasal, 33
 „ navicular, 227
 Fracture (*vide* the several bones)
 Frænum linguæ, 57
 Frontal sinuses, 41

GIMBERNAT'S ligament, 183

Glands, axillary, 133, 139
 „ Cowper's, 228
 „ inguinal, 183
 „ lachrymal, 22
 „ mammary, 112
 „ parotid, 49, 50
 „ popliteal, 269
 „ prostate, 235
 „ submaxillary, 69
 „ thymus, 77
 „ thyroid, 74

Glans penis, 226

Glenoid cavity, 127

Glottis (*vide* Trachea)

Gluteal region, 246

„ artery, ligature of, 247

Groin (*vide* Inguinal Region)

HÆMATOCELE, 213

Hæmorrhoidal arteries, 221
 „ veins, 220

Hand, region of, 166

Hard palate, 44

Harelip, 44

Heart, 107

Hernia, congenital, 188

„ diaphragmatic, 114
 „ inguinal, 186
 „ direct, 188
 „ femoral, 193
 „ oblique, 186, 188
 „ obturator, 249
 „ sciatic, 248
 „ umbilical, 180

Hip-joint, amputation at, 259

„ dislocation at, 256
 „ excision of, 259
 „ region of, 249

Humerus, dislocation of, 127
 „ excision of head of, 130
 „ fractures of, 125
 Hydrocele, 212
 „ congenital, 188
 Hyoid region, 68

ILIAC abscess, 206
 „ fossa, 195
 „ artery, common, 196
 „ „ „ ligature of, 197
 „ „ external, 198
 „ „ „ ligature of, 198
 Ilio-femoral triangle, 252
 Infantile hernia, 189
 Inguinal canal, 186
 „ region, 181
 Innominata, 99
 „ ligature of, 100
 Inspiration, diaphragm in, 114
 „ lung in, 110
 „ subclavian triangle during, 94
 Intercostal artery, 110
 „ muscles, 110
 „ spaces, 110
 Internal abdominal ring, 186
 „ carotid artery, 89
 „ mammary artery, 111
 „ maxillary artery, 53
 Introduction of aural speculum, 14
 „ catheter, male, 230
 „ „ female, 230
 „ probe into canaliculus, 25
 „ „ Eustachian tube, 41
 „ „ nasal duct, 25
 „ œsophagus tube, 80
 „ rectum bougie, 239
 Ischio-rectal fossa, 221
 Isthmus of fauces, 46
 „ of thyroid, 74
 Jaws (*vide* Maxillæ)

KIDNEY (*vide* Abdomen, region of)
 Knee, excision of, 276
 Knee, joint, 271
 „ region of, 266, 271

- L**ACHRYMAL apparatus, 22
 „ gland 22,
 „ sac, 24
 „ introduction of probe, 25
 Laryngotomy, 77
 Larynx, 72
 Leg, region of, 277
 Ligament, annular, of ankle, 287
 „ „ wrist, 161
 „ Gimbernat's, 183
 „ Hey's, 191
 „ Poupart's, 183
 Ligature of artery—
 anterior tibial, 280
 „ axillary, 139, 140
 „ brachial, 145
 „ carotid, common, 90, 91
 „ „ external, 88, 92
 „ „ internal, 89
 „ dorsalis pedis, 291
 „ femoral, 245, 264
 „ iliac, external, 198
 „ innominata, 99
 „ lingual, 71
 „ mammary, internal, 11
 „ popliteal, 271
 „ posterior tibial, 281
 „ radial, 157
 „ subclavian, 98
 „ ulnar, 158
 Lingual region, 55
 „ artery, 57, 71
 Lithotomy in child, 225
 „ female, 231
 „ male, 222
 Lithotrity, 231
 Lumbar region, 199
 „ colotomy, 203
 „ fascia, 203
 Lungs, 106, 107
 Lymphatic glands (*vide* each region)

- M**ALLEOLUS, inner, 285
 „ outer, 284
 Mamma, 112
 „ excision of, 113
 Mammary artery, internal, 111
 „ region, 112
 Mastoid process, 7

- Maxilla, superior, 42
 „ excision of, 44
 „ inferior, 53
 Maxillary artery, internal, 53
 Meatuses of nose, 36
 Mediastina, 118
 Membrana tympani, 14
 Meningeal artery (middle), 6, 9
 Metacarpal bone of thumb, 169
 „ „ „ amputation of, 169
 Metacarpus, 169, 170

- N** APE, region of, 101
 Nares, anterior, 34, 37
 „ posterior, 34, 38
 Nasal fossæ, 33
 Naso-pharyngeal region, 58
 Neck, region of, 61
 „ fasciæ of, 63, 64, 65, 66
 Nerves (*see* several regions)
 Nose, region of, 34
 „ sinuses of, 33
 Nostrils, syringing, 40
 Nutrient arteries of humerus, 146
 „ tibia, 281

- O** BLIQUE inguinal hernia, 186, 188
 Obturator artery, 248
 „ canal, 249
 „ hernia, 249
 „ region, 248
 Occipital region, 81
 Occipito-frontal region, 1
 Œsophagus, 79
 Œsophagotomy, 80
 Olecranon, 154
 Orbital aponeuroses, 27
 „ region, external, 19
 „ „ internal, 27

- P** ALATE, region of, 45
 „ cleft, 46
 Palm, 166
 Palmar arches, 167, 170, 171
 „ „ wounds of, 172

- Paracentesis thoracis, 110
 " abdominis, 180
 Paralysis of diaphragm, 115
 " " " cervical region, 102
 " after injury in dorsal region, 117
 " of third nerve, 30
 " of fourth nerve, 30
 " of sixth nerve, 30
 Parotid gland, duct of, 19
 " " facial part of, 18
 " " relations of, 50
 " region, 49
 Parts beneath deltoid, 123, 124
 " gluteus maximus, 247
 " pectoralis major, 135
 " mylo-hyoid, 70
 " sterno-mastoid, 84
 Patella, dislocation of, 272
 " fracture of, 275
 Pelvis, region of, 208
 Perineal abscess, 221
 " region, 209, 215
 Penis, 226
 Pericranium, 3
 Peroneal region (*vide* Leg, region of)
 Phalanges of fingers, 173, 174
 " toes, 299
 Pharynx, 57
 Piles, 220
 Plantar region, 291
 " fascia, 291
 Popliteal artery, 269
 " space, 268
 Pott's fracture, 282
 Pouch, recto-vesical, 233
 Prostate gland, 235
 Psoas muscle, 200, 202
 Pterygoid region, 52
 Pudic artery, 218
 Pulmonary orifice, 108
 Puncta lachrymalia, 24
 Puncture of bladder above pubes, 222, 235
 " " per rectum, 222, 236

RADIAL artery, 157, 171
 Radius, 159, 164
 Recti muscles of eye, 22, 30, 31

- Rectum, 219, 220, 238
 Relations of bony prominences at elbow, 154
 " " " at hip, 251
 " " " at knee, 266
 " " " at shoulder, 120
 " " " at wrist, 160
 " of cerebrum to cranium, 9
 Relations of viscera to abdominal walls, 176
 " thoracic walls, 106, 107, 108
 Rima glottidis (*vide* Larynx)
 Ribs, 110
 " fracture of, 110
 Ring, external abdominal, 183
 " internal " 186
 " crural, 193
 Rolando, fissure of, 9
 Round ligament of hip, 255

SAC of hernia (*vide* Hernia)

- " lachrymal, 24
 Sacro-iliac disease, 207
 Scapular region, 124
 Scarpa's triangle, 242
 Sclerotic, 22, 28
 Scrotum, 209
 Sections of—

- " abdomen
 " ankle
 " arm, fore
 " " upper
 " elbow-joint
 " foot
 " hip-joint
 " intercostal spaces
 " knee-joint
 " meatus of ear
 " metacarpus
 " neck
 " pelvis, male
 " " female
 " shoulder-joint
 " spermatic cord
 " tarsus
 " thigh
 " wrist

Vide list of
 woodcuts.

Septum crurale, 193

- Sheath of axillary vessels, 136**
 „ carotid, 65
 „ femoral vessels, 192
 „ crural, 192
 „ of rectus muscle, 179
Shoulder, region of, 120
 „ joint, 126
Sinus, lateral, 7, 15
 „ of nose, 41
Skull, fractures of, 12, 13
 „ tables of, 8, 9
Sole, region of, 291
Spermatic artery, 210
 „ vein, 210
Sphincter ani, 219
Spina bifida, 103
Spinal cord, injuries of, 102, 117
Spine, 102, 115, 200
Staphyloraphy, 47
Sternal region, 108
Sterno-clavicular joint, 108
Sterno-mastoid region, 81
Sternum, 108
Stomach, 176
Strabismus, 31
Structures divided in amputation of ankle-joint, 289
 „ „ arm, upper, 143, 144
 „ „ elbow-joint, 152, 153
 „ „ forearm, 158
 „ „ hip-joint, 259
 „ „ leg, 283
 „ „ medio-tarsal, 298
 „ „ shoulder-joint, 130
 „ „ tarso-metarsal, 296
 „ „ thigh, 264
 „ in Amussat's operation, 203
 „ „ cleft palate, 46, 47
 „ „ cutting down on cranium in occipito-
 frontal region, 5
 temporo-parietal, 7
 „ „ „ excision of elbow, 152, 153
 „ „ „ head of femur, 259
 „ „ „ head of humerus, 131
 „ „ „ knee-joint, 277
 „ „ „ maxilla, upper, 44
 „ „ extirpation of eyeball, 31
 „ „ „ testis, 214
 „ „ the operation for fistula in ano, 222

- Structures divided in the operation for harelip, 18, 44
 " " " " herniotomy, 190
 " " " " laryngotomy, 77
 " " " " strabismus, 31
 " " " " tracheotomy, 77, 78, 79
 Structures in contact with ankle-joint, 285
 " " elbow- " 152, 153
 " " hip- " 249
 " " knee- " 274
 " " shoulder-joint, 126
 " " wrist- " 161, 162
 Subclavian artery, 97, 98
 " " compression of, 95
 " " ligature of, 98
 " region, 93, 94, 95, 96
 Submaxillary region, 68
 " gland, 69
 Surface markings (*vide* the Topography of the several regions),
 Sutures of skull, 11
 Synovial membranes of foot, 298
 " " wrist and palm, 164, 169

TABLES of skull, 7, 8

- Tarsus, 289
 " amputations through, 295, 296, 297, 298
 Tarsal cartilages, 21
 Temporal artery, 4, 6
 " bone, 13
 " nerves, 4
 " vein, 4
 Temporo-parietal region, 5
 " maxillary articulation, 54
 Tendo-Achillis, 280
 Tenotomy of sterno-mastoid, 93
 " hamstrings, 268
 " for club-foot, 294
 Teno-synovitis, 157
 Testicle, 213
 Thecal abscess, 173
 Thoracica suprema artery, 138
 " acromialis, 138
 " alar, 138
 " long, 138
 Thorax, 104
 " relations of structures in superior aperture of, 105
 " relations of contents to walls of, 106, 107, 108
 " cavity of, 118

- Thorax, walls of, 108
 Thymus gland, remains of, 77
 Thyroid body, 80
 " artery, superior, 75
 " " inferior, 75
 " veins, inferior, 75
 Thymoidea ima artery, 78
 Thyrotomy, 76
 Tibial region, 278
 " anterior, artery, 279
 " posterior, artery, 280, 281
 Toes, 299
 Tongue, 55
 Tonsil, region of, 47
 " excision of, 48, 49
 " abscess of, 48
 Topography of abdomen, 176
 " axilla, 133
 " bend of elbow, 148
 " brachial region, 142
 " carotid region, 82
 " clavicular, 121
 " cranial region, 1, 2, 5
 " crural region, 190
 " epicranial, 2, 5
 " face, 15
 " femoral region, 241, 261
 " forearm, 155
 " gluteal region, 246
 " infra-hyoid region, 72
 " inguinal region, 182
 " leg, 277
 " lingual region, 55
 " lumbar region, 199
 " malleolar region, 283
 " nape of neck, 101
 " nasal region, 31
 " orbit, 19
 " occipito-frontal region, 2
 " palm, 167
 " parotid region, 49
 " pharyngeal region, 57
 " plantar region, 291
 " popliteal space, 268
 " pterygo-maxillary region, 52
 " perineum, 216, 220
 " scapular, 124
 " sternal region, 108
 " subclavian region, 95

- Topography of submaxillary region, 69
 „ superior maxillary region, 42
 „ temporo-parietal region, 5
 „ wrist, 161, 162
 Trachea, 76
 Tracheotomy, 77, 78, 79
 Transversalis fascia, 179, 184
 Transversus perinei artery, 217
 „ muscle, 217
 Trephining, 8, 9
 Triangles of neck (*vide* Region of Neck)
 Triangular ligament of urethra, 218
 Tunica vaginalis testis, 211
 Tympanum, 14, 15


- U**LNAR, fractures of, 159
 „ artery in fore-arm, 157
 „ at wrist, 163
 Umbilicus, 180
 Ureter (*vide* Cavity of Abdomen)
 Urethra, male, 227
 „ female, 230
 Urine, extravasation of, 209

- V**ALVES of heart, positions of, 107, 108
 Varicocele, 210
 Varicose aneurism, 150
 Vas deferens, 210
 Venesection, 150
 Vein, basilic, 142
 „ cephalic, 142
 „ diploic, 7
 „ jugular, external, 63
 „ „ internal, 88, 90
 „ median, cephalic, 148
 „ „ basilic, 148
 „ præparata, 4
 „ saphena, internal, 261
 „ subclavian, pulsation in, 94
 Vertebræ, cervical, 102, 103
 „ dorsal, 116
 „ lumbar, 199
 Vertebral aponeurosis, 64
 „ artery, 86
 Vesicula seminales, 235
 Viscera, abdominal, 176

Viscera, pelvic, 232
„ thoracic, 105, 118
Vulva, 232

WRIST, region of, 160
Wryneck, 93

ZYGOMA, 5



WORKS PUBLISHED BY

AN ATLAS OF HUMAN ANATOMY.

By RICKMAN J. GODLEE, M.S., F.R.C.S., Assistant-Surgeon to University College Hospital and Senior Demonstrator of Anatomy in University College.

In 12 Parts. Imp. 4to, 7s. 6d. each.

THE OBJECT OF THE AUTHOR IS:—

1. To supply a full illustration of the Anatomy of the Human Body in a form sufficiently portable to be easy of reference.
2. By illustrating Dissections not usually seen in the dissecting-room, to enable the student to understand the mutual relations of parts.
3. By making the Dissections follow one after another, to render him some assistance in working out for himself the steps by which particular organs and regions may be exposed.

The work will consist of twelve parts (ten of which have already appeared), each containing Four Coloured Plates (several Figures). They illustrate Dissections of the Head and Neck (excluding the brain), the Upper and Lower Limbs, and the Thorax and Abdomen from the front and from behind.

The letterpress contains a description of the manner in which the Dissections were made, of the Structures exposed, as well as references to their Medical and Surgical Anatomy.

“The plates are very carefully executed, the text is well written, and will repay a careful perusal.”—*Dublin Medical Journal*.

“The text gives evidence of an extensive acquaintance with anatomical literature.”—*Edinburgh Medical Journal*.

“The series of plates gives a very lucid and practical idea of this most difficult and important part of the human body.”—*Medical Times and Gazette*.

“The dissections are perfect, and the execution of the plates faultless, and will be appreciated by all who have attempted to dissect the most important anatomical regions here delineated. . . . The whole of these plates are of the same high order of merit as those which have preceded them. Indeed, they leave nothing to be desired as regards distinctness, colouring, and accuracy of detail. . . . Beautiful and rare dissections.”—*Students' Journal*.

J. & A. CHURCHILL, NEW BURLINGTON STREET.

WORKS PUBLISHED BY

BRAUNE'S ATLAS OF TOPOGRAPHICAL ANATOMY

AFTER PLANE SECTIONS OF FROZEN BODIES.

Translated by EDWARD BELLAMY, F.R.C.S., Surgeon to, Lecturer on Anatomy and formerly Teacher of Operative Surgery in, Charing Cross Hospital. With 34 Plates and 46 Woodcuts. 4to, 40s.

The great success of Professor Braune's "Atlas" abroad has suggested the reproduction of the volume in English. The immense expense of reproducing such plates and the persistent dearth of material have, in all probability, been the cause why no original English work on topographical anatomy has as yet been placed within the reach of the generality of students. It is generally admitted that there is a want in this country of a good text book on applied anatomy—not a mere hand-book. By means of the sections found in this "Atlas" the exact position and the relations of the structures which must be divided or avoided in the course of an operation are indicated; and the track of a bullet or punctured wound suggested. At the same time, they afford an absolutely correct representation of the intimate relations of the viscera of the thorax and abdomen. Each plate is accompanied by descriptive text, adapted by the translator to the requirements of the English student.

"Mr. Bellamy has been happily inspired in introducing to the British surgeon and anatomist this most valuable atlas."—*British Medical Journal*.

"It will speedily be found in the hands of every advanced anatomical student, and is absolutely indispensable to the anatomical teacher and to every surgeon, whether in military or civil practice."—*Lancet*.

"A more complete book upon sectional anatomy could hardly be published."—*Edinburgh Medical Journal*.

"The finest anatomical work that has been published in this country for a long time."—*Students' Journal*.

J. & A. CHURCHILL, NEW BURLINGTON STREET.

LONDON, *November*, 1879.

J. & A. CHURCHILL'S
MEDICAL CLASS BOOKS.

ANATOMY.

BRAUNE.—An Atlas of Topographical Anatomy, after Plane Sections of Frozen Bodies. By WILHELM BRAUNE, Professor of Anatomy in the University of Leipzig. Translated by EDWARD BELLAMY, F.R.C.S., Surgeon to Charing-Cross Hospital, and Lecturer on Anatomy in its School. With 34 Photo-lithographic Plates and 46 Woodcuts. Large imp. 8vo, 40s.

FLOWER.—Diagrams of the Nerves of the Human Body, exhibiting their Origin, Divisions, and Connexions, with their Distribution to the various Regions of the Cutaneous Surface, and to all the Muscles. By WILLIAM H. FLOWER, F.R.C.S., F.R.S., Conservator of the Museum of the Royal College of Surgeons. Second Edition, containing 6 Plates. Royal 4to, 12s.

GODLEE.—An Atlas of Human Anatomy: illustrating most of the ordinary Dissections; and many not usually practised by the Student. By RICKMAN J. GODLEE, M.S., F.R.C.S., Assistant-Surgeon to University College Hospital, and Senior Demonstrator of Anatomy in University College. To be completed in 12 or 13 Bi-monthly Parts, each containing 4 Coloured Plates, with Explanatory Text. Parts I to X. Imp. 4to, 7s. 6d. each.

HEATH.—Practical Anatomy: a Manual of Dissections. By CHRISTOPHER HEATH, F.R.C.S., Holme Professor of Clinical Surgery in University College and Surgeon to the Hospital. Fourth Edition. With 16 Coloured Plates and 264 Engravings. Crown 8vo, 14s.

NEW BURLINGTON STREET.

ANATOMY—continued.

HOLDEN.—Human Osteology: comprising a Description of the Bones. with Delineations of the Attachments of the Muscles, the General and Microscopical Structure of Bone and its Development. By LUTHER HOLDEN, F.R.C.S., Senior Surgeon to St. Bartholomew's and the Foundling Hospitals, and ALBAN DORAN, F.R.C.S., late Anatomical, now Pathological, Assistant to the Museum of the Royal College of Surgeons. Fifth Edition. With 61 Lithographic Plates and 89 Engravings. Royal 8vo, 16s.

By the same Author.

A Manual of the Dissection of the Human Body. Fourth Edition. Revised by the Author and JOHN LANGTON, F.R.C.S., Assistant Surgeon and Lecturer on Anatomy at St. Bartholomew's Hospital. With Engravings. 8vo, 16s.

ALSO,

Landmarks, Medical and Surgical. Second Edition. 8vo, 3s. 6d.

MORRIS.—The Anatomy of the Joints of Man. By HENRY MORRIS, M.A., F.R.C.S., Surgeon to, and Lecturer on Anatomy and Practical Surgery at, the Middlesex Hospital. With 44 Plates (19 Coloured) and Engravings. 8vo, 16s.

WAGSTAFFE.—The Student's Guide to Human Osteology. By WM. WARWICK WAGSTAFFE, F.R.C.S., Assistant-Surgeon to, and Lecturer on Anatomy at, St. Thomas's Hospital. With 23 Plates and 63 Engravings. Fcap. 8vo, 10s. 6d.

WILSON.—The Anatomist's Vade-Mecum: a System of Human Anatomy. By ERASMUS WILSON, F.R.C.S., F.R.S., late Professor of Dermatology to the Royal College of Surgeons. Ninth Edition, by G. BUCHANAN, M.A., M.D., late Professor of Clinical Surgery in the University of Glasgow, and HENRY E. CLARK, F.F.P.S., Lecturer on Anatomy in the Glasgow Royal Infirmary School of Medicine. With 371 Engravings. Crown 8vo, 14s.

Anatomical Remembrancer (the); or, Com-plete Pocket Anatomist. Eighth Edition. 32mo, 3s. 6d.

NEW BURLINGTON STREET.

BOTANY.

BENTLEY.—**A Manual of Botany.** By Robert BENTLEY, F.L.S., Professor of Botany in King's College and to the Pharmaceutical Society. With 1138 Engravings. Third Edition. Crown 8vo, 14s.

BENTLEY AND TRIMEN.—**Medicinal Plants:** being descriptions, with original Figures, of the Principal Plants employed in Medicine, and an account of their Properties and Uses By ROBERT BENTLEY, F.L.S., and HENRY TRIMEN, M.B., F.L.S., British Museum, and Lecturer on Botany at St. Mary's Hospital Medical School. To be completed in 42 Monthly Parts, each containing 8 Coloured Plates. Parts I. to XL. Large 8vo, 5s. each part.

CHEMISTRY.

BERNAYS.—**Notes for Students in Chemistry;** being a Syllabus of Chemistry compiled mainly from the Manuals of Fownes-Watts, Miller, Wuz, and Schorlemmer. By ALBERT J. BERNAYS, Ph.D., Professor of Chemistry at St. Thomas's Hospital, Examiner in Chemistry at the Royal College of Physicians of London. Sixth Edition. Fcap. 8vo, 3s. 6d.

By the same Author.

Skeleton Notes on Analytical Chemistry,
for Students in Medicine. Fcap. 8vo, 2s. 6d.

BLOXAM.—**Chemistry, Inorganic and Organic;** with Experiments. By CHARLES L. BLOXAM, Professor of Chemistry in King's College. Third Edition. With 295 Engravings. 8vo, 15s.

By the same Author.

Laboratory Teaching; or, Progressive
Exercises in Practical Chemistry. Fourth Edition. With 88 Engravings. Crown 8vo, 5s. 6d.

BOWMAN AND BLOXAM.—**Practical Chemistry,** including Analysis. By JOHN E. BOWMAN, Formerly Professor of Practical Chemistry in King's College, and CHARLES L. BLOXAM, Professor of Chemistry in King's College. With 98 Engravings. Seventh Edition. Fcap. 8vo, 6s. 6d.

CHEMISTRY—continued.

CLOWES.—**Practical Chemistry and Qualitative Inorganic Analysis.** An Elementary Treatise specially adapted for use in the Laboratories of Schools and Colleges, and by Beginners. By FRANK CLOWES, D.SC., Senior Science Master at the High School, Newcastle-under-Lyme. Second Edition. With 47 Engravings. Post 8vo, 7s. 6d.

FOWNES AND WATTS.—**Physical and Inorganic Chemistry.** Twelfth Edition. By GEORGE FOWNES, F.R.S., and HENRY WATTS, B.A., F.R.S. With 154 Engravings, and Coloured Plate of Spectra. Crown 8vo, 8s. 6d.

By the same Authors.

Chemistry of Carbon - Compounds, or Organic Chemistry. Twelfth Edition. With Engravings. Crown 8vo, 10s.

GALLOWAY.—**A Manual of Qualitative Analysis.** By ROBERT GALLOWAY, Professor of Applied Chemistry in the Royal College of Science for Ireland. Fifth Edition. With Engravings. Post 8vo, 8s. 6d.

VACHER.—**A Primer of Chemistry, including Analysis.** By ARTHUR VACHER. 18mo, 1s.

VALENTIN.—**Introduction to Inorganic Chemistry.** By WILLIAM G. VALENTIN, F.C.S., Late Principal Demonstrator of Practical Chemistry in the Science Training Schools. Third Edition. With 82 Engravings. 8vo, 6s. 6d.

By the same Author.

A Course of Qualitative Chemical Analysis. Fourth Edition. With 19 Engravings. 8vo, 7s. 6d.

ALSO,

Chemical Tables for the Lecture-room and Laboratory. In Five large Sheets, 5s. 6d.

NEW BURLINGTON STREET.

CHILDREN, DISEASES OF.

ELLIS.—A Practical Manual of the Diseases of Children. By EDWARD ELLIS, M.D., late Senior Physician to the Victoria Hospital for Sick Children. With a Formulary. Third Edition. Crown 8vo, 7s. 6d.

SMITH.—Clinical Studies of Disease in Children. By EUSTACE SMITH, M.D., F.R.C.P., Physician to H.M. the King of the Belgians, and to the East London Hospital for Children. Post 8vo, 7s. 6d.

By the same Author.

On the Wasting Diseases of Infants and Children. Third Edition. Post 8vo, 8s. 6d.

STEINER.—Compendium of Children's Diseases; a Handbook for Practitioners and Students. By JOHANN STEINER, M.D. Translated from the Second German Edition, by LAWSON TAIT, F.R.C.S., Surgeon to the Birmingham Hospital for Women, &c. 8vo, 12s. 6d.

DENTISTRY.

SEWILL.—The Student's Guide to Dental Anatomy and Surgery. By HENRY E. SEWILL, M.R.C.S., L.D.S., late Dental Surgeon to the West London Hospital. With 77 Engravings. Fcap. 8vo, 5s. 6d.

SMITH.—Handbook of Dental Anatomy and Surgery. For the Use of Students and Practitioners. By JOHN SMITH, M.D., F.R.S.E., Dental Surgeon to the Royal Infirmary, Edinburgh. Second Edition. Fcap. 8vo, 4s. 6d.

STOCKEN.—Elements of Dental Materia Medica and Therapeutics, with Pharmacopœia. By JAMES STOCKEN, L.D.S.R.C.S., Lecturer on Dental Materia Medica and Therapeutics and Dental Surgeon to the National Dental Hospital. Second Edition. Fcap. 8vo, 6s. 6d.

DENTISTRY—*continued.*

TAFT.—**A Practical Treatise on Operative Dentistry.** By JONATHAN TAFT, D.D.S., Professor of Operative Surgery in the Ohio College of Dental Surgery. Third Edition. With 134 Engravings. 8vo, 18s.

TOMES (C. S.).—**Manual of Dental Anatomy, Human and Comparative.** By CHARLES S. TOMES, M.A., M.R.C.S., Lecturer on Anatomy and Physiology at the Dental Hospital of London. With 179 Engravings. Crown 8vo, 10s. 6d.

TOMES (J. and C. S.).—**A Manual of Dental Surgery.** By JOHN TOMES, M.R.C.S., F.R.S., Consulting Surgeon-Dentist to Middlesex Hospital; and CHARLES S. TOMES, M.A., M.R.C.S., Lecturer on Anatomy and Physiology at the Dental Hospital of London. Second Edition. With 262 Engravings. Fcap. 8vo, 14s.

EAR, DISEASES OF.

BURNETT.—**The Ear: its Anatomy, Physiology, and Diseases.** A Practical Treatise for the Use of Medical Students and Practitioners. By CHARLES H. BURNETT, M.D., Aural Surgeon to the Presbyterian Hospital, Philadelphia. With 87 Engravings. 8vo, 18s.

DALBY.—**On Diseases and Injuries of the Ear.** By WILLIAM B. DALBY, F.R.C.S., Aural Surgeon to, and Lecturer on Aural Surgery at, St. George's Hospital. With Engravings. Fcap. 8vo, 6s. 6d.

JONES.—**A Practical Treatise on Aural Surgery.** By H. MACNAUGHTON JONES, M.D., Professor of the Queen's University in Ireland, Surgeon to the Cork Ophthalmic and Aural Hospital. With 46 Engravings. Crown 8vo, 5s.

By the same Author.

Atlas of the Diseases of the Membrana Tympani. In Coloured Plates, containing 59 Figures. With Explanatory Text. Crown 4to, 21s.

NEW BURLINGTON STREET.

FORENSIC MEDICINE.

OGSTON.—Lectures on Medical Jurisprudence.

By FRANCIS OGSTON, M.D., Professor of Medical Jurisprudence and Medical Logic in the University of Aberdeen. Edited by FRANCIS OGSTON, Jun., M.D., Assistant to the Professor of Medical Jurisprudence and Lecturer on Practical Toxicology in the University of Aberdeen. With 12 Plates. 8vo, 18s.

TAYLOR.—The Principles and Practice of

Medical Jurisprudence. By ALFRED S. TAYLOR, M.D., F.R.S., Professor of Medical Jurisprudence to Guy's Hospital. Second Edition. With 189 Engravings. 2 Vols. 8vo, 31s. 6d.

By the same Author.

A Manual of Medical Jurisprudence.

Tenth Edition. With 55 Engravings. Crown 8vo, 14s.

ALSO,

On Poisons, in relation to Medical Juris-

prudence and Medicine. Third Edition. With 104 Engravings. Crown 8vo, 16s.

WOODMAN AND TIDY.—A Handy-Book of

Forensic Medicine and Toxicology. By W. BATHURST WOODMAN, M.D., F.R.C.P.; and C. MEYMOTT TIDY, M.B., Professor of Chemistry and of Medical Jurisprudence, &c., at the London Hospital. With 8 Lithographic Plates and 116 Wood Engravings. 8vo, 31s. 6d.

HYGIENE.

WILSON.—A Handbook of Hygiene and Sani-

tary Science. By GEORGE WILSON, M.A., M.D., Medical Officer of Health for Mid Warwickshire. Fourth Edition. With Engravings. Post 8vo, 10s. 6d.

NEW BURLINGTON STREET.

HYGIENE—*continued.*

PARKES.—A Manual of Practical Hygiene.

By EDMUND A. PARKES, M.D., F.R.S. Fifth Edition by F. DE CHAUMONT, M.D., F.R.S., Professor of Military Hygiene in the Army Medical School. With 9 Plates and 112 Engravings. 8vo, 18s.

By the same Author.

Public Health: being a Concise Sketch of

the Sanitary Considerations connected with the Land, with Cities, Villages, Houses, and Individuals. Revised by WILLIAM AITKEN, M.D., F.R.S., Professor of Pathology in the Army Medical School. Crown 8vo, 2s. 6d.

MATERIA MEDICA AND THERAPEUTICS.

BINZ AND SPARKS.—The Elements of Thera-

peutics: a Clinical Guide to the Action of Medicines. By C. BINZ, M.D., Professor of Pharmacology in the University of Bonn. Translated from the Fifth German Edition, and Edited with Additions, in conformity with the British and American Pharmacopœias, by EDWARD I. SPARKS, M.A., M.B. Oxon., F.R.C.P. Lond. Crown 8vo, 8s. 6d.

ROYLE AND HARLEY.—A Manual of Materia

Medica and Therapeutics. By J. FORBES ROYLE, M.D., F.R.S., formerly Professor of Materia Medica in King's College; and JOHN HARLEY, M.D., F.R.C.P., Physician to, and Joint Lecturer on Clinical Medicine at, St. Thomas's Hospital. Sixth Edition. With 139 Engravings. Crown 8vo, 15s.

THOROWGOOD.—The Student's Guide to

Materia Medica. By JOHN C. THOROWGOOD, M.D., F.R.C.P., Lecturer on Materia Medica at the Middlesex Hospital. With Engravings. Fcap. 8vo, 6s. 6d.

WARING.—A Manual of Practical Therapeu-

tics. By EDWARD J. WARING, M.D., F.R.C.P., Retired Surgeon H.M. Indian Army. Third Edition. Fcap. 8vo, 12s. 6d.

NEW BURLINGTON STREET.

MEDICINE.

BARCLAY.—A Manual of Medical Diagnosis.

By A. WHYTE BARCLAY, M.D., F.R.C.P., Physician to, and Lecturer on Medicine at, St. George's Hospital. Third Edition. Fcap. 8vo, 10s. 6d.

BARLOW.—A Manual of the Practice of

Medicine. By HILARO BARLOW, M.D., Formerly Senior Physician to Guy's Hospital. Second Edition. Fcap. 8vo, 7s. 6d.

CHARTERIS.—The Student's Guide to the

Practice of Medicine. By MATTHEW CHARTERIS, M.D., Professor of Practice of Medicine, Anderson's College; Physician and Lecturer on Clinical Medicine, Royal Infirmary, Glasgow. With Engravings on Copper and Wood. Second Edition. Fcap. 8vo, 6s. 6d.

FENWICK.—The Student's Guide to Medical

Diagnosis. By SAMUEL FENWICK, M.D., F.R.C.P., Physician to the London Hospital. Fourth Edition. With 106 Engravings. Fcap. 8vo, 6s. 6d.

By the same Author.

The Student's Outlines of Medical Treat-

ment. Fcap. 8vo., 7s.

FLINT.—Clinical Medicine : a Systematic Trea-

tise on the Diagnosis and Treatment of Disease. By AUSTIN FLINT, M.D., Professor of the Principles and Practice of Medicine, &c., in Bellevue Hospital Medical College. 8vo, 20s.

By the same Author.

A Manual of Percussion and Auscultation ;

of the Physical Diagnosis of Diseases of the Lungs and Heart, and of Thoracic Aneurism. Post 8vo, 6s. 6d.

HALL.—Synopsis of the Diseases of the Larynx,

Lungs, and Heart : comprising Dr. Edwards' Tables on the Examination of the Chest. With Alterations and Additions. By F. DE HAVILLAND HALL, M.D., Assistant-Physician to the Westminster Hospital. Royal 8vo, 2s. 6d.

MIDWIFERY.

BARNES.—**Lectures on Obstetric Operations,** including the Treatment of Hæmorrhage, and forming a Guide to the Management of Difficult Labour. By ROBERT BARNES, M.D., F.R.C.P., Obstetric Physician to, and Lecturer on Diseases of Women, &c., at St. George's Hospital. Third Edition. With 124 Engravings. 8vo, 18s.

CLAY.—**The Complete Handbook of Obstetric Surgery;** or, Short Rules of Practice in every Emergency, from the Simplest to the most formidable Operations connected with the Science of Obstetricy. By CHARLES CLAY, M.D., late Senior Surgeon to, and Lecturer on Midwifery at, St. Mary's Hospital, Manchester. Third Edition. With 91 Engravings. Fcap. 8vo, 6s. 6d.

RAMSBOTHAM.—**The Principles and Practice** of Obstetric Medicine and Surgery. By FRANCIS H. RAMSBOTHAM, M.D., formerly Obstetric Physician to the London Hospital. Fifth Edition. Illustrated with 120 Plates, forming one thick handsome volume. 8vo, 22s.

ROBERTS.—**The Student's Guide to the Practice** of Midwifery. By D. LLOYD ROBERTS, M.D., F.R.C.P., Physician to St. Mary's Hospital, Manchester. Second Edition. With 96 Engravings. Fcap. 8vo, 7s.

SCHROEDER.—**A Manual of Midwifery;** including the Pathology of Pregnancy and the Puerperal State. By KARL SCHROEDER, M.D., Professor of Midwifery in the University of Erlangen. Translated by CHARLES H. CARTER, M.D. With Engravings. 8vo, 12s. 6d.

SWAYNE.—**Obstetric Aphorisms for the Use of** Students commencing Midwifery Practice. By JOSEPH G. SWAYNE, M.D., Lecturer on Midwifery at the Bristol School of Medicine. Sixth Edition. With Engravings. Fcap. 8vo, 3s. 6d.

NEW BURLINGTON STREET.

MICROSCOPY.

CARPENTER.—**The Microscope and its Revelations.** By WILLIAM B. CARPENTER, C.B., M.D., F.R.S., late Registrar to the University of London. Fifth Edition. With more than 500 Engravings. Crown 8vo, 15s.

MARSH.—**Section-Cutting: a Practical Guide to the Preparation and Mounting of Sections for the Microscope, special prominence being given to the subject of Animal Sections.** By Dr. SYLVESTER MARSH. With Engravings. Fcap. 8vo, 2s. 6d.

MARTIN.—**A Manual of Microscopic Mounting.** By JOHN H. MARTIN, Member of the Society of Public Analysts, &c. Second Edition. With several Plates and 144 Engravings. 8vo, 7s. 6d.

WYTHE.—**The Microscopist: a Manual of Microscopy and Compendium of the Microscopic Sciences, Micro-Mineralogy, Micro-Chemistry, Biology, Histology, and Pathological Histology.** By J. H. WYTHE, A.M., M.D., Professor of Microscopy and Biology in the San Francisco Medical College. Third Edition. With 205 Illustrations. Royal 8vo, 18s.

OPHTHALMOLOGY.

HIGGENS.—**Hints on Ophthalmic Out-Patient Practice.** By CHARLES HIGGENS, F.R.C.S., Ophthalmic Assistant-Surgeon to, and Lecturer on Ophthalmology at, Guy's Hospital. Second Edition. Fcap. 8vo, 3s.

JONES.—**A Manual of the Principles and Practice of Ophthalmic Medicine and Surgery.** By T. WHARTON JONES, F.R.C.S., F.R.S., Ophthalmic Surgeon and Professor of Ophthalmology to University College Hospital. Third Edition. With 9 Coloured Plates and 173 Engravings. Fcap. 8vo, 12s. 6d.

MACNAMARA.—**A Manual of the Diseases of the Eye.** By CHARLES MACNAMARA, F.R.C.S., Surgeon to Westminster Hospital. Third Edition. With 7 Coloured Plates and 52 Engravings. Fcap. 8vo, 12s. 6d.

OPHTHALMOLOGY—continued.

NETTLESHIP.—The Student's Guide to Diseases of the Eye. By EDWARD NETTLESHIP, F.R.C.S., Ophthalmic Surgeon to, and Lecturer on Ophthalmic Surgery at, St. Thomas's Hospital. With 48 Engravings. Fcap. 8vo, 7s. 6d.

WELLS.—A Treatise on the Diseases of the Eye. By J. SOELBERG WELLS, F.R.C.S., Ophthalmic Surgeon to King's College Hospital, Professor of Ophthalmology at King's College. With Coloured Plates and Engravings. Third Edition. 8vo, 25s.

PATHOLOGY.

JONES AND SIEVEKING.—A Manual of Pathological Anatomy. By C. HANDFIELD JONES, M.B., F.R.S., Physician to St. Mary's Hospital, and EDWARD H. SIEVEKING, M.D., F.R.C.P., Physician to St. Mary's Hospital. Second Edition. Edited by J. F. PAYNE, M.B., Assistant-Physician and Lecturer on General Pathology at St. Thomas's Hospital. With 195 Engravings. Crown 8vo, 16s.

VIRCHOW.—Post-Mortem Examinations: a Description and Explanation of the Method of Performing them, with especial reference to Medico-Legal Practice. By Professor RUDOLPH VIRCHOW, Berlin Charité Hospital. Fcap. 8vo, 2s. 6d.

WILKS AND MOXON.—Lectures on Pathological Anatomy. By SAMUEL WILKS, M.D., F.R.S., Physician to, and Lecturer on Medicine at, Guy's Hospital; and WALTER MOXON, M.D., F.R.C.P., Physician to, and Lecturer on Clinical Medicine at, Guy's Hospital. Second Edition. With 5 Steel Plates. 8vo, 18s.

PSYCHOLOGY.

BUCKNILL AND TUKE.—A Manual of Psychological Medicine: containing the Lunacy Laws, Nosology, Ætiology, Statistics, Description, Diagnosis, Pathology, and Treatment of Insanity, with an Appendix of Cases. By JOHN C. BUCKNILL, M.D., F.R.S., and D. HACK TUKE, M.D., F.R.C.P. Fourth Edition, with 12 Plates (30 Figures). 8vo, 25s.

NEW BURLINGTON STREET.

PHYSIOLOGY.

CARPENTER.—Principles of Human Physiology. With 3 Steel Plates and 371 Engravings. By WILLIAM B. CARPENTER, C.B., M.D., F.R.S., late Registrar to the University of London. Eighth Edition. Edited by Mr. Henry Power. 8vo, 31s. 6d.

By the same Author.

A Manual of Physiology. With upwards of 250 Illustrations. Fifth Edition. Edited by P. H. PYE-SMITH, M.D., F.R.C.P. Crown 8vo. [*In the press.*]

DALTON.—A Treatise on Human Physiology : designed for the use of Students and Practitioners of Medicine. By JOHN C. DALTON, M.D., Professor of Physiology and Hygiene in the College of Physicians and Surgeons, New York. Sixth Edition. With 316 Engravings. Royal 8vo, 20s.

FREY.—The Histology and Histo-Chemistry of Man. A Treatise on the Elements of Composition and Structure of the Human Body. By HEINRICH FREY, Professor of Medicine in Zurich. Translated from the Fourth German Edition, by ARTHUR E. BARKER, Assistant-Surgeon to the University College Hospital. With 608 Engravings. 8vo, 21s.

RUTHERFORD.—Outlines of Practical Histology. By WILLIAM RUTHERFORD, M.D., F.R.S., Professor of the Institutes of Medicine in the University of Edinburgh ; Examiner in Physiology in the University of London. Second Edition. With 63 Engravings. Crown 8vo (with additional leaves for Notes), 6s.

SANDERSON.—Handbook for the Physiological Laboratory : containing an Exposition of the fundamental facts of the Science, with explicit Directions for their demonstration. By J. BURDON SANDERSON, M.D., F.R.S., Professor and Superintendent of the Brown Institution ; E. KLEIN, M.D., F.R.S., Assistant-Professor in the Brown Institution ; MICHAEL FOSTER, M.D., F.R.S., Prælector of Physiology at Trinity College, Cambridge ; and T. LAUDER BRUNTON, M.D., F.R.S., Lecturer on Materia Medica at St. Bartholomew's Hospital Medical College. 2 Vols., with 123 Plates. 8vo, 24s.

SURGERY.

BRYANT. — **A Manual for the Practice of Surgery.** By THOMAS BRYANT, F.R.C.S., Surgeon to, and Lecturer on Surgery at, Guy's Hospital. Third Edition. With 672 Engravings (nearly all original, many being coloured). 2 vols. Crown 8vo, 28s.

BELLAMY.—**The Student's Guide to Surgical Anatomy; a Text-Book for the Pass Examination.** By EDWARD BELLAMY, F.R.C.S., Surgeon to, and Lecturer on Anatomy and Practical Surgery at, Charing Cross Hospital. With 50 Engravings. Fcap. 8vo, 6s. 6d.

CLARK AND WAGSTAFFE. — **Outlines of Surgery and Surgical Pathology.** By F. LE GROS CLARK, F.R.C.S., F.R.S., Consulting Surgeon to St. Thomas's and the Great Northern Hospitals. Second Edition. Revised and expanded by the Author, assisted by W. W. WAGSTAFFE, F.R.C.S., Assistant-Surgeon to St. Thomas's Hospital. 8vo, 10s. 6d.

DRUITT. — **The Surgeon's Vade-Mecum; a Manual of Modern Surgery.** By ROBERT DRUITT, F.R.C.S. Eleventh Edition. With 369 Engravings. Fcap. 8vo, 14s.

FERGUSON.—**A System of Practical Surgery.** By Sir WILLIAM FERGUSON, Bart., F.R.C.S., F.R.S., late Surgeon and Professor of Clinical Surgery to King's College Hospital. With 463 Engravings. Fifth Edition. 8vo, 21s.

HEATH.—**A Manual of Minor Surgery and Bandaging, for the use of House-Surgeons, Dressers, and Junior Practitioners.** By CHRISTOPHER HEATH, F.R.C.S., Holme Professor of Clinical Surgery in University College and Surgeon to the Hospital. Fifth Edition. With 88 Engravings. Fcap. 8vo, 5s. 6d.

By the same Author.

A Course of Operative Surgery: with Twenty Plates drawn from Nature by M. LÉVEILLÉ, and Coloured by hand under his direction. Large 8vo, 40s.

ALSO,

The Student's Guide to Surgical Diagnosis. Fcap. 8vo, 6s. 6d.

NEW BURLINGTON STREET.

SURGERY—continued.

MAUNDER.—Operative Surgery. By Charles

F. MAUNDER, F.R.C.S., late Surgeon to, and Lecturer on Surgery at, the London Hospital. Second Edition. With 164 Engravings. Post 8vo, 6s.

PIRRIE.—The Principles and Practice of

Surgery. By WILLIAM PIRRIE, F.R.S.E., Professor of Surgery in the University of Aberdeen. Third Edition. With 490 Engravings. 8vo, 28s.

TERMINOLOGY.

DUNGLISON.—Medical Lexicon: a Dictionary

of Medical Science, containing a concise Explanation of its various Subjects and Terms, with Accentuation, Etymology, Synonymes, &c. By ROBLEY DUNGLISON, M.D. New Edition, thoroughly revised by RICHARD J. DUNGLISON, M.D. Royal 8vo, 28s.

MAYNE.—A Medical Vocabulary: being an

Explanation of all Terms and Phrases used in the various Departments of Medical Science and Practice, giving their Derivation, Meaning, Application, and Pronunciation. By ROBERT G. MAYNE, M.D., LL.D., and JOHN MAYNE, M.D., L.R.C.S.E. Fourth Edition. Fcap. 8vo, 10s.

WOMEN, DISEASES OF.

BARNES.—A Clinical History of the Medical

and Surgical Diseases of Women. By ROBERT BARNES, M.D., F.R.C.P., Obstetric Physician to, and Lecturer on Diseases of Women, &c., at, St. George's Hospital. Second Edition. With 131 Engravings. 8vo, 28s.

DUNCAN.—Clinical Lectures on Diseases of

Women. By J. MATTHEWS DUNCAN, M.D., Obstetric Physician to St. Bartholomew's Hospital. 8vo.

EMMET.—The Principles and Practice of

Gynæcology. By THOMAS ADDIS EMMET, M.D., Surgeon to the Woman's Hospital of the State of New York. With 130 Engravings. Royal 8vo, 24s.

WOMEN, DISEASES OF—*continued.*

GALABIN.—**The Student's Guide to the Diseases of Women.** By ALFRED L. GALABIN, M.D., F.R.C.P., Assistant Obstetric Physician and Joint Lecturer on Obstetric Medicine to Guy's Hospital. With 63 Engravings. Fcap. 8vo, 7s. 6d.

SMITH.—**Practical Gynæcology: a Handbook of the Diseases of Women.** By HEYWOOD SMITH, M.D., Physician to the Hospital for Women, and to the British Lying-in Hospital. With Engravings. Crown 8vo, 5s. 6d.

WEST AND DUNCAN.—**Lectures on the Diseases of Women.** By CHARLES WEST, M.D., F.R.C.P. Fourth Edition. Revised and in part re-written by the Author, with numerous additions, by J. MATTHEWS DUNCAN, M.D., Obstetric Physician to St. Bartholomew's Hospital. 8vo, 16s.

ZOOLOGY.

BRADLEY.—**Manual of Comparative Anatomy and Physiology.** By S. MESSENGER BRADLEY, F.R.C.S., Lecturer on Practical Surgery in Owen's College, Manchester. Third Edition. With 61 Engravings. Post 8vo, 6s. 6d.

CHAUVEAU AND FLEMING.—**The Comparative Anatomy of the Domesticated Animals.** By A. CHAUVEAU, Professor at the Lyons Veterinary School; and GEORGE FLEMING, Veterinary Surgeon, Royal Engineers. With 450 Engravings. 8vo, 31s. 6d.

HUXLEY.—**Manual of the Anatomy of Invertebrated Animals.** By THOMAS H. HUXLEY, LL.D., F.R.S. With 156 Engravings. Fcap. 8vo, 16s.

By the same Author.

Manual of the Anatomy of Vertebrated Animals. With 110 Engravings. Post 8vo, 12s.

WILSON.—**The Student's Guide to Zoology: a Manual of the Principles of Zoological Science.** By ANDREW WILSON, Lecturer on Natural History, Edinburgh. With Engravings. Fcap. 8vo, 6s. 6d.

NEW BURLINGTON STREET.

